

## Clinical Commentary

# Intravenous thrombolysis in ischemic stroke patients with isolated homonymous hemianopia

Strbian D, Soinne L, Sairanen T, Scheperjans F, Salonen O, Palomäki M, Kaste M, Tatlisumak T. Intravenous thrombolysis in ischemic stroke patients with isolated homonymous hemianopia.

Acta Neurol Scand: DOI: 10.1111/j.1600-0404.2012.01646.x.

© 2012 John Wiley & Sons A/S.

**Background** – Patients with posterior ischemic stroke were usually excluded from thrombolytic treatment in clinical trials and clinical practice, and little is known about effectiveness of thrombolysis treatment in such patients who may end up with severe disability.

**Aims of the study** – We aimed to describe the outcome of acute ischemic stroke patients presenting with isolated homonymous hemianopia and treated with intravenous thrombolysis. **Methods** – A case report of three patients presenting with homonymous hemianopia owing to posterior circulation stroke treated with intravenous thrombolysis at the Helsinki University Central Hospital. Main outcome measures were modified Rankin Scale and neuropsychological examination at 3 months after thrombolysis. We further evaluated Goldmann visual field examination at 6 months. **Results** – No acute findings appeared on admission non-contrast head-computed tomography scan. All patients had a perfusion deficit on admission-computed tomography perfusion imaging. All patients scored 0 on 3-month modified Rankin Scale, and their neuropsychological evaluation was normal. Goldmann examination revealed no visual field deficit in both female patients, and a modest visual field defect was detected in the male patient. **Conclusions** – Our experience encourages application of intravenous thrombolytic treatment (especially when supported with multimodality neuroimaging) in patients with homonymous hemianopia, for which rehabilitation options are limited.

**D. Strbian<sup>1</sup>, L. Soinne<sup>1</sup>,  
T. Sairanen<sup>1</sup>, F. Scheperjans<sup>1</sup>,  
O. Salonen<sup>2</sup>, M. Palomäki<sup>2</sup>,  
M. Kaste<sup>1</sup>, T. Tatlisumak<sup>1</sup>**

<sup>1</sup>Department of Neurology, Helsinki University Central Hospital, Helsinki, Finland; <sup>2</sup>Department of Radiology, Helsinki University Central Hospital, Helsinki, Finland

Key words: homonymous hemianopia; posterior circulation stroke; thrombolysis; visual field

D. Strbian, Department of Neurology, Helsinki University Central Hospital, Haartmaninkatu 4, 00290 Helsinki, Finland

Tel.: +358 9 471 71758

Fax: +358 9 471 71796

e-mail: daniel.strbian@hus.fi

Accepted for publication January 5, 2012

## Introduction

Patients with posterior ischemic stroke [accounting for up to 10% of all strokes (1)] were typically excluded from thrombolytic treatment in clinical trials and clinical practice. A striking example is a posterior circulation stroke patient presenting with isolated homonymous hemianopia. Such a patient scores 1 or 2 points on the National Institutes of Health Stroke Scale (NIHSS) and can end up with severe disability despite low NIHSS score. Only scarce data are

available on effectiveness of thrombolysis treatment in such patients.

## Case reports

We report three patients who presented with isolated homonymous hemianopia owing to posterior circulation stroke and received intravenous thrombolysis (0.9 mg/kg of bodyweight) within 4.5 h of symptom onset at the Department of Neurology, Helsinki University Central Hospital. We received institutional approval for this study.

Our institution does not require ethical review for retrospective analysis of data collected prospectively as part of routine clinical care.

Patient 1 was a 42-year-old woman with a history of aural migraine who presented with right-sided isolated homonymous hemianopia scoring 2 NIHSS points. She did not have any symptoms indicative of a migraine attack prior to admission or subsequently. Onset-to-treatment time (OTT) was 2 h 46 min.

Patient 2 was a 60-year-old man with a history of atrial fibrillation who presented with left-sided isolated homonymous hemianopia, also scoring 2 NIHSS points. OTT was 4 h 7 min.

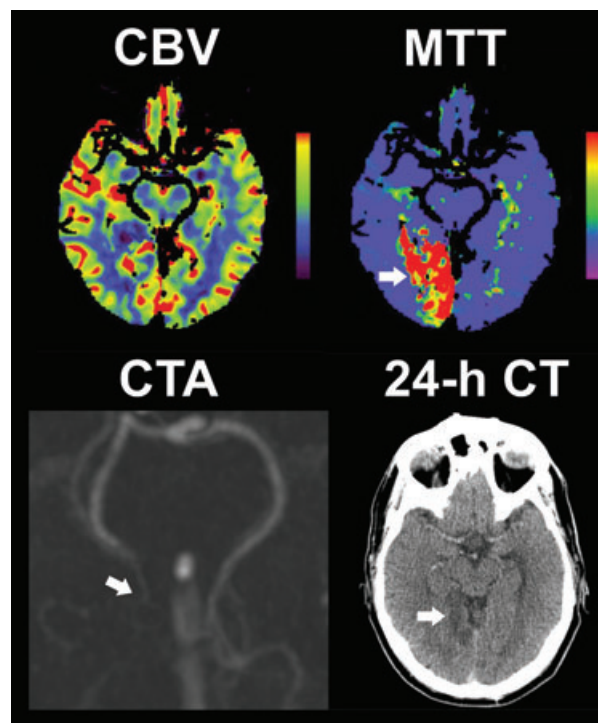
Patient 3 was a 70-year-old woman with a 4-year history of stage 4 follicular non-Hodgkin's lymphoma. She presented with left-sided isolated homonymous hemianopia and scored 1 NIHSS point. OTT was 1 h 40 min.

None of the patients had acute findings on admission non-contrast head-computed tomography (CT) scan; however, all of them had a perfusion deficit on admission CT perfusion imaging. Patient 1 had hypoperfusion in the left occipitoparietal region in the mean transit time (MTT) and cerebral blood flow (CBF) maps, whereas no decrease in cerebral blood volume (CBV). Patients 2 (Fig. 1) and 3 had hypoperfusion in the right occipital region (MTT and CBF) with no change in CBV maps. CT-angiography was normal in Patient 1, whereas it showed a distal posterior cerebral artery occlusion (PCAO) in Patient 2, and a short occlusion at the bifurcation level of PCA in Patient 3. On control (24-h) scan, Patient 1 and 3 had no new findings, whereas Patient 2 developed brain infarction, which was much smaller than the perfusion deficit seen on admission (Fig. 1). None developed cerebral hemorrhage.

Visual field defect of both female patients resolved within 2 h after initiation of thrombolysis, while partial improvement was observed in the male patient at 2 h post-thrombolysis and a small defect at 7 days. Goldmann visual field examination was normal in both female patients, and a modest visual field defect was detected in the male patient after 3 months. Neuropsychological evaluation of all patients was normal, and all scored 0 (normal) on 3-month modified Rankin Scale.

## Discussion

Most patients with acute posterior circulation stroke do not receive thrombolysis, owing to the lack of evidence from clinical trials. In the most recent trial, the ECASS-III (2), patients with pos-



**Figure 1.** Findings on admission and control brain imaging. Patient 2 had a hypoperfusion in the right occipital region in the mean transit time (MTT, arrow) and cerebral blood flow (not shown) maps with no change in the cerebral blood volume (CBV) maps. Admission CT-angiography (CTA) confirmed a distal occlusion of posterior cerebral artery (arrow). Control (24-h) CT scan showed a brain infarction (arrow), which was much smaller than the initial perfusion deficit. Onset-to-treatment time was 4 h 7 min.

terior stroke or isolated homonymous hemianopia were not explicitly excluded. Still, minor symptoms were part of the exclusion criteria, but minor symptoms were not specifically defined in the ECASS-III, so it is difficult to know how many patients (if any) with isolated homonymous hemianopia were included. One of our patients eventually developed a small visible brain infarction and ended up with a modest visual field defect. He had the longest OTT almost reaching 4.5 h. Nonetheless, all our patients benefited from intravenous thrombolysis and had normal 3-month modified Rankin Scale and neuropsychological evaluation. Because CBV measurements relatively well predict the final infarct size and no patients in our series had CBV changes, the current results are limited to patients without decrease in CBV.

Despite the low NIHSS score, mere homonymous hemianopia may lead to significant disability limiting the patient's daily activities, ability to work, and drive. Despite the fact that baseline NIHSS was repeatedly shown to be a strong predictor of final functional outcome (3), PCA

infarcts are associated with a variety of cognitive sequelae, which may lead to even severe handicap, which is poorly reflected by standard clinical assessment with NIHSS score (4). Indeed, isolated homonymous hemianopia not only represents posterior circulation stroke but also leads to a maximum of two NIHSS points. This strict inclusion criterion in our series represents the major difference compared with some recent reports evaluating thrombolysis in patients with posterior circulation stroke as such (5–7). Those series included patients with more severe symptoms in addition to homonymous hemianopia (NIHSS up to 21). Importantly, those reports show the impact of thrombolysis in the region of posterior circulation.

In our series, patient 1 had a history of migraine, but she did not have any symptoms indicative of a migraine attack. In theory, migraine episode with visual aura can be associated with hypoperfusion. Such hypoperfusion is, unlike ischemia, also seen in CBV maps and does not follow cerebral vascular territories (8, 9). Occluded vessel in this patient was most probably of small caliber (relatively smaller area of hypoperfusion on MTT and CBF maps) and was not visible on CT-angiography. She never had a similar attack before.

Our experience encourages application of intravenous thrombolytic treatment (especially when supported with multimodality neuroimaging) in patients with homonymous hemianopia, for which rehabilitation options are limited (10). The cases also prompt (more systematic research) on the thrombolysis of PCA ischemia and the resolution of the visual and cognitive symptoms.

### Acknowledgements

None.

### Conflicts of interest

Drs. Strbian, Soenne, Sairanen, Scheperjans, Salonen, and Palomäki report no disclosures.

Dr. Kaste has received honoraria and his travel expenses have been covered for participating in the Steering Commit-

tee meetings of ECASS, ECASS-II, ECASS-III, DIAS, DIAS-2, and DIAS-4 trials, and as a consultant for Boehringer Ingelheim, PAION AG, Forest Research Laboratories, Inc., and H. Lundbeck A/S and as a speaker in educational meetings sponsored by Boehringer Ingelheim (modest).

Dr. Tatlisumak had research contract with Boehringer Ingelheim, Sanofi Aventis, H. Lundbeck A/S, Mitsubishi Pharma, Schering Plough, Concentric Medical, PhotoThera, and BrainsGate (significant). He has received grant from Boehringer Ingelheim (modest) and served on the scientific advisory board and as consultant for Boehringer Ingelheim, Mitsubishi Pharma, BrainsGate (modest).

### Sources of funding

None.

### References

1. BRANDT T, STEINKE W, THIE A, PESSIN MS, CAPLAN LR. Posterior cerebral artery territory infarcts: clinical features, infarct topography, causes and outcome. Multicenter results and a review of the literature. *Cerebrovasc Dis* 2000;**10**:170–82.
2. HACKE W, KASTE M, BLUHMKI E et al.; ECASS Investigators. Thrombolysis with alteplase 3 to 4.5 hours after acute ischemic stroke. *N Engl J Med* 2008;**359**:1317–29.
3. SAŇÁK D, HERZIG R, ZAPLETALOVÁ J et al. Predictors of good clinical outcome in acute stroke patients treated with intravenous thrombolysis. *Acta Neurol Scand* 2011;**123**:339–44.
4. SATO S, TOYODA K, UEHARA T et al. Baseline NIH Stroke Scale Score predicting outcome in anterior and posterior circulation strokes. *Neurology* 2008;**70**:2371–7.
5. BREUER L, HUTTNER HB, JENTSCH K et al. Intravenous thrombolysis in posterior cerebral artery infarctions. *Cerebrovasc Dis* 2011;**31**:448–54.
6. MEIER N, FISCHER U, SCHROTH G et al. Outcome after thrombolysis for acute isolated posterior cerebral artery occlusion. *Cerebrovasc Dis* 2011;**32**:79–88.
7. FÖRSTER A, GASS A, KERN R, WOLF ME, HENNERICI MG, SZABO K. MR imaging-guided intravenous thrombolysis in posterior cerebral artery stroke. *AJNR Am J Neuroradiol* 2011;**32**:419–21.
8. SANCHEZ DEL RIO M, BAKKER D, WU O et al. Perfusion weighted imaging during migraine: spontaneous visual aura and headache. *Cephalalgia* 1999;**19**:701–7.
9. CUTRER FM, O'DONNELL A, SANCHEZ DEL RIO M. Functional neuroimaging: enhanced understanding of migraine pathophysiology. *Neurology* 2000;**55**:S36–45.
10. SCHOFIELD TM, LEFF AP. Rehabilitation of hemianopia. *Curr Opin Neurol* 2009;**22**:36–40.