

# Bevacizumab used for the treatment of severe, refractory perilesional edema due to an arteriovenous malformation treated with stereotactic radiosurgery

## Case report

BRIAN J. WILLIAMS, M.D., DERIC M. PARK, M.D., AND JASON P. SHEEHAN, M.D., PH.D.

*Department of Neurological Surgery, University of Virginia Health System, Charlottesville, Virginia*

The authors present a case of an arteriovenous malformation of the central sulcus treated with Gamma Knife surgery. The patient developed perilesional edema 9 months after treatment and experienced severe headache and hemiparesis. Her symptoms were refractory to corticosteroid therapy and pain management. She was subsequently treated with bevacizumab with striking improvement in her symptoms and results of neuroimaging studies. This is the first time that bevacizumab has been used to control severe refractory perilesional edema related to an intracranial arteriovenous malformation.

(<http://thejns.org/doi/abs/10.3171/2012.1.JNS111627>)

**KEY WORDS** • bevacizumab • arteriovenous malformation • edema • stereotactic radiosurgery

**P**ERILESIONAL edema is a significant clinical problem. An agent that reliably abrogates this edema is dexamethasone, a potent glucocorticoid receptor agonist.<sup>14</sup> Animal and in vitro data indicate that VEGF is the primary mediator of peritumoral edema.<sup>2,19,20</sup> Dexamethasone is believed to act primarily through the glucocorticoid receptor to decrease the expression of VEGF and thereby edema.<sup>12</sup> Bevacizumab, a monoclonal antibody against VEGF, has been used in the treatment of recurrent glioblastoma.<sup>8,15,21,24</sup> Recently, bevacizumab has been successfully used to control perilesional edema related to radiation necrosis, in a double-blind randomized, controlled trial.<sup>9,10,16,17,23</sup> All patients included in this trial had neoplastic lesions.

The use of bevacizumab for vascular pathology has been reported in Osler Weber Rendu Syndrome (Hereditary Hemorrhagic Telangiectasia) to decrease the incidence of epistaxis in these patients.<sup>1,3,7,13,22</sup> However, bevacizumab has not been used to treat AVMs of the central nervous system or related perilesional edema after treatment with SRS.

We report the first case of the use of bevacizumab to control symptomatic perilesional edema refractory to corticosteroid therapy after GKS for an intracranial AVM.

## Case Report

This 20-year-old right-handed woman had an AVM centered on the right central sulcus, which was found during an evaluation for persistent headaches. The malformation measured 1.4 cm in maximum dimension and was located on the motor strip (Fig. 1). After discussion of the risks and benefits of the treatment options, she elected to proceed with GKS. She was treated with a prescription dose of 22.0 Gy to the 50% isodose line with a maximum dose of 44.0 Gy. The planned treatment volume was 2.53 ml (Fig. 2). She initially did well and was discharged home the day after her procedure in good condition. She presented to the emergency department 9 months after GKS complaining of 2–3 weeks of severe persistent right-side headache and difficulty walking in high heels.

*Abbreviations used in this paper:* AVM = arteriovenous malformation; GKS = Gamma Knife surgery; SRS = stereotactic radiosurgery; VEGF = vascular endothelial growth factor.

This article contains some figures that are displayed in color online but in black-and-white in the print edition.

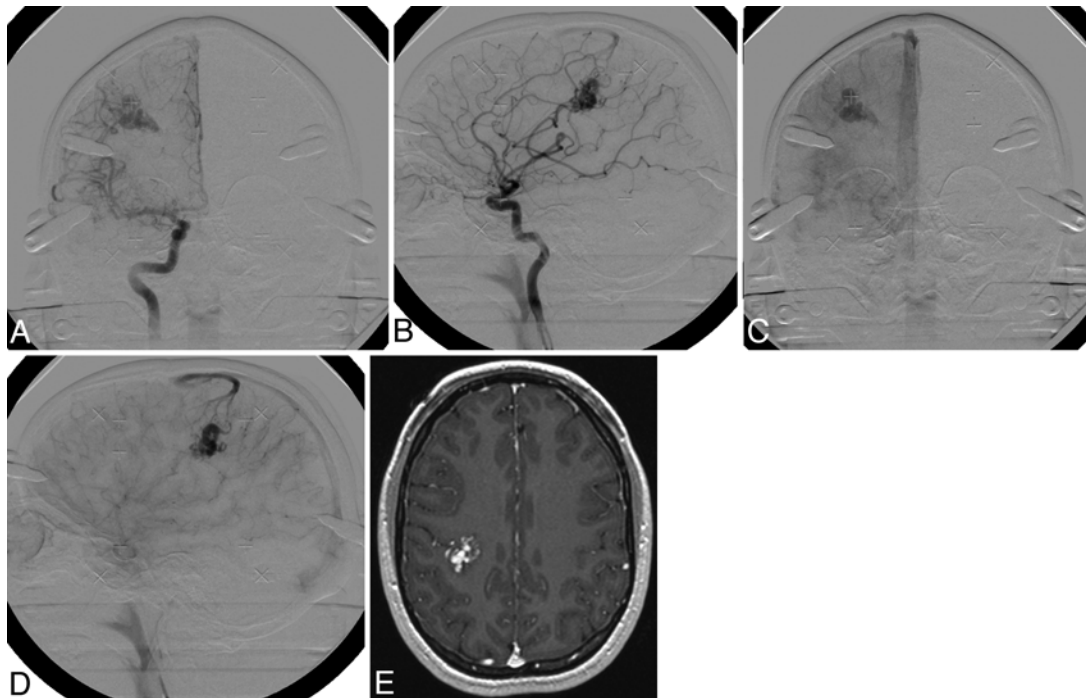


FIG. 1. Digital subtraction angiography and MRI of the AVM of the right central sulcus prior to GKS. Digital subtraction angiography is shown with right internal carotid artery injection in anteroposterior (**B and D**) and lateral projections (**A and C**) in the arterial phase (**A and B**) and capillary phase (**C and D**), demonstrating shunting in the middle cerebral artery territory and an early draining vein into the superior sagittal sinus. In addition, a stereotactic, axial T1-weighted MR image obtained after Gd administration (**E**) demonstrated a contrast-enhancing vascular lesion consistent with an AVM in the region of the central sulcus.

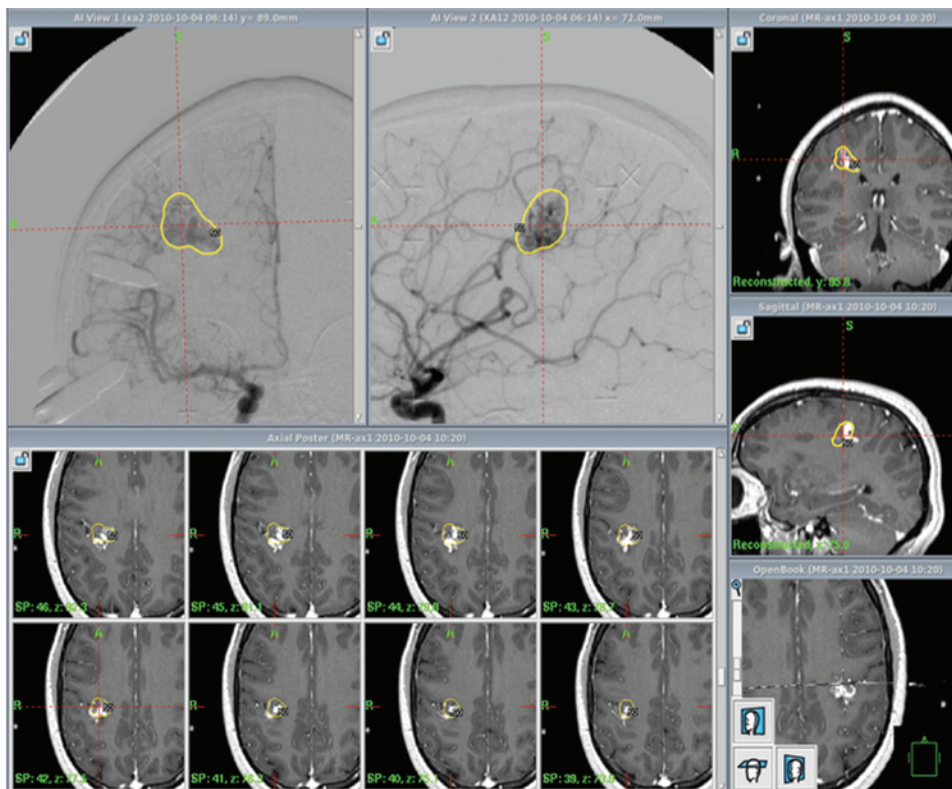
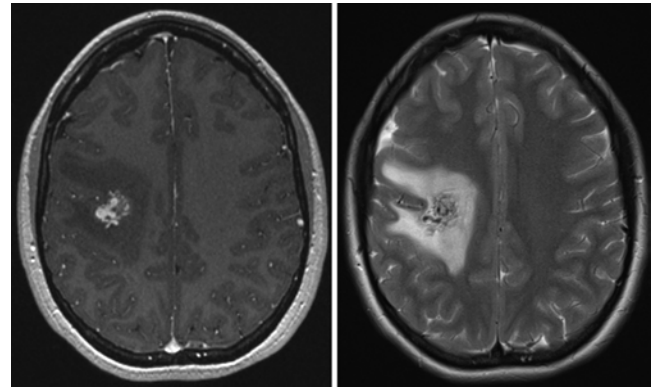


FIG. 2. Dose treatment plan from GKS treatment session using the GammaPlan software, including both the stereotactic MR and digital subtraction angiograms. The 50% isodose line is shown in yellow.

Her neurological examination was remarkable for weakness 4/5 in the left arm and 4+/5 in the left leg. An MRI demonstrated increased T2 signal intensity surrounding the AVM (Fig. 3). Corticosteroid therapy was initiated at that time, with a prescription for slow tapering off of the dosage over a month. The patient experienced a partial clinical response to the steroids with slight improvement in her headache but minimal change in her weakness. After 3 weeks, while on a lower dose of steroid medication, she returned to the emergency department with severe headache, nausea, vomiting, and unchanged weakness. She subsequently developed a left-sided pronator drift. An MRI study demonstrated persistent perilesional edema (Fig. 4). She was restarted on a high-dose steroid taper, and vitamin E and pentoxifylline were added. She continued to experience severe headaches intermittently; her hemiparesis remained stable. Approximately 1 month later (2 months after the onset of her symptoms) her headaches became severe enough to restrict her activity to bed rest only, causing her to present to the emergency department again. Her neurological examination findings were stable. Both MRI and CT demonstrated persistent perilesional edema (Fig. 5). She was admitted to the hospital and treated with an increased dose of corticosteroids without significant improvement in her symptoms. Her severe headache, which was refractory to pain management with intravenous narcotics and steroids, kept her incapacitated and essentially bed bound.

Considering the inadequate response to corticosteroids and her severe refractory symptoms, we discussed the option of treating the perilesional edema with bevacizumab. After informed consent was obtained, the patient was initially treated with a dose of 2.5 mg/kg, which she tolerated without incident. She experienced dramatic improvement in her headache the day after her infusion. She was able to ambulate without assistance and did not require further intravenous narcotic therapy. One week later she returned for evaluation and additional treatment. A CT study demonstrated no complications from treatment with her initial dose, and therefore, a dose of 7.5 mg/kg was administered (Fig. 6). On follow-up at 2 weeks (Fig. 7) and 6 weeks (Fig. 8) after the initial infusion of bevacizumab, her symptoms continued to improve. Her headache was intermittent and tolerable, managed with tramadol, and her steroid had been tapered off. Her weakness had improved to 4+/5 in her left lower extremity. She continued to have a pronator drift and slight hyperreflexia on the left. At 2 weeks' follow-up, MRI demonstrated stable perilesional edema on T2-weighted images, and MR angiography demonstrated no abnormal shunting in the region of the AVM (Fig. 7). A CT study and MRI performed at 6 weeks after the initial administration of bevacizumab demonstrated a dramatic decrease in contrast enhancement in the area of the AVM and a decrease in T2 signal around the AVM (Fig. 8). Follow-up at 1 year after GKS treatment and 10 weeks after the administration of bevacizumab demonstrated clinical improvement with infrequent use of tramadol for headache and no use of steroid agents. Neurological examination showed 4+/5 strength in the left arm and leg and a slight left pronator drift. She was able to return to school and activities of

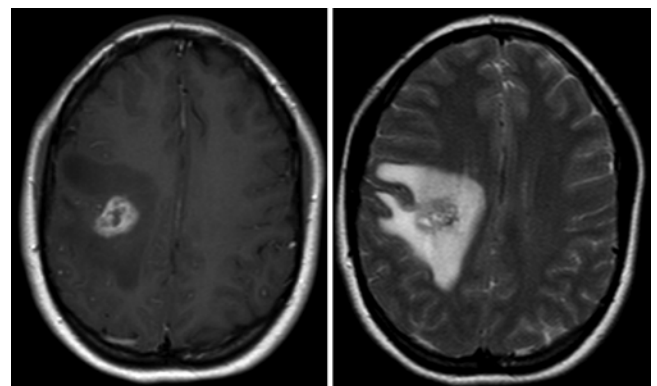


**FIG. 3.** Axial MR images obtained 9 months after GKS at the time of the patient's initial presentation to the emergency department. A T1-weighted postcontrast image (**left**) demonstrating enhancement in the area of the AVM with surrounding hypointensity and a T2-weighted image (**right**) demonstrating T2 hyperintensity correlating with T1 hypointensity consistent with edema.

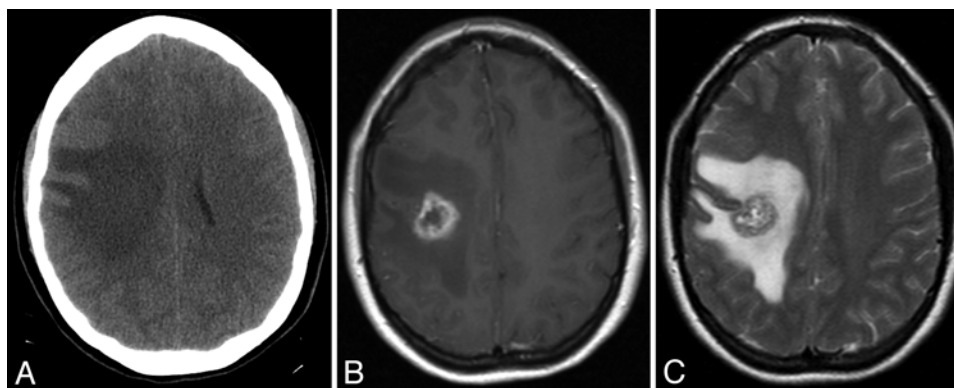
daily living without difficulty. Digital subtraction angiography performed at this time demonstrated obliteration of the AVM nidus with no evidence of abnormal shunting (Fig. 9).

## Discussion

Radiation-induced MRI changes occur in 36% of AVM cases treated with SRS at our institution.<sup>25</sup> These changes typically occur between 6 and 25 months after treatment and last for 2 to 79 months. The MRI findings were not associated with symptoms in 17% of cases, and these cases were managed expectantly. Symptomatic patients presented with headaches and new neurological deficits, as in our report, and were generally treated only with corticosteroid therapy.<sup>25,26</sup> In these cases perilesional edema typically heralded obliteration of the malformation. In the case presented in this report, the AVM was in an eloquent area, thus the patient developed a focal neurological deficit. Her severe headache, which was the most functionally limiting symptom, was a significant clinical feature as well.



**FIG. 4.** Images obtained 1 month after the patient's initial presentation to the emergency department and 10 months after GKS. Axial T1-weighted post-contrast (**left**) and T2-weighted (**right**) MR images demonstrating persistent perilesional edema of the pre- and postcentral gyri as well as the centrum semiovale.



**FIG. 5.** Images obtained 1 day prior to administration of bevacizumab, which was 2 months after the patient's initial presentation to the emergency department. Axial CT image (**A**), T1-weighted post-contrast MR image (**B**), and T2-weighted MR image (**C**) demonstrating unchanged perilesional edema.

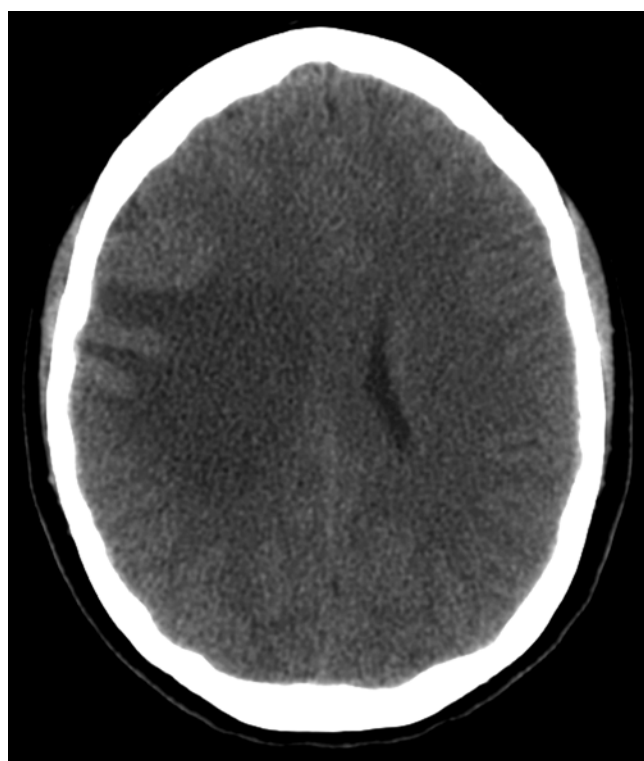
Bevacizumab has been used successfully for severe, symptomatic perilesional edema related to radiation necrosis from fractionated external beam treatments.<sup>9,10,17,23</sup> If VEGF is a final common mediator of perilesional edema due to tumors, necrosis, or AVMs treated with radiosurgery, then there may be a rational basis for using bevacizumab in these cases.<sup>18</sup> The side effect profile and cost of bevacizumab limit its potential use for this indication given that corticosteroids are inexpensive and typically control perilesional edema safely and effectively.<sup>6,8,11,15</sup> Nevertheless, in cases in which edema is refractory to corticosteroids and the patient is symptomatic, it may be

reasonable to consider the use of bevacizumab, especially when symptoms are severe and operative intervention would have significant morbidity, as in our case.

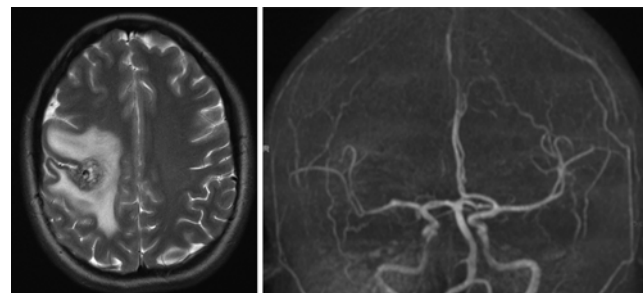
The administration of this medication should be supervised by clinicians familiar with prescribing this medication and with the pertinent side effects. In particular, the risk of bevacizumab in patients with vascular malformations known to have a tendency to hemorrhage must be weighed against the benefits and alternative therapeutic options (for example, open resection or continued management with narcotic and corticosteroid agents). When bevacizumab is used in GKS patients with posttreatment edema and necrosis, the patients must be monitored closely with clinical examination and serial imaging for improvement in the edema and potential development of bevacizumab-associated toxicity. Common severe adverse events associated with the use of bevacizumab are seizure (6%), fatigue (3.6%), hypertension (8.3%), and neutropenia, diarrhea, and pneumonia (1.2% each).<sup>5</sup> Specifically related to neurosurgical complications, bevacizumab has been associated with worse wound healing if given before a procedure compared with healing in groups not treated with bevacizumab or treated postoperatively.<sup>4</sup>

## Conclusions

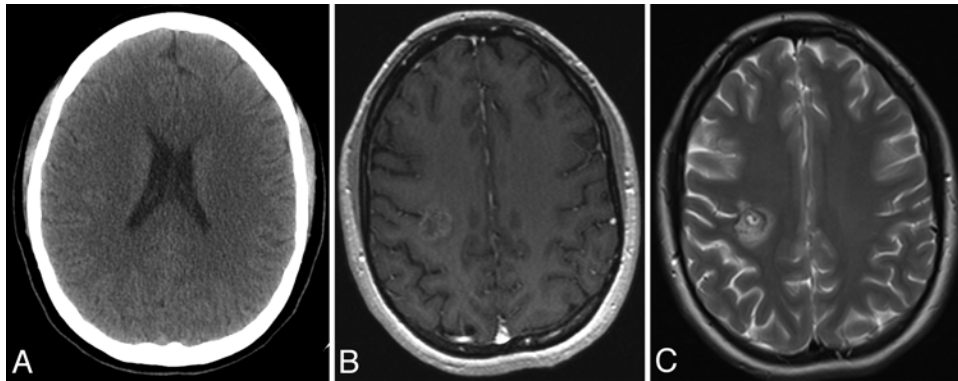
We report the first case of bevacizumab used for



**FIG. 6.** A CT image obtained 1 week after administration of the first dose of bevacizumab (2.5 mg/kg) demonstrating mildly improved perilesional edema and no evidence of hemorrhage in or around the lesion.



**FIG. 7.** Imaging obtained 2 weeks after administration of the first dose of bevacizumab. Axial T2-weighted MR image (**left**) and reconstructed MR angiographic (**right**) image demonstrating stable perilesional edema compared with the previous CT scan and no evidence of shunting in the region of the AVM.



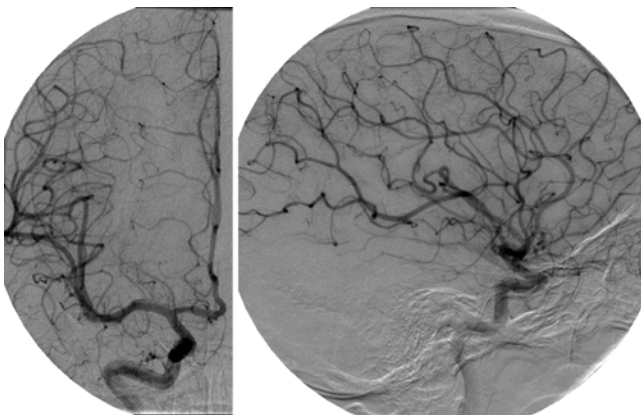
**FIG. 8.** Computed tomography and MR images obtained 6 weeks after administration of the first dose of bevacizumab demonstrating resolution of perilesional edema. Axial CT image (A), T1-weighted post-contrast MR image (B), and T2-weighted MR image (C) demonstrating dramatic improvement in the perilesional edema and decreased enhancement in the region of the AVM.

treatment of corticosteroid-refractory, symptomatic, and progressive edema due to an AVM after GKS. Given that this is a single case report, we cannot presume to provide proof of a causal relationship between bevacizumab and the resolution of perilesional edema. However, when evaluated in the context of the recent trial of bevacizumab for perilesional edema related to radiation necrosis, this case provides further evidence that bevacizumab may be a useful tool in the armamentarium of clinicians treating these difficult cases. Based on this evidence, we believe that the efficacy and safety of bevacizumab should be rigorously evaluated for severe, refractory cases of perilesional edema.

#### Disclosure

Dr. Park is a consultant for Elekta.

Author contributions to the study and manuscript preparation include the following. Conception and design: all authors. Acquisition of data: Williams. Drafting the article: all authors. Critically revising the article: all authors. Reviewed submitted version of manuscript: all authors. Approved the final version of the manuscript on behalf of all authors: Sheehan.



**FIG. 9.** Anterior-posterior (left) and lateral (right) projection digital subtraction angiograms obtained 1 year after GKS of the AVM near the right central sulcus demonstrating obliteration of the AVM nidus and no evidence of shunting in the region of the malformation.

#### References

1. Brinkerhoff BT, Poetker DM, Choong NW: Long-term therapy with bevacizumab in hereditary hemorrhagic telangiectasia. *N Engl J Med* **364**:688–689, 2011
2. Bruce JN, Criscuolo GR, Merrill MJ, Moquin RR, Blacklock JB, Oldfield EH: Vascular permeability induced by protein product of malignant brain tumors: inhibition by dexamethasone. *J Neurosurg* **67**:880–884, 1987
3. Chen S IV, Karnezis T, Davidson TM: Safety of intranasal Bevacizumab (Avastin) treatment in patients with hereditary hemorrhagic telangiectasia-associated epistaxis. *Laryngoscope* **121**:644–646, 2011
4. Clark AJ, Butowski NA, Chang SM, Prados MD, Clarke J, Polley MY, et al: Impact of bevacizumab chemotherapy on craniotomy wound healing. Clinical article. *J Neurosurg* **114**:1609–1616, 2011
5. Cohen MH, Shen YL, Keegan P, Pazdur R: FDA drug approval summary: bevacizumab (Avastin) as treatment of recurrent glioblastoma multiforme. *Oncologist* **14**:1131–1138, 2009
6. Desjardins A, Reardon DA, Coan A, Marcello J, Herndon JE II, Bailey L, et al: Bevacizumab and daily temozolomide for recurrent glioblastoma. *Cancer* [epub ahead of print], 2011
7. Fodstad P, Dheyaudeen S, Rinde M, Bachmann-Harildstad G: Anti-VEGF with 3-week intervals is effective on anemia in a patient with severe hereditary hemorrhagic telangiectasia. *Ann Hematol* **90**:611–612, 2011
8. Friedman HS, Prados MD, Wen PY, Mikkelsen T, Schiff D, Abrey LE, et al: Bevacizumab alone and in combination with irinotecan in recurrent glioblastoma. *J Clin Oncol* **27**:4733–4740, 2009
9. Gonzalez J, Kumar AJ, Conrad CA, Levin VA: Effect of bevacizumab on radiation necrosis of the brain. *Int J Radiat Oncol Biol Phys* **67**:323–326, 2007
10. Gronier S, Bourg V, Frenay M, Cohen M, Mondot L, Thomas P, et al: [Bevacizumab for the treatment of cerebral radionecrosis.] *Rev Neurol (Paris)* **167**:331–336, 2011 (Fr)
11. Gutin PH, Iwamoto FM, Beal K, Mohile NA, Karimi S, Hou BL, et al: Safety and efficacy of bevacizumab with hypofractionated stereotactic irradiation for recurrent malignant gliomas. *Int J Radiat Oncol Biol Phys* **75**:156–163, 2009
12. Heiss JD, Papavassiliou E, Merrill MJ, Nieman L, Knightly JJ, Walbridge S, et al: Mechanism of dexamethasone suppression of brain tumor-associated vascular permeability in rats. Involvement of the glucocorticoid receptor and vascular permeability factor. *J Clin Invest* **98**:1400–1408, 1996
13. Karnezis TT, Davidson TM: Efficacy of intranasal Bevacizumab (Avastin) treatment in patients with hereditary hemorrhagic telangiectasia-associated epistaxis. *Laryngoscope* **121**:636–638, 2011

14. Kotsarini C, Griffiths PD, Wilkinson ID, Hoggard N: A systematic review of the literature on the effects of dexamethasone on the brain from in vivo human-based studies: implications for physiological brain imaging of patients with intracranial tumors. **Neurosurgery** **67**:1799–1815, 2010
15. Kreisl TN, Kim L, Moore K, Duic P, Royce C, Stroud I, et al: Phase II trial of single-agent bevacizumab followed by bevacizumab plus irinotecan at tumor progression in recurrent glioblastoma. **J Clin Oncol** **27**:740–745, 2009
16. Liu AK, Macy ME, Foreman NK: Bevacizumab as therapy for radiation necrosis in four children with pontine gliomas. **Int J Radiat Oncol Biol Phys** **75**:1148–1154, 2009
17. Matuschek C, Bölke E, Nawatny J, Hoffmann TK, Peiper M, Orth K, et al: Bevacizumab as a treatment option for radiation-induced cerebral necrosis. **Strahlenther Onkol** **187**:135–139, 2011
18. Nonoguchi N, Miyatake S, Fukumoto M, Furuse M, Hiramatsu R, Kawabata S, et al: The distribution of vascular endothelial growth factor-producing cells in clinical radiation necrosis of the brain: pathological consideration of their potential roles. **J Neurooncol** **105**:423–431, 2011
19. Papavassiliou E, Gogate N, Proescholdt M, Heiss JD, Walbridge S, Edwards NA, et al: Vascular endothelial growth factor (vascular permeability factor) expression in injured rat brain. **J Neurosci Res** **49**:451–460, 1997
20. Proescholdt MA, Heiss JD, Walbridge S, Mühlhauser J, Capogrossi MC, Oldfield EH, et al: Vascular endothelial growth factor (VEGF) modulates vascular permeability and inflammation in rat brain. **J Neuropathol Exp Neurol** **58**:613–627, 1999
21. Reardon DA, Desjardins A, Vredenburgh JJ, Gururangan S, Sampson JH, Sathornsumetee S, et al: Metronomic chemotherapy with daily, oral etoposide plus bevacizumab for recurrent malignant glioma: a phase II study. **Br J Cancer** **101**:1986–1994, 2009
22. Simonds J, Miller F, Mandel J, Davidson TM: The effect of bevacizumab (Avastin) treatment on epistaxis in hereditary hemorrhagic telangiectasia. **Laryngoscope** **119**:988–992, 2009
23. Torcuator R, Zuniga R, Mohan YS, Rock J, Doyle T, Anderson J, et al: Initial experience with bevacizumab treatment for biopsy confirmed cerebral radiation necrosis. **J Neurooncol** **94**:63–68, 2009
24. Wong ET, Gautam S, Malchow C, Lun M, Pan E, Brem S: Bevacizumab for recurrent glioblastoma multiforme: a meta-analysis. **J Natl Compr Canc Netw** **9**:403–407, 2011
25. Yen CP, Jain S, Haq IU, Jagannathan J, Schlesinger D, Sheehan J, et al: Repeat Gamma Knife surgery for incompletely obliterated cerebral arteriovenous malformations. **Neurosurgery** **67**:55–64, 2010
26. Yen CP, Khaled MA, Schwyzer L, Vorsic M, Dumont AS, Steiner L: Early draining vein occlusion after gamma knife surgery for arteriovenous malformations. **Neurosurgery** **67**:1293–1302, 2010

Manuscript submitted September 15, 2011.

Accepted January 9, 2012.

Please include this information when citing this paper: published online February 10, 2012; DOI: 10.3171/2012.1.JNS111627.

Address correspondence to: Jason P. Sheehan, M.D., Ph.D., University of Virginia Health System, Department of Neurological Surgery, Charlottesville, Virginia 22908. email: jps2f@virginia.edu.