



# Epidural hematoma

Alexandra Scheibl\*, Elisenda Moliner Calderón, María José García Borau, Raúl Morales Prieto, Patricia Febles González, Gemma Ginovart Galiana

*Division of Neonatology, Department of Pediatrics, Hospital Sant Pau I Santa Creu, Barcelona, Spain*

Received 28 March 2011; revised 23 October 2011; accepted 28 October 2011

## Key words:

Epidural hematoma;  
Newborn;  
Cephalohematoma;  
Skull fracture

**Abstract** Epidural hematomas are rare birth injuries, and spontaneous presentation is exceptional. We present 2 cases of newborns with spontaneous epidural hematomas after delivery. In both cases, cerebral hemorrhage was associated with skull fracture and cephalohematoma. One newborn presented with neurologic symptoms in the form of convulsions, whereas the other was asymptomatic. Confirmation of the diagnosis was made by cranial computed tomography. Both cases were treated surgically by craniotomy. Follow-up showed normal neurologic development.

© 2012 Elsevier Inc. All rights reserved.

Epidural hematomas represent only 2% of neonatal cerebral hemorrhages [1] and are often accompanied by cranial fractures [2]. They are usually related to obstetric trauma secondary to instrument assisted delivery [1,3,4]. Newborns can be asymptomatic or present with hematologic, neurologic, or nonspecific symptoms. Because spontaneous epidural hematomas are probably underdiagnosed, we describe 2 newborns with cephalohematomas and spontaneous presentation of an epidural hematoma to provide a better understanding of this pathology.

## 1. Case reports

### 1.1. Case 1

An infant girl was born spontaneously, in vertex presentation without instrumental assistance at 38 weeks gestation. Pregnancy was uneventful. Apgar scores were 9 at

1 minute and 10 at 5 minutes. Birth weight was 2.380 g; length, 47.5 cm; head circumference, 35 cm, corresponding to a newborn small for gestational age. There was no evidence of traumatic delivery. Physical examination was normal, except for a parietal cephalohematoma. Transfontanelle ultrasound was performed in accordance with the protocol of our center for newborns weighing less than 2500 g. Right ventricular compression and a paraventricular hyperechoic image were detected, suggesting right parietooccipital intracranial hemorrhage. Cranial computed tomography (CT) showed a voluminous right parietooccipital epidural hematoma confirming the ultrasound findings (Fig. 1). The hematoma caused compression of adjacent structures, collapse of the ipsilateral ventricle, and midline deviation. An ipsilateral cranial fracture was detected.

Neurologic examination was normal, except for a tendency to somnolence. The pupils were equal and reactive. She had normal vital signs: heart rate of 147 beats per minute, arterial blood pressure of 79/61 mm Hg. Platelet count was 269,000/ $\mu$ L and normal coagulation test (international normalized ratio, 1.23; cephalin ratio, 1.35; activated thromboplastin time, 25 seconds; fibrinogen, 4.28 g/L) excluding coagulopathies. There was no evidence of anemia observed

\* Corresponding author.

E-mail address: alex41280@hotmail.com (A. Scheibl).

(hemoglobin level was 132 g/L). Surgical evacuation was performed via craniotomy without any adverse events.

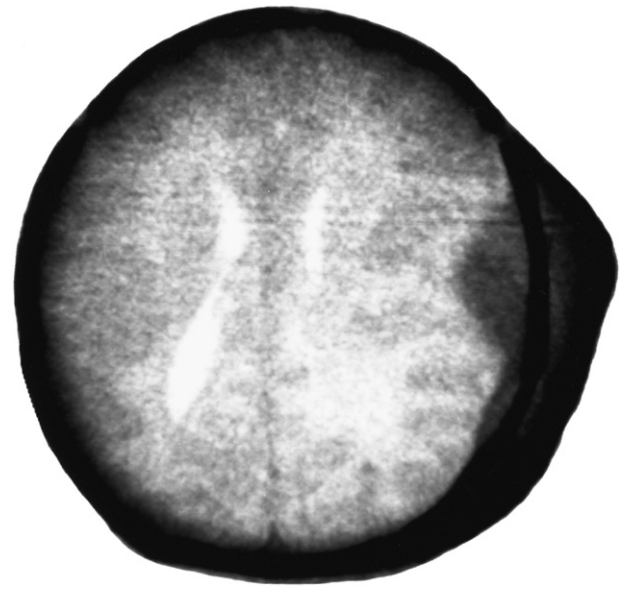
The infant did well postoperatively and was discharged after 1 week with a normal neurologic examination. A repeat head CT scan was performed at 6 months with normal findings. At 7 months, the patient presented a normal neurologic examination, meeting developmental milestones for her age.

## 1.2. Case 2

A male infant was born at 39 weeks gestation, delivered by cesarean delivery owing to failure to progress. Pregnancy was uneventful. Apgar scores were 5 at 1 minute, 8 at 5 minutes, and 10 at 10 minutes. Birth weight was 3190 g; length, 49 cm; and head circumference, 33 cm. Physical examination was normal except for a left parietal cephalohematoma and self-limited transient tachypnea in the first few hours of life. At 36 hours of life, the newborn presented with right-sided myoclonic movements. Treatment with phenobarbital was started. A transfontanelle ultrasound study showed displacement of the midline, a compressed left lateral ventricle, and a high echodense mass in the cortical area. A cranial CT scan confirmed the suspicion of epidural hematoma in the frontoparietal region, communicating with the external left cephalohematoma through a skull fracture (Fig. 2).

Emergency surgical evacuation was performed by craniotomy without any complications. Coagulation and blood samples were normal (hemoglobin level 172 g/L and normal coagulation test [international normalized ratio, 1.31; cephalin ratio, 1.03; activated thromboplastin time, 34 seconds; reptilase time, 28 seconds]).

One day postoperatively, the patient had another episode of myoclonic movements, which diminished after treatment



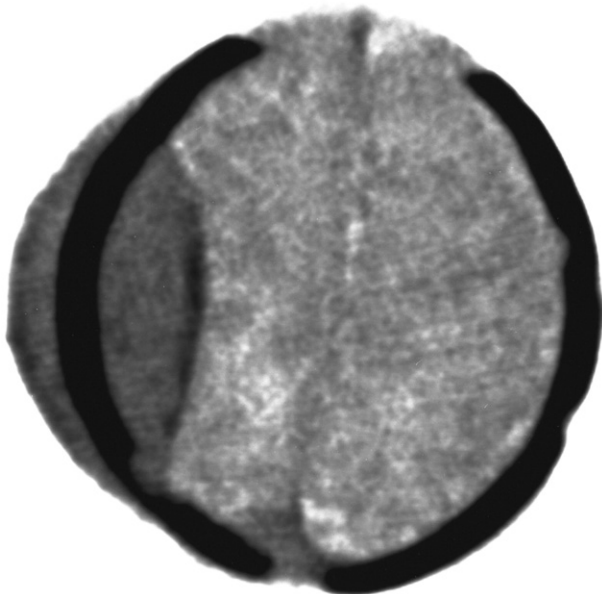
**Fig. 2** Case 2, Cranial CT showed frontoparietal epidural hematoma communicating with the external left cephalohematoma through a skull fracture.

with phenobarbital, which was discontinued 5 days later. A follow-up cranial CT scan showed minimal residual blood in the sulci of the left cerebral hemisphere. Antibiotic therapy was administered for 6 days. The patient was discharged 14 days after the procedure without any further treatment. Neurologic development by the age of 4 years was normal. The boy demonstrated appropriate developmental milestones for his age.

## 2. Discussion

Most cranial hemorrhages of in-term infants are either subdural or subarachnoid in nature [5]. Epidural hematomas are rare and self limited because of the firm adherence of dura to the overlying skull bone. Dura mater bone separation is the initiating event of epidural hematomas after birth [6]. Commonly, epidural hematomas are observed after traumatic delivery owing to instrumental delivery [7]. Nevertheless, spontaneous hematomas do occur. Compression in the birth canal can cause considerable bone dislocation and, thus, separate the dura mater from the inner table. Another cause of epidural hematomas is skull fractures, if the injury has produced a dura mater bone cleavage. Cephalohematoma is a common finding in epidural hematomas in newborns, owing to communication through a skull fracture or confluence of 2 different bleeding points. Because meningeal arteries are not embedded in the skull bone in newborns, both meningeal arteries or the diploic venous system can be a source of bleeding after cranial fracture [8].

Patients can either be asymptomatic or present with neurologic or hematologic symptoms, such as paleness, somnolence, bradycardia, hypotension, convulsion, apnea, or



**Fig. 1** Case 1, Cranial CT showed right parietal-occipital epidural hematoma and cranial fracture.

focal neurologic deficits [9]. Clinical appearance depends on the size and location of the lesion. In a clinical study including 15 cases, seizures and hypotonia were the most common symptoms. Time latency from birth to the first symptoms was less than 24 hours in most cases. No sex predominance was reported in this study [6]. Other studies suggest a male predominance, which could be explained by the fact that boys have a larger head circumference than girls [10].

Diagnosis is made by cranial CT [11] or magnetic resonance imaging. Computed tomographic scan features are not different than in other age groups. They are characterized by a hyperdense lentiform collection, but it may also be hypodense or heterogeneous. Appropriate therapeutic modalities depend on the volume of the hemorrhage and clinical presentation. Treatment of epidural hemorrhage in newborns consists of either evacuation by craniotomy or conservative treatment. Surgical criteria include large volume of the hematoma, associated cranial fracture, and midline deviation of the brain as well as clinical symptoms. Because cranial sutures are not unfused and, therefore, head circumference can increase, intracranial hypertension may be compensated explaining the absence of symptoms. Although alternative methods such as trepanation or needle aspiration of epidural hematomas communicating with cephalohematomas were described [2,3], craniotomy is still considered the standard treatment. Follow-up CT or magnetic resonance imaging scans are mandatory. Prognosis and outcome are generally good given prompt diagnosis and treatment. The current presented cases were both diagnosed using transfontanelle ultrasound first; upon atypical presentation, a cranial CT confirmed the diagnosis of epidural hematomas. Craniotomy was used as treatment in both cases. Follow-up cranial CT scans were performed, and both cases showed normal neurologic development.

### 3. Conclusion

Although spontaneous epidural hematomas are rare birth-associated injuries, cephalohematomas are a very common

finding. Nevertheless, they can be associated with cranial fracture and epidural hematomas. Epidural hematomas are probably underdiagnosed because of their asymptomatic presentation in some cases. Thus, we suggest examining newborns presenting with cephalohematomas using transfontanelle ultrasound to exclude epidural hematomas. If clinical symptoms or compression of adjacent brain structures is visible surgical evacuation via craniotomy should be performed. Further studies are needed to determine incidence and possible follow-up of affected children.

### References

- [1] Hovind KH. Traumatic birth injuries. In: AJ Raimondi, Choux M, Di Rocco C, editors. *Head injuries in the newborn and infant* Springer; 1986. p. 87-109.
- [2] Smets K, Vanhauwaert D. Treatment of cranial epidural hematoma in a neonate by needle aspiration of a communicating cephalohematoma. *Eur J Pediatr* 2010;169:617-9.
- [3] Vachharajani A, Mathur A. Ultrasound-guided needle aspiration of cranial epidural hematoma in a neonate: treating a rare complication of vacuum extraction. *Am J Perinatol* 2002;19:401-4.
- [4] Villarejo F, Belinchón JM, Carceller F, et al. Lesiones craneales secundarias a parto asistido con forceps. *Neurocirugía* 2009;20:262-4.
- [5] Towner D, Castro MA, Eby-Wilkens E, et al. Effect of mode of delivery in nulliparous women on neonatal intracranial injury. *N Engl J Med* 1999;341:1709-14.
- [6] Hamlat A, Heckly A, Adn M, et al. Pathophysiology of intracranial epidural haematoma following birth. *Med Hypotheses* 2006;66:371-4.
- [7] Heyman R, Heckly A, Magagi J, et al. Intracranial epidural hematoma in newborn infants: clinical study of 15 cases. *Neurosurgery* 2005;57:924-9.
- [8] Harpold TL, McComb JG, Levy ML, et al. Neonatal neurosurgical trauma. *Neurosurg Clin N Am* 1998;9:141-54.
- [9] Haase R, Sauer H, Brucke M, et al. Geburtstraumatisches epidurales Hämatom bei einem Neugeborenen. *Geburtshilfe Neonatol* 2005;209:151-5.
- [10] Akiyama Y, Moritake K, Maruyama N, et al. Acute epidural hematoma related to cesarean section in a neonate with Chiari II malformation. *Childs Nerv Syst* 2001;17:290-3.
- [11] Aoki N. Epidural haematoma in newborn infants: therapeutic consequences from the correlation between haematoma content and computed tomography features. A review. *Acta Neurochir (Wien)* 1990;106:65-7.