

Case report

Reversion of cerebral artery stenoses due to tuberculomas with TNF- α antibodiesStefaan J. Vandecasteele^{a,*}, An S. De Vriese^a, Geert T. Vanhooren^b^a Department Internal Medicine, Division of Nephrology and Infectious diseases, AZ Sint-Jan Brugge-Oostende AV, Ruddershove 10, 8000 Brugge, Belgium^b Department of Neurology, AZ Sint-Jan Brugge-Oostende AV, Ruddershove 10, 8000 Brugge, Belgium

ARTICLE INFO

Article history:

Received 13 November 2010

Received in revised form 6 January 2012

Accepted 16 January 2012

Available online 15 February 2012

Keywords:

Tuberculosis

Tuberculoma

Stroke

Infliximab

1. Introduction

Intracranial tuberculomas are a rare but severe complication of tuberculosis infections. Their pathogenesis is partially immune-mediated, and they can present throughout the course of the disease [1]. Anti-TNF treatment such as infliximab inherits an increased risk for tuberculosis [2]. A case of disseminated tuberculosis under infliximab treatment is presented illustrating the subsequent risk of paroxysmal reactions after cessation of the infliximab and the potential role of infliximab in the treatment of these paroxysmal reactions.

2. Case report

A 58-year old patient presented in April 2008 with recent onset painless swelling in the right groin, non-productive cough and night-sweats. The patient was known with HLA-B27 positive spondyloarthropathy, for which he received etanercept from 2000 till 2005, and infliximab since 2005. The patient was intradermo negative prior to the start of etanercept in 2005. Ultrasound of the right groin demonstrated multiple pathologic lymph nodes. Biopsy revealed an inflammatory lymphadenitis with positive Ziehl staining and culture for omni sensitive *Mycobacterium tuberculosis*. Disseminated tuberculosis infection with invasion of multiple lymph node stations (iliaco-inguinal, abdominal, mediastinal, hilar and peripheral lymph nodes) as well as bilaterally lung lesions

was diagnosed (Fig. 1). Treatment with infliximab was ceased, and quadruple tuberculostatic treatment was started. After three months of treatment, there was a noticeable decrease in the number and size of the lymph nodes, but the patient had crescendo complaints of his inflammatory spondyloarthropathy.

In August 2008, the patient presented with transient dysarthria, paresis of the right arm and, to a lesser extent, of the right leg, caused by a small infarction on the course of the pyramidal tract in the left anterior pontine region. There was no evident cardioemboligenic or arteriosclerotic etiology (Fig. 2A). Clopidogrel, acetylsalicylic acid, pravastatin and a low dose of ramipril were started. Two months later, the patient had a relapse of dysarthria and new-onset vertigo, resolving within days. TOF MR angiography (MRA) of the brain revealed no recent parenchymatous lesions, but a new, high-grade stenosis of the basilar artery (BA) (Fig. 2B). Cerebrospinal fluid only showed a slightly elevated protein (protein 48 mg/L, albumin index 8.9). Given the normal imaging of the brain vessels 2 months earlier and the recent history of miliary tuberculosis, a tentative diagnosis of paradoxical worsening of tuberculomas causing luminal narrowing in the affected arteries was made. Dexamethasone 12 mg was added to the treatment. One month later, new high-grade stenoses were found in the left posterior cerebral artery (ACP), the bifurcation of the BA and the left ACP and the ostium of the left superior cerebellar artery. The critical stenosis of the BA did not change (Fig. 2C). At that moment, treatment with infliximab was re-instituted after discussion of potential risks and benefits with the patient. Except for one transient episode of vertigo 2 weeks after institution of the infliximab, the patient remained free of neurological signs. A progressive regression of the BA stenosis was observed over a 14 months period (Fig. 2D).

* Corresponding author. Tel.: +32 50452200; fax: +32 50452299.

E-mail address: Stefaan.Vandecasteele@azbrugge.be (S.J. Vandecasteele).

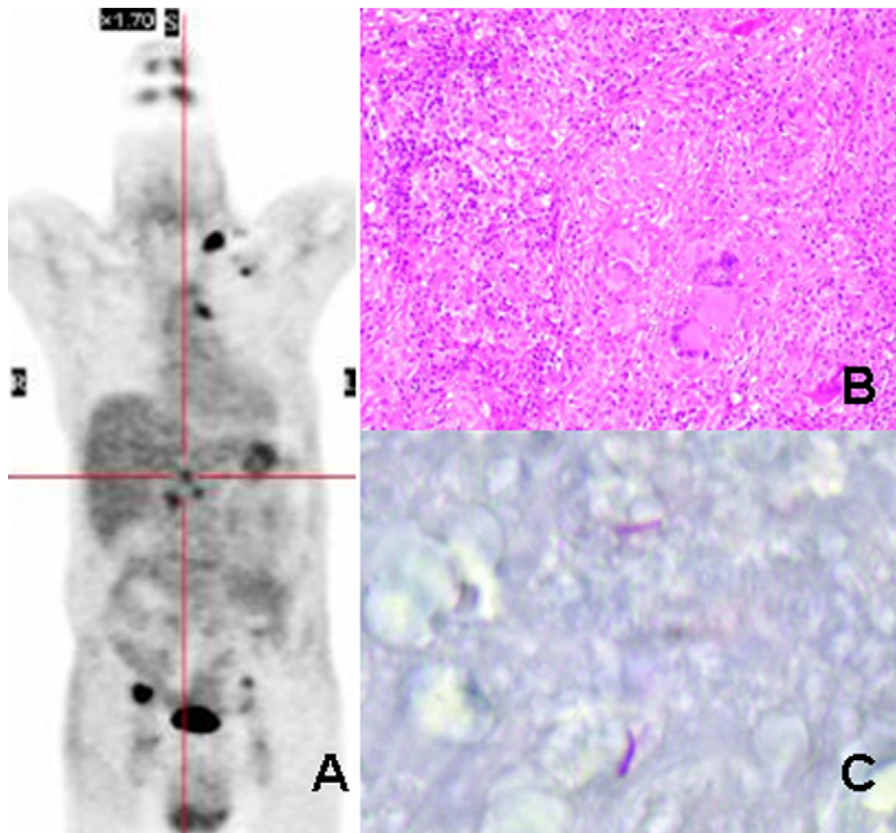


Fig. 1. PET scan of the patient demonstrating multiple pathologic lymph nodes (A). Hematoxylin–eosin stain of a lymph node demonstrating inflammation with histiocytes, lymphocytes and necrosis (B) with a positive Ziehl stain (C).

3. Discussion

The diagnosis and differential diagnosis of cerebral vasculitis remain a difficult clinical challenge. Conventional cerebral angiography is generally considered to be the most accurate test, but its availability and small risk for complications may hamper its use and repetitive use, as was the case in this patient. In this case, the tentative diagnosis of tuberculosis related cerebral vasculitis was made on a composition of the clinical context and picture, the rapid appearance of multiple stenoses on sequential MRA and the response of these lesions on a treatment that only acts on vasculitis. No evidence for alternative diagnosis such as atheromatosis or auto-immune mediated vasculitis was found.

TNF- α monoclonal antibodies such as infliximab confer a risk for both reactivation and new-onset of often rapidly progressive and disseminated tuberculosis [2]. TNF plays a central role in granuloma formation and maintenance, which is essential for the containment of this difficult-to-eradicate intracellular infection [2,3]. Granulomas induce a semi-dormant state in mycobacteria and function as a physical barrier against dissemination of the mycobacterial infection [3]. Several lines of evidence suggest that they do not only protect the body against the debilitating effects of disease dissemination, but also hamper significantly the already intrinsic weak killing effect of tuberculostatic drugs [3]. TNF- α monoclonal antibodies inhibits this containment strategy, thus making patients vulnerable for rapid

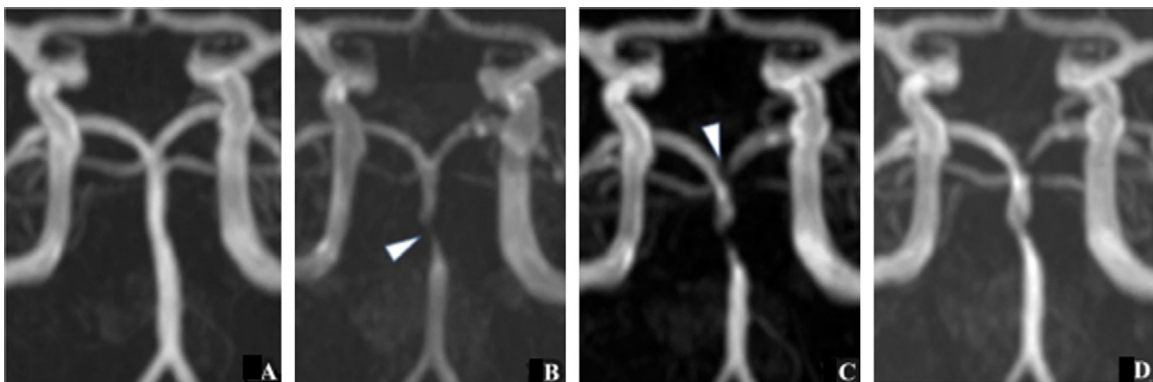


Fig. 2. Sequential MRA of the posterior cerebral circulation: (A) 19th August 2008, small infarction left pontine region with normal BA and ACP; (B) 22nd October 2008, new high grade stenosis BA; (C) 27th November 2008, after 1 month of dexamethasone treatment, new high-grade stenoses of left ACP; (D) 2nd February 2010, regression of stenotic lesions.

spreading infections with mycobacteria [3]. On the other hand, excessive or inappropriate activation of TNF- α mediated cellular immune response against mycobacteria that are damaged or killed by chemotherapy, may exacerbate inflammatory disease [2–4]. This seems the underlying mechanism of paradoxical reactions and inflammatory immune reconstitution syndromes reported in association with the treatment of tuberculosis *in se*, with the treatment of HIV-TBC co-infection and with the discontinuation of TNF- α antagonists in patients with active tuberculosis [1,2,4].

Paradoxical reactions may present as intracranial tuberculomas. Intracranial tuberculomas develop in approximately 1% of the patients. They have a variable appearance, and a growth that might be independent of disease activity [1]. Symptoms arise from either an intracranial mass-effect caused by excessive inflammation, or a minor lesion located in a critical area of the brain – as in our patient. High doses of corticosteroids in combination with tuberculostatics are the mainstay of the treatment [1]. A possible role of the TNF- α antagonist infliximab in the treatment of these paradoxical inflammatory conditions has been suggested, but remains unproven [4]. Contrary to the soluble TNF- α receptor agonist etanercept, the anti-TNF- α monoclonal antibody infliximab binds cell surface expressed TNF, apparently leading to apoptosis of TNF-expressing cells, with inhibition of further granuloma formation and disruption of existing granulomas [3,5]. Infliximab may in this way reduce tuberculosis associated inflammation and enhance anti-tuberculosis chemotherapy induced killing [3–5].

Thalidomide, by virtue of its anti-TNF- α activity, also appears to be beneficial in this setting [1].

4. Conclusion

In this case of live-threatening stenoses of the posterior cerebral circulation caused by tuberculomas, early reinstatement of infliximab was associated with a disappearance of neurological symptoms, and a slow reversal of the causative vascular lesions. These observations suggest a potential role of TNF- α antibodies in the management of excessive inflammation in tuberculosis.

Conflict of interest

None.

References

- [1] Nicolls DJ, King M, Holland D, Bala J, del Rio C. Intracranial tuberculomas developing while on therapy for pulmonary tuberculosis. *Lancet Infect Dis* 2005;5(December (12)):795–801.
- [2] Wallis RS. Tumour necrosis factor antagonists: structure, function, and tuberculosis risks. *Lancet Infect Dis* 2008;8(October (10)):601–11.
- [3] Wallis RS, Broder M, Wong J, Lee A, Hoq L. Reactivation of latent granulomatous infections by infliximab. *Clin Infect Dis* 2005;41(August (Suppl. 3)):S194–8.
- [4] Blackmore TK, Manning L, Taylor WJ, Wallis RS. Therapeutic use of infliximab in tuberculosis to control severe paradoxical reaction of the brain and lymph nodes. *Clin Infect Dis* 2008;47(November (10)):e83–5.
- [5] Wallis RS. Reconsidering adjuvant immunotherapy for tuberculosis. *Clin Infect Dis* 2005;41(July (2)):201–8.