

Transient periodic lateralised epileptiform discharges (PLEDs) following internal carotid artery stenting

Daniela Marino¹, Giampaolo Vatti², Alessandra Rufa¹, Alessandro Malandrini¹, Raffaele Rocchi², Sandra Bracco³, Rosaria Buccoliero¹, Antonio Federico¹

¹ Department of Neurological, Behavioural and Neurosurgical Sciences, Section of Neurological Sciences

² Department of Neuroscience, Section of Neurology

³ Department of Neuroimaging and Neurointervention, University of Siena, Italy

Received August 8, 2010; Accepted November 30, 2011

ABSTRACT – *Background.* Periodic lateralised epileptiform discharges (PLEDs) are EEG patterns consisting of periodic or pseudoperiodic unilateral, focal or hemispheric epileptiform discharges at a rate of 1-2 Hz. PLEDs may be triggered by acute brain injuries or systemic metabolic changes such as fever, hyperglycaemia or electrolyte imbalance and may result in disturbance of consciousness and/or neurological deficits. *Case report.* A 58-year-old female with a history of focal epilepsy and deep brain haematoma presented with acute change in awareness, associated with EEG evidence of PLEDs, three days after a left internal carotid artery stenting procedure. Clinical examination, laboratory testing and MRI were unchanged with respect to pre-stenting investigations. *Conclusion.* In this patient, PLEDs may have been triggered by local haemodynamic changes due to reperfusion after stenting in a previously damaged brain area.

Key words: PLEDs, carotid artery stenting, EEG periodic discharges

Periodic lateralised epileptiform discharges (PLEDs) are peculiar EEG patterns consisting of unilateral, focal or hemispheric epileptiform potentials (spikes, spike and waves, sharp waves, and polyspikes) recurring in a periodic or pseudoperiodic fashion, at a rate of 1-2 Hz (Baykan *et al.*, 2000). Usually self-limiting over time, this electrical event may rarely persist for months or even years (Westmoreland *et al.*, 1986). PLEDs

are believed to be triggered by a systemic condition which lowers the seizure threshold (Grand'Maison *et al.*, 1991).

Neurological correlates of PLEDs are disturbances of consciousness (81%), cognitive deficits and epileptic seizures (90%) (Baykan *et al.*, 2000; Westmoreland *et al.*, 1986).

Although the pathophysiology of this electrical phenomenon has not been completely clarified, it was

Correspondence:

Antonio Federico
Department of Neurological, Behavioural and Neurosurgical Sciences,
Medical School,
University of Siena,
Viale Bracci 2,
53100 Siena, Italy
<federico@unisi.it>

doi:10.1684/epd.2012.0487

suggested that PLEDs may be the expression of an epileptic event (Bozkurt *et al.*, 2002; Assal *et al.*, 2001; Calarese *et al.*, 2008; Singh *et al.*, 2005).

From an electroencephalographic point of view, PLEDs can be distinguished as “PLEDs proper” or “PLEDs plus”, of which the latter are characterised by an association with low-amplitude paroxysmal rhythmic discharges (RDs) (Reiher *et al.*, 1991) and a more pronounced propensity to occur with seizures (Grand’Maison *et al.*, 1991; Reiher *et al.*, 1991; Jirsch and Hirsch, 2007).

PLEDs are reported in association with acute or sub-acute structural brain lesions such as stroke, tumours and central nervous system infections (Fitzpatrick and Lowry, 2007). Moreover, fever, hyperglycaemia or other metabolic disturbances may trigger PLEDs even in the absence of newly formed lesions by reducing the subject’s threshold for seizure susceptibility (Neufeld *et al.*, 1997; Raroque *et al.*, 1993).

In a few cases, PLEDs have been reported following carotid artery recanalisation in the context of acute reperfusion syndrome associated with cerebral oedema (Breen *et al.*, 1996).

Here, we report the case of a patient with temporal lobe partial epilepsy who developed PLEDs associated with loss of consciousness and absence of evident MRI changes following left internal carotid stenting. Possible pathogenetic mechanisms are discussed.

Case report

A 59-year-old woman presented with a history of hypertension and cryptogenic drug-resistant partial epilepsy, characterised by a rising epigastric sensation, followed by chewing and swallowing automatisms, with rare secondary tonic-clonic generalisation. Seizure onset was located in the right temporal lobe. Seizures started at age 22, following her first delivery. Her seizure frequency was about three to four episodes per year. EEGs showed rare epileptiform discharges and brief sequences of rhythmic theta activity affecting anterior and mid-temporal electrodes of the right hemisphere.

At the age of 57, she complained of acute onset of right-sided hemiplegia and aphasia due to left capsulothalamic haemorrhage. After the stroke, epileptic seizures were greatly reduced in frequency (one seizure per year), but showed consistent semiology. At the age of 59, a carotid Doppler ultrasound showed 75% left-sided internal carotid artery stenosis, confirmed by cerebral angiography; the patient was therefore referred for carotid artery stenting. Upon admission, the neurological examination showed right-sided severe spastic hemiparesis and mild Broca’s aphasia.

Three days after the stenting procedure, the patient became acutely confused and lethargic, with brainstem functions preserved and absence of both fever and meningeal signs. Brain MRI, including gadolinium contrast-enhanced and DWI sequences, did not show any new lesions (*figure 1*). EEG disclosed the presence of continuous paroxysmal pseudo-periodic activity affecting the left temporal parietal and occipital areas. The epileptiform discharges (PLEDs plus) consisted of brief bursts of polyspikes lasting around 300 mseconds, inconstantly followed by a slow wave, appearing with maximal amplitude at P3, O1 and T5 (*figure 2*). Neither the clinical picture nor the EEG pattern was influenced by benzodiazepines (4 mg lorazepam, repeated after 30 minutes) or phenytoin (bolus of 15 mg/kg) administered intravenously in addition to her habitual AED treatment. EEG monitoring was performed daily (40 minutes during wakefulness) during the first week after disease onset and on the tenth, sixteenth and twenty-third days thereafter. Neither subclinical electrographic nor overt clinical seizures were recorded.

Three days after the first EEG recording, the patient started to show a progressive improvement of clinical features paralleled by reduction of paroxysmal EEG activity which disappeared completely one week after the onset.

Discussion

PLEDs are an EEG pattern characterised by the presence of focal, unilateral and periodic epileptiform discharges with clinical evidence of disturbances of consciousness, cognitive deficits or epileptic seizures (Baykan *et al.*, 2000; Westmoreland *et al.*, 1986).

The pathophysiology of PLEDs is not yet completely clarified. Although such a pattern has been considered to be interictal or periictal, there is growing evidence supporting the hypothesis of an ictal significance for this EEG pattern (Grand’Maison *et al.*, 1991; Calarese *et al.*, 2008; Singh *et al.*, 2005; Jirsch and Hirsch, 2007). In addition, paroxysmal periodic EEG patterns, such as triphasic waves, may not be associated with epileptic conditions (e.g. Creutzfeldt-Jakob disease or hepatic encephalopathy).

The ictal nature of PLEDs is supported by the findings that both perfusion and behavioural changes are spatially and temporally correlated with EEG abnormalities. Similar to that in ictal SPECT studies, PLEDs are associated with hyperperfusion which tends to resolve along with EEG normalisation (Bozkurt *et al.*, 2002; Assal *et al.*, 2001). Other authors have demonstrated the occurrence of focal motor disturbances or changes in level of consciousness, time-locked to

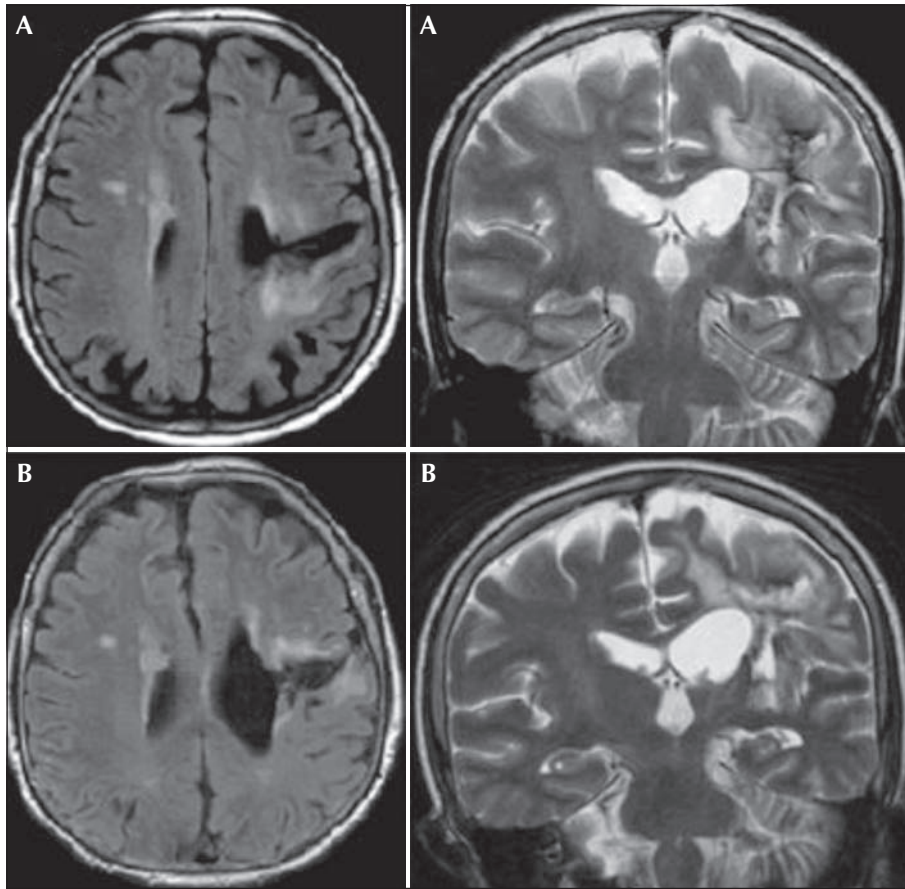


Figure 1. Flair axial and T2 coronal image before (A) and after (B) stenting procedure; left capsulo-thalamic haemorrhage with no evidence of new lesion after stent placement.

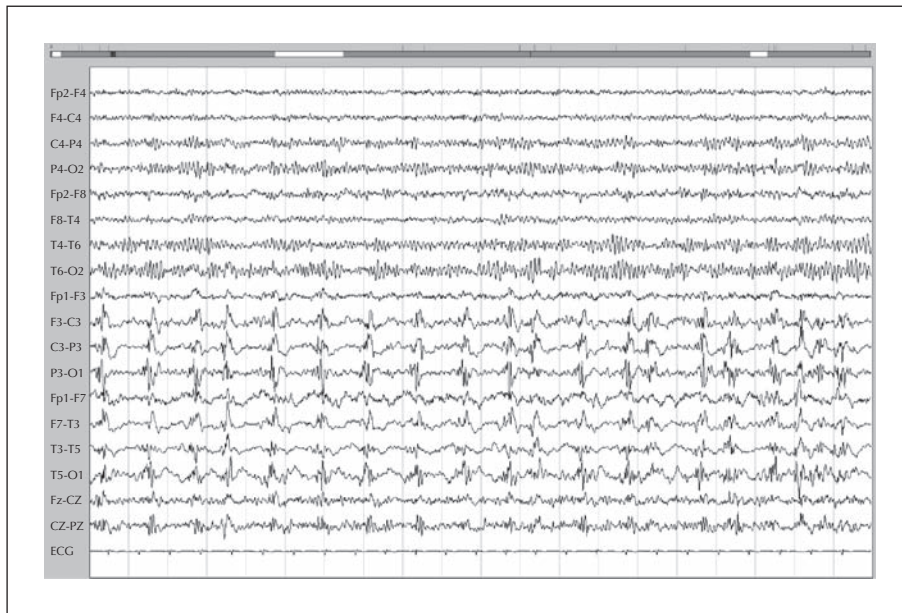

Figure 2. Third day after stent placement. Continuous spike and polyspike-wave discharges occurring in a pseudoperiodic fashion over the left hemisphere with maximal amplitude in parietal and temporal regions. Background activity is normal in the right hemisphere.

PLEDs (Grand'Maison *et al.*, 1991; Calarese *et al.*, 2008; Singh *et al.*, 2005; Jirsch and Hirsch, 2007).

Acute brain injuries may be followed by PLEDs or observed in association with subacute or chronic cerebral lesions or even in patients with normal MRI (Kalamangalam *et al.*, 2007). PLEDs, both proper and plus, can occur with any type of brain lesion, although PLEDs plus are less commonly observed with chronic lesions than PLEDs proper (Reiher *et al.*, 1991).

Besides cerebral structural changes, systemic metabolic disorders may play a role in precipitating such events, although the mechanism is still unknown (Neufeld *et al.*, 1997; Raroque *et al.*, 1993).

In a few cases, PLEDs have been observed following internal carotid artery stenting procedures (Breen *et al.*, 1996; Solomon *et al.*, 1986). In these cases, possible hyperperfusion syndrome (HPS) has been hypothesized, based on clinical and, above all, neuroradiological findings.

HPS is a condition that may follow treatment of cerebral artery stenosis, often associated with increased systemic blood pressure levels, characterised by disturbances of consciousness and MRI evidence of white and grey matter vasogenic oedema.

In cases following stenting procedures, it is thought that the increase in cerebral blood flow may cause vasogenic oedema due to massive reperfusion of maximally-dilated capillaries which have lost their autoregulatory capacity due to chronic ischaemia (Breen *et al.*, 1996; Solomon *et al.*, 1986). Several reports have documented that the risk of hyperperfusion syndrome after cerebral revascularization techniques, including extracranial carotid angioplasty and stenting, ranges from 0.4 to 2.7% (Liu *et al.*, 2001).

In our case, PLEDs occurred soon after internal carotid artery stenting. We suggest that in our patient, PLEDs had an ictal significance since there was a close parallel between the course of EEG abnormalities and clinical disturbances. We could not find any other explanation for such clinical changes since MRI and DWI studies were normal and no electrolyte imbalance or changes in blood pressure were detected.

Moreover, the close temporal link between the stenting procedure and appearance of PLEDs suggests a possible role for such a procedure in the development of the electroclinical disturbance. We believe that the resolution of carotid stenosis led to raised local blood perfusion in an area chronically hypoperfused and previously damaged by a haemorrhagic lesion.

The detailed MRI investigation performed after the onset of PLEDs allowed us to exclude any new cerebral lesions either of embolic origin or related to HPS. Therefore, we hypothesize that PLEDs were an ictal phenomenon and therefore responsible for changes in clinical status. We also believe that the EEG pattern,

observed after a stenting procedure, in the absence of newly occurring cerebral damage, may be a consequence of haemodynamic changes alone. Repetitive Transcranial Magnetic Stimulation (rTMS) studies have demonstrated that the cortical excitability is increased in the epileptic brain, not only close to the epileptic focus but also in the contralateral hemisphere (Läppchen *et al.*, 2008). On this basis, both a pre-existing brain lesion (Neufeld *et al.*, 1997; Raroque *et al.*, 1993) and seizure disorder (Läppchen *et al.*, 2008) may be predisposing factors. □

Disclosures.

This work was not supported by a grant and the authors have no other conflict of interest to declare

References

- Assal F, Papazyan JP, Slosman DO, Jallon P, Goerres GW. SPECT in periodic lateralized epileptiform discharges (PLEDs): a form of partial status epilepticus? *Seizure* 2001; 10: 260-5.
- Baykan B, Kinay D, Gökyigit A, Gürses C. Periodic lateralized epileptiform discharges: association with seizures. *Seizure* 2000; 9: 402-6.
- Bozkurt MF, Saygi S, Erbas B. SPECT in a patient with postictal PLEDs: is hyperperfusion evidence of electrical seizure? *Clin Electroencephalogr* 2002; 33: 171-3.
- Breen JC, Caplan LR, DeWitt LD, Belkin M, Mackey WC, O'Donnell TP. Brain edema after carotid surgery. *Neurology* 1996; 46: 175-81.
- Calarese T, Ferlazzo E, Daquin G, Genton P, Di Bella P, Villeneuve N. Ictal paresis associated to PLEDs in two children: a video-EEG study. *Seizure* 2008; 17: 735-9.
- Fitzpatrick W, Lowry N. PLEDs: clinical correlates. *Can J Neurol Sci* 2007; 34: 443-50.
- Grand'Maison F, Reiher J, Leduc CP. Retrospective inventory of EEG abnormalities in partial status epilepticus. *Electroencephalogr Clin Neurophysiol* 1991; 79: 264-70.
- Jirsch J, Hirsch LJ. Nonconvulsive seizures: developing a rational approach to the diagnosis and management in the critically ill population. *Clin Neurophysiol* 2007; 118: 1660-70.
- Kalamangalam GP, Diehl B, Burgess RC. Neuroimaging and neurophysiology of periodic lateralized epileptiform discharges: observations and hypotheses. *Epilepsia* 2007; 48: 1396-405.
- Läppchen CH, Feil B, Fauser S, Wuwer Y, Glocker FX, Schulze-Bonhage A. Changes in intracortical excitability after successful epilepsy surgery. *Epilepsy Res* 2008; 79: 55-62.
- Liu AY, Do HM, Albers GW, Lopez JR, Steinberg GK, Marks MP. Hyperperfusion syndrome with hemorrhage after angioplasty for middle cerebral artery stenosis. *AJNR Am J Neuroradiol* 2001; 22: 1597-601.
- Neufeld MY, Vishnevskaya S, Treves TA, et al. Periodic lateralized epileptiform discharges (PLEDs) following stroke are

associated with metabolic abnormalities. *Electroencephalogr Clin Neurophysiol* 1997; 102: 295-8.

Raroque HG Jr, Gonzales PC, Jhaveri HS, Leroy RF, Allen EC. Defining the role of structural lesions and metabolic abnormalities in periodic lateralized epileptiform discharges. *Epilepsia* 1993; 34: 279-83.

Reiher J, Rivest J, Grand'Maison F, Leduc CP. Periodic lateralized epileptiform discharges with transitional rhythmic discharges: association with seizures. *Electroencephalogr Clin Neurophysiol* 1991; 78: 12-7.

Singh G, Wright MA, Sander JW, Walker MC. Periodic lateralized epileptiform discharges (PLEDs) as the sole electrographic correlate of a complex partial seizure. *Epileptic Disord* 2005; 7: 37-41.

Solomon RA, Loftus CM, Quest DO, Correll JW. Incidence and etiology of intracerebral hemorrhage following carotid endarterectomy. *J Neurosurg* 1986; 64: 29-34.

Westmoreland BF, Klass DW, Sharbrough FW. Chronic periodic lateralized epileptiform discharges. *Arch Neurol* 1986; 43: 494-6.