

Efficacy of Prophylactic Blood Pressure Lowering according to a Standardized Postoperative Management Protocol to Prevent Symptomatic Cerebral Hyperperfusion after Direct Revascularization Surgery for Moyamoya Disease

Miki Fujimura^{a, b} Takashi Inoue^b Hiroaki Shimizu^c Atsushi Saito^b
Shunji Mugikura^d Teiji Tominaga^c

^aDepartment of Neurosurgery, National Hospital Organization, Sendai Medical Center, ^bDepartment of Neurosurgery, Kohnan Hospital, and Departments of ^cNeurosurgery and ^dRadiology, Tohoku University Graduate School of Medicine, Sendai, Japan

Key Words

Blood pressure lowering · Cerebral hyperperfusion · Extracranial-intracranial bypass · Moyamoya disease · Postoperative management

Abstract

Background: Cerebral hyperperfusion is a potential complication of superficial temporal artery-middle cerebral artery (STA-MCA) anastomosis for moyamoya disease, but the optimal postoperative management has not been determined. Aggressive blood pressure lowering is controversial because of the risk of ischemic complications. **Objective:** To establish the optimal postoperative management protocol to prevent symptomatic cerebral hyperperfusion in moyamoya disease. **Methods:** N-isopropyl-*p*-[¹²³I]-iodoamphetamine single-photon emission computed tomography was performed 1 and 7 days after STA-MCA anastomosis on 152 hemispheres from 108 consecutive patients with moyamoya disease (2–69, mean 33.3 years). Between 2004 and 2007 (period 1), 65 patients were maintained under normotensive conditions after 93 operations, and only patients with cerebral hyperperfusion underwent blood pressure lowering. Between

2008 and 2010 (period 2), all 43 patients were prospectively subjected to intensive blood pressure lowering (<130 mm Hg of systolic blood pressure) immediately after 59 operations. Then the incidence of symptomatic cerebral hyperperfusion was compared between the two groups. **Results:** Systolic blood pressure the day after surgery was significantly lower in period 2 (mean, 120.9 mm Hg) than in period 1 (133.9 mm Hg) ($p < 0.0001$). Symptomatic cerebral hyperperfusion was seen in 22 patients during period 1 (23 hemispheres, 24.7%), but only in 4 patients during period 2 (6.7%, $p = 0.0047$). Multivariate analysis revealed that prophylactic blood pressure lowering was significantly associated with the prevention of symptomatic cerebral hyperperfusion ($p = 0.015$). Symptomatic cerebral hyperperfusion was relieved in all patients without developing a permanent neurological deficit due to cerebral hyperperfusion. **Conclusion:** Prophylactic blood pressure lowering prevents symptomatic cerebral hyperperfusion after STA-MCA anastomosis in patients with moyamoya disease. Accurate diagnosis of cerebral hyperperfusion and blood pressure lowering, and considering the severity of hemodynamic compromise in the contralateral and/or remote areas are essential for postoperative management of moyamoya disease.

Copyright © 2012 S. Karger AG, Basel

Introduction

Moyamoya disease is a chronic, occlusive cerebrovascular disease of unknown etiology, characterized by bilateral steno-occlusive changes at the terminal portion of the internal carotid artery and an abnormal vascular network at the base of the brain [1]. Extracranial-intracranial (EC-IC) bypass such as superficial temporal artery-middle cerebral artery (STA-MCA) anastomosis is generally employed as the standard surgical treatment for moyamoya disease to prevent cerebral ischemic attacks [2–6]. Despite the favorable long-term outcome of STA-MCA anastomosis for moyamoya disease [4–6], increasing evidence suggests that cerebral hyperperfusion syndrome, as has been well described in patients undergoing carotid endarterectomy (CEA) [7–9], is a potential complication of EC-IC bypass, especially for moyamoya disease. Focal cerebral hyperperfusion was reported to cause transient neurological deterioration [3, 10–16] or delayed intracerebral hemorrhage (ICH) [17] during the acute stage after EC-IC bypass for moyamoya disease. Patients with moyamoya disease have a significantly higher risk for cerebral hyperperfusion syndrome than those with other occlusive cerebrovascular diseases based on routine postoperative cerebral blood flow (CBF) measurements using N-isopropyl-*p*-[¹²³I]-iodoamphetamine single-photon emission computed tomography (¹²³I-IMP-SPECT) [18].

The optimal postoperative management for avoiding the hyperperfusion syndrome has not yet been determined. Blood pressure lowering in patients with the hyperperfusion phenomenon is an effective treatment after revascularization surgery for moyamoya disease [3, 18], but aggressive blood pressure lowering to systolic blood pressure <120 mm Hg in all patients could be controversial because of the risk of perioperative ischemic complications in the contralateral hemisphere [19] and/or remote areas with hemodynamic compromise. To address this issue, we prospectively performed prophylactic blood pressure lowering applying a standardized management protocol for consecutive patients with moyamoya disease who underwent direct revascularization surgery with routine postoperative CBF measurement starting in 2008 [20]. We then compared the incidence of symptomatic cerebral hyperperfusion between this series and consecutive surgical patients operated on between 2004 and 2007 who had been treated under normotensive conditions after EC-IC bypass [3, 10], in order to establish the optimal postoperative management protocol for preventing symptomatic cerebral hyperperfusion in moyamoya disease.

Methods

Inclusion Criteria of Patients

Postoperative changes in CBF and clinical course were investigated in 108 consecutive patients with moyamoya disease (male/female = 30/78; 2–69 years old, mean 33.3 years) surgically treated in 152 hemispheres by the same surgeon (M.F.) between March 2004 and December 2010. Inclusion criteria of this study, corresponding to our surgical indications for STA-MCA anastomosis, included all of the following items: the presence of ischemic symptoms (minor completed stroke and/or transient ischemic attack, TIA), apparent hemodynamic compromise on SPECT as defined below, independent activity of daily living (modified Rankin scale scores 0–2) and absence of major cerebral infarction exceeding the vascular territory of one major branch of the MCA. All hemispheres that did not match these criteria were excluded from surgery, except for 3 hemispheres from 2 patients with a history of hemorrhage who were enrolled to the Japan Adult Moyamoya trial [21] and were randomly allocated to the surgically treated group. Besides these 2 patients participating in the Japan Adult Moyamoya trial, the present study included 8 patients with a history of hemorrhage; 10 hemispheres were operated on. All 8 patients simultaneously suffered from TIAs or cerebral infarction in the affected hemispheres before surgery, which matched our surgical indication.

Preoperative CBF was quantified by the autoradiographic method in most cases, and the CBF in each subregion was automatically calculated by 3D SRT (three-dimensional stereotactic region of interest template) software (version 2) provided by Daiichi Radio-Isotope (Tokyo, Japan) using ¹²³I-IMP-SPECT [3, 10]. The cerebral perfusion reserve capacity was quantified by the administration of acetazolamide. When the CBF at rest is <80% of normal CBF (about 42 ml/100 g/min) and/or reactivity to acetazolamide is <10%, we regard the CBF state as hemodynamic compromise. In pediatric patients with crescendo TIAs or in patients under the age of 4 we did not perform a preoperative quantitative CBF study but only qualitative ¹²³I-IMP-SPECT without acetazolamide stress. One adult patient with progressing stroke underwent only qualitative ¹²³I-IMP-SPECT without acetazolamide stress before surgery.

Once hemodynamic compromise was confirmed, the patients underwent revascularization surgery. All patients underwent STA-MCA (M4) anastomosis with encephaloduromyosynangiosis (EDMS) [10]. Patients were maintained under normotension, normovolemia and normocapnia during surgery, which was performed under intravenous anesthesia using propofol [22]. Craniotomy was performed around the Sylvian fissure end, approximately 8 cm in diameter, and the stump of the STA was anastomosed to the M4 segment of the MCA, which was followed by EDMS. To avoid postoperative compression of the brain surface by swollen temporal muscle used for EDMS [23], we drilled out the inner layer of the bone flap and made a relatively wide bone window at the site of EDMS graft insertion. All patients satisfied the diagnostic criteria of the Research Committee on Spontaneous Occlusion of the Circle of Willis of the Ministry of Health, Labor and Welfare, Japan [24], except for 5 patients with ‘probable moyamoya disease’, who showed unilateral involvement. Eight adult patients had associated cerebrovascular diseases, including 7 patients with atherosclerotic occlusive changes and 1

Table 1. Incidence of symptomatic cerebral hyperperfusion following EC-IC bypass in 152 hemispheres of moyamoya patients

	Overall	Period 1	Period 2	p value (period 1 vs. period 2)
Symptomatic HP	17.8% (27/152)	24.7% (23/93)	6.7% (4/59)	0.0047*
Focal ND	15.1% (23/152)	21.5% (20/93)	5.0% (3/59)	0.0059*
Symptomatic SAH or ICH	2.6% (4/152)	3.2% (3/93)	1.7% (1/59)	0.57

HP = Hyperperfusion; ND = neurological deficit. * Statistically significant.

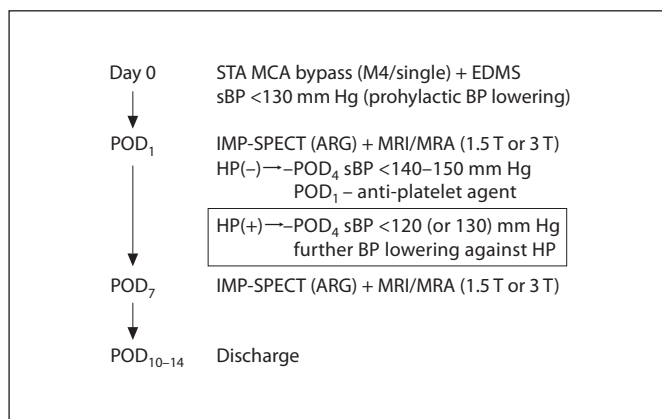


Fig. 1. Summary of the perioperative management protocol in period 2. Prophylactic blood pressure lowering was attempted starting immediately after revascularization surgery. sBP = Systolic blood pressure; HP = hyperperfusion; POD = postoperative day; ARG = autoradiographic.

patient with a cavernous malformation with a developmental venous anomaly. All patients were closely followed in our institutes for more than 6 months, with a mean follow-up period of 53.4 months.

Postoperative CBF Measurement and Diagnosis of Hyperperfusion

CBF was routinely measured by ^{123}I -IMP-SPECT 1 and 7 days after surgery in all patients. A postoperative computed tomography (CT) scan was routinely performed immediately after surgery and 1 day after surgery in all cases. 1.5- or 3-tesla magnetic resonance imaging (MRI) and magnetic resonance angiography (MRA) were routinely performed within 2 days after surgery. MRI included diffusion-weighted images, T_2 -weighted images, and T_2^* -weighted images in all cases. Fluid-attenuated inversion recovery (FLAIR) was also performed in most cases. The diagnostic criteria for symptomatic cerebral hyperperfusion included all of the following items [3, 18]: (1) presence of a significant focal increase in CBF, which confined to the vascular territory of one

major branch of the MCA at the site of the anastomosis that is responsible for the neurological signs, including focal neurological deficit and/or progressive/severe headache due to newly formed hemorrhagic changes; (2) apparent visualization of STA-MCA bypass by MRA and absence of any ischemic changes by diffusion-weighted images, and (3) absence of other pathologies, such as compression of the brain surface by the temporal muscle inserted for indirect pial synangiosis, ischemic attack, venous infarction, interruption of transdural collaterals and CBF increase secondary to seizure. In addition to these items, blood pressure-dependent aggravation of the symptoms and/or amelioration of the symptoms by blood pressure lowering clinically confirmed the diagnosis of symptomatic hyperperfusion in all cases. In most patients with progressive/severe headache with hemorrhagic changes, manual compression of STA at the preauricular region attenuated the symptom.

The occurrence of symptomatic cerebral hyperperfusion after revascularization surgery was evaluated by ^{123}I -IMP-SPECT in the acute stage. Mortality and morbidity due to cerebral hyperperfusion were also evaluated 3 months after revascularization surgery. We investigated the correlation between postoperative CBF changes and clinical presentation in both periods, and compared the incidence of symptomatic cerebral hyperperfusion between the two groups.

Postoperative Management in Two Distinct Periods

During the initial period from March 2004 to December 2007 (period 1), 65 patients underwent STA-MCA anastomosis with EDMS in 93 hemispheres, and were maintained under normotensive conditions (<150–160 mm Hg systolic blood pressure) after surgery (table 1). If ^{123}I -IMP-SPECT suggested cerebral hyperperfusion on the day after surgery, the patients underwent mild blood pressure lowering (<140 mm Hg systolic blood pressure) to avoid the deleterious effects of cerebral hyperperfusion while considering the risk of a contralateral ischemic complication. Only patients who developed symptomatic hyperperfusion were subjected to intensive blood pressure lowering (<130 mm Hg systolic blood pressure). During period 2, between January 2008 and December 2010, 43 patients underwent STA-MCA anastomosis with EDMS in 59 hemispheres, and were prospectively subjected to prophylactic intensive blood pressure lowering (<130 mm Hg systolic blood pressure) irrespective of patients' age, using a 1–10 mg/h continuous intravenous drip infu-

sion of nicardipine hydrochloride, immediately after surgery in the operation room (fig. 1) [20] because most of the cases of symptomatic hyperperfusion in period 1 were resolved by blood pressure lowering <130 mm Hg systolic blood pressure irrespective of the preoperative blood pressure. To avoid unfavorable effects of intensive blood pressure lowering on the contralateral hemisphere and/or ipsilateral remote areas, we routinely administered antiplatelet agents (100 mg aspirin/day, or 200 mg cilostazol/day) starting on the day after surgery in period 2, in light of the observation that antiplatelet agents have preventive effects on ischemic stroke in moyamoya disease [25] and that abnormal thrombogenesis was found to be involved in the pathophysiology of moyamoya disease in autopsy cases [26]. Based on the temporal profile of ^{123}I -IMP-SPECT and MRI/MRA findings, we gradually allowed a return to normotensive conditions within 7–10 days after surgery. If ^{123}I -IMP-SPECT 7 days after surgery showed a mild increase in CBF in the entire MCA territory compared to the preoperative status, we considered that the hyperperfusion phenomenon was ameliorated, and allowed them to return to their baseline blood pressure level. If ^{123}I -IMP-SPECT at 7 days still demonstrated a focal intense increase in CBF at the site of the anastomosis, we continued blood pressure control and repeated ^{123}I -IMP-SPECT several days later. The details of our management protocol in period 2 are summarized in figure 1.

Statistical Analysis

The incidence of symptomatic cerebral hyperperfusion was compared between the two periods using the χ^2 test. Systolic blood pressure 1 day after surgery was compared between the two periods using Student's *t* test. Patient ages were compared between the two periods using Student's *t* test. Since age and history of ICH are known to be related to symptomatic cerebral hyperperfusion after STA-MCA anastomosis for moyamoya disease [3], multivariate statistical analysis of the factors related to the development of symptomatic cerebral hyperperfusion, including management period (period 1 or period 2), age, sex, operated side, history of ICH, and systolic blood pressure (mm Hg) 1 day after surgery was performed using a logistic regression model.

Results

Overall Results during the Two Periods

Among the 108 consecutive patients with 152 operated hemispheres, 26 patients (27 hemispheres, 17.8% of 152 operated hemispheres) demonstrated temporary neurological deterioration, including mild focal neurological signs, due to postoperative focal cerebral hyperperfusion between 2 and 14 days after surgery (table 1). Postoperative MRI did not show any ischemic changes in the 27 hemispheres. Postoperative MRA demonstrated a thick high signal intensity of STA in the operated hemisphere in all 27 hemispheres. Postoperative SPECT demonstrated significant intense increases in CBF at the sites of anastomosis in all 27 hemispheres. Twenty-two patients (23

hemispheres, 15.1%) demonstrated transient focal neurological deficits due to focal hyperperfusion, starting between 2 and 9 days after surgery and persisting for several days. In all cases, the symptoms fluctuated in a blood pressure-dependent manner, which further supported the diagnosis of symptomatic hyperperfusion. The anatomical location and temporal profile of hyperperfusion were completely in accordance with the transient neurological signs in all 22 patients. The detail of the neurological signs after 23 operations was as follows; hemiparesis and/or facial palsy in 14, aphasia in 12, and sensory disturbance on the contralateral side of the operation in 3 (some patients had multiple symptoms). Five patients demonstrated dysarthria in addition to the above-mentioned symptoms. One patient suffered from prolonged dysarthria and sensory disturbance, and ultimately developed simple partial seizures that were apparently secondary to hyperperfusion [10]. None of the other 21 patients developed seizures during the postoperative period. Four patients (4 hemispheres, 2.6%) complained of progressive/severe headache and demonstrated cerebral hyperperfusion syndrome associated with subarachnoid hemorrhage (SAH) in 3 patients (2.0%) or with ICH at the right frontal sub-cortex in 1 patient (0.66%) [17]. In all 3 patients with progressive headache due to SAH, manual compression of STA at the preauricular region ameliorated the symptoms. The distribution of newly formed SAH or ICH, demonstrated by CT scan, was in accordance with the site of the anastomosis in all 4 patients and such hemorrhagic changes were not evident immediately after surgery, thus we diagnosed them as having symptomatic hemorrhage due to cerebral hyperperfusion. None of the patients demonstrated any permanent neurological deficits due to cerebral hyperperfusion and no patients suffered from delayed neurological deterioration due to cerebral hyperperfusion during the follow-up period.

Among 108 consecutive patients with 152 operated hemispheres, there were no patients with perioperative cerebral infarction, except for the 4 patients as detailed below. Three patients in period 1 (2.0%) presented with pseudolaminar necrosis identified by MRI, probably due to the transient ischemia caused by a thrombotic event in the portion of the cerebral cortex supplied by the STA-MCA bypass in the subacute stage which did not affect their long-term neurological status [2]. One patient in period 2 (1.7%) with ipsilateral preoperative posterior cerebral artery (PCA) stenosis and an atherosclerotic background presented with cerebral infarction 3 days after surgery in the ipsilateral occipital lobe during intensive

Table 2. Incidence of symptomatic cerebral hyperperfusion following EC-IC bypass

	Period 1	Period 2
Hemispheres and patients, n	93 (65 patients)	59 (43 patients)
Age, years		
Range	2–66	9–69
Mean	33.2	33.4
Sex, male/female	18/47	11/32
Symptomatic hyperperfusion	23 (24.7%)	4 (6.7%)*
Systolic blood pressure (POD ₁) mm Hg	133.9	120.9**

POD₁ = Postoperative day 1. * $p = 0.0047$, ** $p < 0.00001$, significantly lower.

Table 3. Multivariate analysis of symptomatic cerebral hyperperfusion in moyamoya disease

	Odds ratio	p value
Prophylactic BP lowering, period 2	2.158	0.015 ¹
Age	0.971	0.050
Female sex	0.890	0.661
Hemisphere operated on, left	1.174	0.480
History of hemorrhage	0.674	0.268
Systolic BP, POD ₁	0.996	0.822

BP = Blood pressure; POD₁ = postoperative day 1. ¹ Significant association.

blood pressure control for symptomatic SAH due to hyperperfusion, indicating the potential risk for cerebral ischemia in the contralateral hemisphere and/or ipsilateral remote area during blood pressure lowering. However, this did not affect her long-term activity of daily living. All patients with onset of TIA showed disappearance or improvement of the ischemic attack during the follow-up period. One ischemic-onset patient (0.66%) treated during period 1 developed ICH of the ipsilateral thalamus 3 years after successful revascularization surgery. Therefore, she showed deterioration of the modified Rankin scale score from 0 to 3 after the hemorrhage. Two patients in period 1, who presented with hemorrhage as their initial presentation, developed rebleeding (1.31%), 1 from a contralateral ICH and one from SAH, but neither patient showed deterioration of their neurological status. On the postoperative MRA, the patency of the STA-MCA

bypass was confirmed in all 108 patients in 152 operated hemispheres.

Background and Incidence of Cerebral Hyperperfusion in Each Group

As shown in tables 1 and 2, the incidence of symptomatic cerebral hyperperfusion including mild focal neurological signs was significantly lower in period 2 under prophylactic blood pressure lowering (4/59; 6.7%) than in period 1 (23/93 hemispheres, 24.7%) ($p = 0.0047$). As for the clinical presentation of cerebral hyperperfusion in each period, transient focal neurologic signs were seen in 19 patients in period 1 (20/93 hemispheres, 21.5%), but only in 3 period-2 patients (3/59; 5.0%, $p = 0.0059$) (table 1). Symptomatic hemorrhage due to cerebral hyperperfusion was found in 3 patients (3/93 hemispheres, 3.2%) in period 1, and in 1 (1/59; 1.7%) in period 2, showing no significant difference between the two periods ($p = 0.57$). Symptomatic cerebral hyperperfusion was relieved in all patients, and none of the patients developed permanent neurological deficits due to hyperperfusion. Systolic blood pressure on the day after surgery was significantly lower in period 2 (mean 120.9 mm Hg) than in period 1 (133.9 mm Hg) ($p < 0.00001$). The average patient age was 33.2 years in period 1 and 33.4 in period 2, showing no significant difference between the two periods ($p = 0.949$) (table 2). Of the 108 patients in both periods, patients with symptomatic hyperperfusion were significantly older (mean 39.4 years) than those without symptomatic hyperperfusion (mean 31.9 years) ($p = 0.031$). Multivariate analysis demonstrated that prophylactic blood pressure lowering (period 2) was significantly associated with prevention of symptomatic cerebral hyperperfusion ($p = 0.006$) as shown in table 3. Patient age was not found to be associated with symptomatic cerebral hyperperfusion by multivariate analysis ($p = 0.050$). There was no significant association between sex ($p = 0.661$), side of the operated hemisphere (0.480), past history of hemorrhage (0.268), and systolic blood pressure 1 day after surgery (0.822) and the occurrence of symptomatic hyperperfusion (table 3).

Representative Case in Period 2 Suggesting a Potential Risk for Symptomatic Hyperperfusion in Asymptomatic Patients

A 57-year-old woman presented with minor completed stroke in the left hemisphere, and was found to have moyamoya disease. She was surgically treated in period 2. Digital subtraction angiography demonstrated stenocclusive changes at the terminal portion of the bilateral

internal carotid artery, and development of an abnormal vascular network at the base of the brain, predominantly in the left hemisphere. Preoperative ^{123}I -IMP-SPECT 1 month after the onset of stroke showed significant hemodynamic compromise in the entire left hemisphere (fig. 2a). She underwent STA-MCA anastomosis with EDMS in the left hemisphere 2 months after the onset of stroke. The recipient artery at the M4 segment of the frontal branch of the MCA was explored and anastomosis was performed between the stump of the STA (1.0 mm in diameter) and the M4 segment (1.0 mm in diameter) that supplied the left premotor cortex. The temporary occlusion time was 20 min. The patient's systolic blood pressure was strictly maintained at <130 mm Hg starting immediately after surgery. The patient did not demonstrate any neurological signs after surgery. ^{123}I -IMP-SPECT 1 day after surgery demonstrated a focal intense increase in CBF at the site of the anastomosis (fig. 2b). The MRI performed 1 day after surgery did not show any evidence of ischemic change, and the MRA demonstrated thick high signal intensity of the STA (fig. 3c). FLAIR imaging demonstrated asymptomatic SAH at the left Sylvian cistern extending to the left frontoparietal lobe sulcus (fig. 3a, b), which was consistent with the result of the CT scan 1 day after surgery, demonstrating faint SAH which was not evident immediately after surgery. The patient did not show any sign of infection including postoperative meningitis. Based on these findings suggesting cerebral hyperperfusion, more intensive blood pressure lowering (systolic blood pressure <120 mm Hg) was performed. She did not develop any neurological deterioration or seizure nor did she complain of headache during the postoperative period. ^{123}I -IMP-SPECT obtained 7 days after surgery indicated amelioration of the focal hyperperfusion in the left hemisphere (fig. 2c), and FLAIR imaging showed a significant decrease in asymptomatic SAH (fig. 3d, f). She was discharged without neurological deficit 14 days after surgery, and there were no cerebrovascular events during the follow-up period.

Discussion

In the present study, we prospectively introduced a standardized postoperative management protocol including prophylactic intensive blood pressure lowering (systolic blood pressure <130 mm Hg) immediately after STA-MCA anastomosis for moyamoya disease in order to prevent a postoperative hyperperfusion syn-

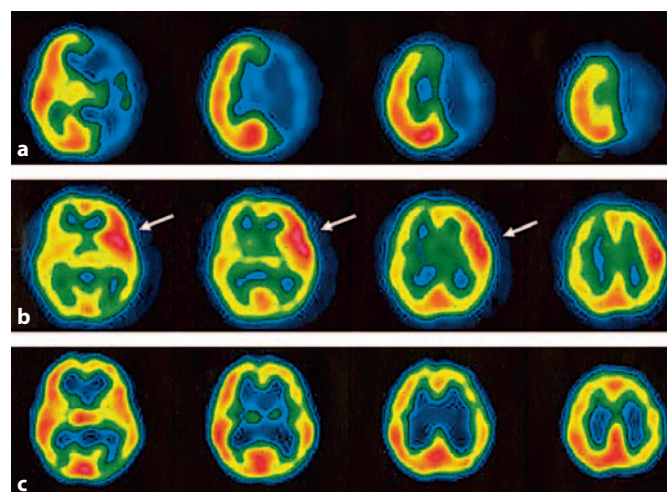


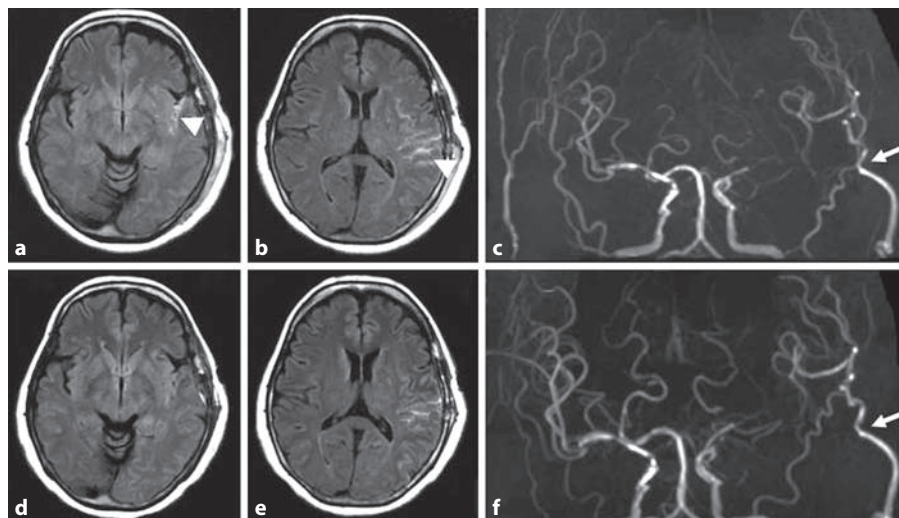
Fig. 2. Representative case in period 2: a 57-year-old woman with moyamoya disease presenting with minor stroke. ^{123}I -IMP-SPECT before (a) and after (b, c) left STA-MCA anastomosis with pial synangiosis. Significant hemodynamic compromise in the left hemisphere was shown before surgery (a). Marked increase in CBF at the site of the anastomosis was evident (arrows in b) 1 day after surgery, and was ameliorated at 7 days after surgery (c). There was no difference in the CBF in the right hemisphere before (a) and after surgery (b, c).

drome. We demonstrated, for the first time, that prophylactic intensive blood pressure lowering significantly ameliorates symptomatic cerebral hyperperfusion after STA-MCA anastomosis for moyamoya disease. Accurate diagnosis by flow study and further blood pressure lowering in patients with cerebral hyperperfusion is essential to prevent cerebral hyperperfusion including symptomatic hemorrhage, seizure and neurological deterioration.

Higher Incidence of Symptomatic Cerebral Hyperperfusion following EC-IC Bypass for Moyamoya Disease

Symptomatic cerebral hyperperfusion following EC-IC bypass for atherosclerotic occlusive cerebrovascular disease is relatively rare and generally manifests as a mild focal neurological deficit that resolves within 2 weeks [27, 28]. Heros et al. [27] were the first to report cerebral hyperperfusion in 5 patients with atherosclerotic ischemic disease who presented with temporary neurological deterioration after STA-MCA bypass surgery among 134 patients (3.7%). The symptoms resolved in all 5 patients within 2 weeks after surgery. In a recent contribution, Yamaguchi et al. [29] reported a 6.0% (3/50) incidence of

Fig. 3. Postoperative FLAIR by MRI 1(**a, b**) and 7 days (**d, e**) after surgery in a 57-year-old woman, demonstrating asymptomatic SAH in the left Sylvian cistern extending to the ipsilateral fronto-temporal sulcus (arrowheads in **a, b**). SAH was decreased 7 days after surgery (**d, f**). MRA 1 (**c**) and 7 days (**f**) after STA-MCA anastomosis with pial synangiosis, demonstrating STA-MCA bypass as a thick high signal sign (arrows in **c, f**).



symptomatic cerebral hyperperfusion under strict blood pressure control and propofol sedation. Our most recent study using routine postoperative CBF measurements by ^{123}I -IMP-SPECT after STA-MCA (M4) anastomosis for moyamoya and non-moyamoya patients showed that none of the patients in the non-moyamoya group (0/28; 0%) versus 25 patients (26/121 hemispheres, 21.5%) in the moyamoya group developed symptomatic cerebral hyperperfusion after STA-MCA anastomosis ($p = 0.0069$) [18]. The incidence of symptomatic cerebral hyperperfusion in patients with moyamoya disease has been suggested to be as high as 16.7–28.1% [3, 12, 16] when mild focal neurological signs are included. In the present study, the incidence of symptomatic cerebral hyperperfusion was 24.7% (23/93 hemispheres) when the patients were managed under normotensive conditions and only patients demonstrating hyperperfusion on postoperative SPECT underwent blood pressure lowering (period 1), which is almost in agreement with the previous reports [3, 12, 16].

Management of Cerebral Hyperperfusion after EC-IC Bypass

Since delayed ICH [17] and symptomatic SAH due to cerebral hyperperfusion after STA-MCA anastomosis [18] have been reported in patients with moyamoya disease, STA-MCA anastomosis, although it provides low flow revascularization, is considered to entail substantial risks of surgical morbidity due to hyperperfusion. Intensive blood pressure lowering in patients with evidence of hyperperfusion on flow study, while considering the risk

of ischemic complication on the contralateral and/or remote areas with hemodynamic compromise, is generally accepted as the standard management of cerebral hyperperfusion after EC-IC bypass for moyamoya disease [3, 10, 11, 18]. The intraoperative and/or postoperative use of free-radical scavengers could be an acceptable additional management to ameliorate secondary brain injury due to cerebral hyperperfusion as reported in patients undergoing CEA [30]. Regarding EC-IC bypass for atherosclerotic occlusive cerebrovascular disease, Yamaguchi et al. [29] recently recommended continuous, strict blood pressure control under continuous sedation immediately after surgery. In their study, all patients were managed in the intensive care unit under continuous propofol sedation, based on the rationale that systemic blood pressure is more easily controlled and hyperperfusion more effectively prevented under propofol sedation compared with wakefulness. But intensive blood pressure lowering for moyamoya patients has generally been controversial because of the risk of ischemic complications in the contralateral and/or remote hemodynamically compromised areas [19], especially under continuous propofol sedation that precludes monitoring of the patient's neurological status during hemodynamic changes. In the present study, we prospectively performed prophylactic blood pressure lowering in conscious patients immediately after revascularization surgery, which resulted in significant amelioration of symptomatic cerebral hyperperfusion compared to previous treatment under normotensive conditions. However, even when applying the recent protocol of prophylactic blood pressure lowering, we ob-

served symptomatic cerebral hyperperfusion in 4 patients (4/59 hemispheres, 6.7%) as well as 2 cases with asymptomatic hemorrhage including the representative case (fig. 2, 3). Furthermore, 1 adult patient sustained a minor stroke in the ipsilateral occipital lobe, in the vascular territory of the stenotic PCA revealed by the preoperative angiogram, during intensive blood pressure lowering for symptomatic cerebral hyperperfusion in period 2, pointing to the potential risk of ischemic complications under intensive blood pressure lowering. In fact, Khan et al. [19] reported 1 adult patient with moyamoya disease who died after revascularization surgery due to a massive MCA infarct on the nonoperated side.

Based on this finding, it is conceivable that patients with PCA stenosis, as observed in patients with advanced Suzuki's angiographic staging (stage IV–), which is a significant risk factor for recurrent stroke after surgery [31], could have a higher risk of ischemic complications during intensive blood pressure lowering because the PCA territory could not benefit from revascularization surgery in the acute stage. An additional strategy with more selective management that focuses on the molecular pathway underlying cerebral hyperperfusion is warranted to counteract this deleterious phenomenon.

Mechanism of Cerebral Hyperperfusion and Feasibility of an Additional Strategy

The mechanism underlying the occurrence of the cerebral hyperperfusion syndrome in moyamoya disease is undetermined, but could be explained as follows: firstly, in patients undergoing CEA or EC-IC bypass for atherosclerotic occlusive cerebrovascular disease, impaired cerebrovascular reactivity is reported to be a predictive factor of cerebral hyperperfusion [29, 32]. Therefore, the presence of hemodynamic compromise, including decreased cerebrovascular reactivity, could definitively be a background of the risk for cerebral hyperperfusion in moyamoya disease. Secondly, the intrinsic vulnerability of the microvascular structure in moyamoya disease, such as medial thinness, abnormality of the internal elastic lamina, and accumulation of necrotic cell components in the interstitium [33, 34] may facilitate the occurrence of hemorrhagic changes due to hyperperfusion. Thirdly, excessive production of reactive oxygen species during revascularization [35] and subsequent activation of inflammatory molecules such as vascular endothelial growth factor (VEGF) [36, 37] and matrix metalloproteinase (MMP)-9 [36, 38] may affect vascular permeability and thus result in transient neurological deterioration and/or hemorrhagic complications. In fact, VEGF [36, 37]

and MMP-9 [36, 38], both of which play a potential role in increasing the permeability of the blood-brain barrier, is significantly increased in moyamoya patients compared to healthy controls. These observations suggest that the increased expression of VEGF and MMP-9 in patients with moyamoya disease [36–38] may facilitate, at least in part, the occurrence of cerebral hyperperfusion in moyamoya disease. Based on these observations, the prophylactic blockade of VEGF and/or MMP-9 in patients with moyamoya disease could be an additional therapeutic approach to counteract postoperative cerebral hyperperfusion in moyamoya disease. Finally, we used nicardipine to lower postoperative blood pressure in period 2. Since nicardipine was reported to have a protective effect against cerebral ischemia [39] and hypertension-induced brain damage [40], we do not rule out the possibility that prophylactic use of nicardipine might have contributed in part to the prevention of symptomatic hyperperfusion in our study. Elucidation of the mechanism of cerebral hyperperfusion in moyamoya disease is necessary to develop a definitive perioperative management protocol to avoid surgical complications including both cerebral hyperperfusion and cerebral ischemia.

Limitation of the Present Study

Previous reports including our studies have indicated that symptomatic cerebral hyperperfusion is a potential complication of EC-IC bypass for moyamoya disease. However, except for the most recent study by Kawamata et al. [41], all the previous reports [2, 3, 10–18] lacked the quantitative definition of 'hyperperfusion phenomenon' in moyamoya disease. Our present study has a similar limitation, since we could not yet define the threshold of the 'pathological increase in CBF after EC-IC bypass' for moyamoya disease. The reason why it is difficult to propose a quantitative definition of the cerebral hyperperfusion phenomenon after EC-IC bypass for moyamoya disease is as follows. Firstly, unlike the hyperperfusion syndrome after CEA [7–9], the increase in CBF is usually localized in a small area under the site of the anastomosis, thus the quantitative postoperative CBF value may totally depend on the setting of the region of interest. Secondly, susceptibility to the 'hyperperfusion phenomenon' seems to vary from one moyamoya patient to another, and various biological factors other than cerebral hemodynamics, such as intrinsic fragility of pial artery anatomy [33, 34], development of leptomeningeal anastomosis, and/or increased expression of inflammatory molecules related to blood-brain barrier impermeability [36–38],

may strongly affect the clinical response in the presence of increased CBF immediately after surgery. Therefore, we speculate that patients with moyamoya disease could be symptomatic even with a CBF increase <100% compared to the preoperative value, unlike the definition of the hyperperfusion phenomenon after CEA [7–9]. Quantitative evaluation of postoperative CBF after EC-IC bypass in consecutive cases with moyamoya disease is necessary to answer this important question. Alternatively, further evaluation of cerebral metabolism by positron emission tomography and/or evaluation of the cortex with hyperperfusion by apparent diffusion coefficient images and MRI would be of great value to address this important issue.

Conclusion

Prophylactic blood pressure lowering ameliorates symptomatic cerebral hyperperfusion after STA-MCA anastomosis in patients with moyamoya disease. Accurate diagnosis of hyperperfusion and intensive blood pressure lowering while considering the severity of hemodynamic compromise in the contralateral and/or remote areas are essential for postoperative management of moyamoya disease.

Disclosure Statement

None.

References

- 1 Suzuki J, Takaku A: Cerebrovascular 'moyamoya' disease. Disease showing abnormal net-like vessels in base of brain. *Arch Neurol* 1969;20:288–299.
- 2 Fujimura M, Kaneta T, Tominaga T: Efficacy of superficial temporal artery-middle cerebral artery anastomosis with routine postoperative cerebral blood flow measurement during the acute stage in childhood moyamoya disease. *Childs Nerv Syst* 2008;24:827–832.
- 3 Fujimura M, Mugikura S, Kaneta T, Shimizu H, Tominaga T: Incidence and risk factors for symptomatic cerebral hyperperfusion after superficial temporal artery-middle cerebral artery anastomosis in patients with moyamoya disease. *Surg Neurol* 2009;71:442–447.
- 4 Guzman R, Lee M, Achrol A, Bell-Stephens T, Kelly M, Do HM, Marks MP, Steinberg GK: Clinical outcome after 450 revascularization procedures for moyamoya disease. *J Neurosurg* 2009;111:927–935.
- 5 Houkin K, Ishikawa T, Yoshimoto T, Abe H: Direct and indirect revascularization for moyamoya disease: surgical techniques and peri-operative complications. *Clin Neurol Neurosurg* 1997;99(suppl 2):S142–S145.
- 6 Okada Y, Shima T, Nishida M, Yamane K, Yamada T, Yamanaka C: Effectiveness of superficial temporal artery-middle cerebral artery anastomosis in adult moyamoya disease: cerebral hemodynamics and clinical course in ischemic and hemorrhagic varieties. *Stroke* 1998;29:625–630.
- 7 Piepgras DG, Morgan MK, Sundt TM Jr, Yanagihara T, Mussman LM: Intracerebral hemorrhage after carotid endarterectomy. *J Neurosurg* 1988;68:532–536.
- 8 Solomon RA, Loftus CM, Quest DO, Correll JW: Incidence and etiology of intracerebral hemorrhage following carotid endarterectomy. *J Neurosurg* 1986;64:29–34.
- 9 Sundt TM Jr, Sharbrough FW, Piepgras DG, Kearns TP, Messick JM, O'Fallon WM: Correlation of cerebral blood flow and electroencephalographic changes during carotid endarterectomy: with results of surgery and hemodynamics of cerebral ischemia. *Mayo Clin Proc* 1981;56:533–543.
- 10 Fujimura M, Kaneta T, Mugikura S, Shimizu H, Tominaga T: Temporary neurologic deterioration due to cerebral hyperperfusion after superficial temporal artery-middle cerebral artery anastomosis in patients with adult-onset moyamoya disease. *Surg Neurol* 2007;67:273–282.
- 11 Furuya K, Kawahara N, Morita A, Momose T, Aoki S, Kirino T: Focal hyperperfusion after superficial temporal artery-middle cerebral artery anastomosis in a patient with moyamoya disease. Case report. *J Neurosurg* 2004;100:128–132.
- 12 Kim JE, Oh CW, Kwon OK, Park SQ, Kim SE, Kim YK: Transient hyperperfusion after superficial temporal artery/middle cerebral artery bypass surgery as a possible cause of postoperative transient neurological deterioration. *Cerebrovasc Dis* 2008;25:580–586.
- 13 Kohama M, Fujimura M, Mugikura S, Tominaga T: Temporal change of 3-T magnetic resonance imaging/angiography during symptomatic cerebral hyperperfusion following superficial temporal artery-middle cerebral artery anastomosis in a patient with adult-onset moyamoya disease. *Neurosurg Rev* 2008;31:451–455.
- 14 Nakagawa A, Fujimura M, Arafune T, Sakuma I, Tominaga T: Clinical implications of intraoperative infrared brain surface monitoring during superficial temporal artery-middle cerebral artery anastomosis in patients with moyamoya disease. *J Neurosurg* 2009;111:1158–1164.
- 15 Ogasawara K, Komoribayashi N, Kobayashi M, Fukuda T, Inoue T, Yamada K, Ogawa A: Neural damage caused by cerebral hyperperfusion after arterial bypass surgery in a patient with moyamoya disease: case report. *Neurosurgery* 2005;56:E1380.
- 16 Ohue S, Kumon Y, Kohno K, Watanabe H, Iwata S, Ohnishi T: Postoperative temporary neurological deficits in adults with moyamoya disease. *Surg Neurol* 2008;69:281–286.
- 17 Fujimura M, Shimizu H, Mugikura S, Tominaga T: Delayed intracerebral hemorrhage after superficial temporal artery-middle cerebral artery anastomosis in a patient with moyamoya disease: possible involvement of cerebral hyperperfusion and increased vascular permeability. *Surg Neurol* 2009;71:223–227.
- 18 Fujimura M, Shimizu H, Inoue T, Mugikura S, Saito A, Tominaga T: Significance of focal cerebral hyperperfusion as a cause of transient neurologic deterioration after EC-IC bypass for moyamoya disease: Comparative study with non-moyamoya patients using ¹²³I-IMP-SPECT. *Neurosurgery* 2011;68:957–965.
- 19 Khan N, Schuknecht B, Boltshauser E, Capone A, Buck A, Imhof HG, Yonekawa Y: Moyamoya disease and moyamoya syndrome: experience in Europe: Choice of revascularisation procedures. *Acta Neurochir (Wien)* 2003;145:1061–1071.
- 20 Tominaga T, Fujimura M: Outcome of revascularization surgery for moyamoya disease under standardized peri-operative management protocol. Annual Report by the Research Committee on Spontaneous Occlusion of the Circle of Willis (Moyamoya Disease) of Health and Labour Science Research Grants (in Japanese). *Res Measures Intract Dis (Japan)* 2009;30:5–6.

- 21 Miyamoto S; Japan Adult Moyamoya Trial Group: study design for a prospective randomized trial of extracranial-intracranial bypass surgery for adults with moyamoya disease and hemorrhagic onset – the Japan Adult Moyamoya Trial Group. *Neurol Med Chir (Tokyo)* 2004;44:218–219.
- 22 Kikuta K, Takagi Y, Nozaki K, Yamada K, Miyamoto S, Kataoka H, Arai T, Hashimoto N: Effects of intravenous anesthesia with propofol on regional cortical blood flow and intracranial pressure in surgery for moyamoya disease. *Surg Neurol* 2007;68:421–424.
- 23 Fujimura M, Kaneta T, Shimizu H, Tomimaga T: Cerebral ischemia owing to compression of the brain by swollen temporal muscle used for encephalo-myo-synangiosis in moyamoya disease. *Neurosurg Rev* 2009;32:245–249.
- 24 Fukui M: Guidelines for the diagnosis and treatment of spontaneous occlusion of the circle of Willis ('moyamoya' disease). Research Committee on Spontaneous Occlusion of the Circle of Willis (Moyamoya Disease) of the Ministry of Health and Welfare, Japan. *Clin Neurol Neurosurg* 1997;99(suppl 2):S238–S240.
- 25 Research on intractable disease of the Ministry of Health, Labour and Welfare, Japan. Recommendations for the Management of Moyamoya Disease. A Statement from Research Committee on Spontaneous Occlusion of the Circle of Willis (Moyamoya Disease) (in Japanese). *Surg Cereb Stroke* 2009;37:321–337.
- 26 Ikeda E, Hosoda Y: Distribution of thrombotic lesion in the cerebral arteries in spontaneous occlusion of the circle of Willis: cerebrovascular moyamoya disease. *Clin Neuropathol* 1993;12:44–48.
- 27 Heros RC, Scott RM, Ackerman RH, Conner ES: Temporary neurological deterioration after extracranial-intracranial bypass. *Neurosurgery* 1984;15:178–185.
- 28 Kuroda S, Kamiyama H, Abe H, Asaoka K, Mitsumori K: Temporary neurological deterioration caused by hyperperfusion after extracranial-intracranial bypass: case report and study of cerebral hemodynamics. *Neurol Med Chir (Tokyo)* 1994;34:15–19.
- 29 Yamaguchi K, Kawamata T, Kawashima A, Hori T, Okada Y: Incidence and predictive factors of cerebral hyperperfusion after extracranial-intracranial bypass for occlusive cerebrovascular diseases. *Neurosurgery* 2010;67:1548–1554.
- 30 Ogasawara K, Inoue T, Kobayashi M, Endo H, Fukuda T, Ogawa A: Pretreatment with the free radical scavenger edaravone prevents cerebral hyperperfusion after carotid endarterectomy. *Neurosurgery* 2004;55:1060–1067.
- 31 Huang AP, Liu HM, Yang CC, Tsai YH, Wang KC, Yang SH, Kuo MF, Tu YK: Clinical significance of posterior circulation changes after revascularization in patients with moyamoya disease. *Cerebrovasc Dis* 2009;28:247–257.
- 32 Komoribayashi N, Ogasawara K, Kobayashi M, Saitoh H, Terasaki K, Inoue T, Ogawa A: Cerebral hyperperfusion after carotid endarterectomy is associated with preoperative hemodynamic impairment and intraoperative cerebral ischemia. *J Cereb Blood Flow Metab* 2005;26:878–884.
- 33 Oka K, Yamashita M, Sadoshima S, Tanaka K: Cerebral haemorrhage in Moyamoya disease at autopsy. *Virchows Arch A Pathol Anat Histol* 1981;392:247–261.
- 34 Takagi Y, Kikuta K, Nozaki K, Hashimoto N: Histological features of middle cerebral arteries from patients treated for Moyamoya disease. *Neurol Med Chir (Tokyo)* 2007;47:1–4.
- 35 Chan PH: Role of oxidants in ischemic brain injury. *Stroke* 1996;27:1124–1129.
- 36 Kang HS, Kim JH, Phi JH, Kim YY, Wang KC, Cho BK, Kim SK: Plasma matrix metalloproteinases, cytokines and angiogenic factors in moyamoya disease. *J Neurol Neurosurg Psychiatry* 2010;81:673–678.
- 37 Sakamoto S, Kiura Y, Yamasaki F, Shibukawa M, Ohba S, Shrestha P, Sugiyama K, Kurisu K: Expression of vascular endothelial growth factor in dura matter of patients with moyamoya disease. *Neurosurg Rev* 2008;31:77–81.
- 38 Fujimura M, Watanabe M, Narisawa A, Shimizu H, Tomimaga T: Increased expression of serum matrix metalloproteinase-9 in patients with moyamoya disease. *Surg Neurol* 2009;72:476–480.
- 39 Mikami C, Suzuki M, Tsuike K, Ogawa A: Effect of nicardipine and magnesium on cerebral infarction-brain surface perfusion technique. *Cerebrovasc Dis* 2001;11:44–50.
- 40 Amenta F, Tomassoni D: Treatment with nicardipine protects brain in an animal model of hypertension-induced damage. *Clin Exp Hypertens* 2004;26:351–361.
- 41 Kawamata T, Kawashima A, Yamaguchi K, Hori T, Okada Y: Usefulness of intraoperative laser Doppler flowmetry and thermography to predict a risk of postoperative hyperperfusion after STA-MCA bypass for moyamoya disease. *Neurosurg Rev* 2011;34:355–362.

Copyright: S. Karger AG, Basel 2012. Reproduced with the permission of S. Karger AG, Basel. Further reproduction or distribution (electronic or otherwise) is prohibited without permission from the copyright holder.