

Vasculopathy after intracystic bleomycin administration for a recurrent cystic craniopharyngioma

Case report

WON-SANG CHO, M.D.,¹ SEUNG-KI KIM, M.D., PH.D.,² KYU-CHANG WANG, M.D., PH.D.,² JI HOON PHIL, M.D.,² AND BYUNG-KYU CHO, M.D., PH.D.³

¹Department of Neurosurgery, Kangwon National University Hospital, School of Medicine, Kangwon National University, Chuncheon, Gangwon-do; ²Division of Pediatric Neurosurgery, Seoul National University Children's Hospital, Seoul National University College of Medicine, Seoul; and ³Department of Neurosurgery, The Armed Forces Capital Hospital, Bundang-gu Seongnam-si, Gyeonggi-do, Korea

Intracystic bleomycin (ICB) administration is known to be effective in the treatment of cystic craniopharyngiomas (CRPs) and rarely causes serious complications. The authors report a case of vasculopathy after ICB injection for a recurrent cystic CRP. A 5-year-old boy presented with the cystic recurrence of a CRP. A catheter and Ommaya system were inserted into the cyst, followed by a leakage test 2 weeks later. Bleomycin was delivered at 3 mg per week for 14 weeks (total dose 42 mg). Four months later, the patient's activity decreased and right hemiparesis occurred. Magnetic resonance imaging and cerebral angiography demonstrated a recurrent multicystic mass and infarction at the left middle cerebral artery territory with stenosis/occlusion of the left distal internal carotid artery and posterior cerebral artery. During the operation to remove the recurrent cystic mass, fibrotic stenooocclusion of the left intracranial arteries was identified. The cyst was totally removed. However, additional multiple border zone infarctions occurred in the left hemisphere, and the patient became wheelchair bound. Leakage of ICB was considered as the most probable cause of the cerebral vasculopathy and corresponding infarction. A leakage test may not always guarantee a leakage-free status even if the test is negative. Direct bypass surgery should have been considered to prevent a high risk of postoperative infarction in this case of a recurrent CRP with confirmed vasculopathy. (<http://thejns.org/doi/abs/10.3171/2012.1.PEDS11437>)

KEY WORDS • bleomycin • craniopharyngioma • intracystic injection • vasculopathy • oncology

CRANIOPHARYNGIOMA is a histologically benign tumor, presumably derived from Rathke cleft epithelium.²⁷ Age distribution is bimodal with a peak in childhood and a second peak in adulthood,⁸ and about 90% of CRPs have a cystic portion.^{1,19} Gross-total resection, or subtotal resection and adjuvant radiation therapy are considered as the treatment of choice, with a success rate of 50% to 80%.^{8,16,23} However, standard treatment strategies are not always effective or applicable. Even after GTR is performed, the recurrence rate is reported to be about 10% to 30%.^{8,16,27} Early postoperative complications can be serious, such as hypothalamic injury, hormonal insufficiency, and optic nerve injury.⁸ When subtotal resection and adjuvant radiation therapy are performed, the complication rate is lower than after GTR,

and long-term outcomes are comparable to those following GTR. However, delayed complications after radiation therapy can be significant, including cognitive dysfunction, visual loss, hormonal insufficiency, vasculopathy, and secondary neoplasm.^{8,23} These complications can cause disastrous effects, especially in children with developing brain. Thus, alternative approaches have been considered in a specific subgroup of tumors.

Alternative treatment modalities include ICB, interferon, and radionuclides injection.²³ Among these, ICB administration has been used for primary or recurrent cystic tumors since Takahashi et al.²⁴ successfully treated cystic CRPs in 1985. Although the relevant literature to date is limited,^{1–7,9–12,14,16,18–20,22,28} the results of ICB administration are satisfactory. However, some complications have been reported, mainly associated with hypothalamic injury.^{2,3,6,7,9,10,12,16,18–20,22,28} We here present a case with

Abbreviations used in this paper: ACA = anterior cerebral artery; CRP = craniopharyngioma; GTR = gross-total resection; ICA = internal carotid artery; ICB = intracystic bleomycin; MCA = middle cerebral artery; PCA = posterior cerebral artery; SCA = superior cerebellar artery.

This article contains some figures that are displayed in color online but in black-and-white in the print edition.

Vasculopathy after intracystic bleomycin for recurrent cystic CRP

complications consisting of occlusion of major intracranial vessels and infarction at the corresponding territory after ICB administration as well as a review of the literature.

Case Report

History and Examination. A 28-month-old boy presented with gait disturbance and frequent vomiting. Left visual acuity had decreased, and papilledema was identified on ophthalmoscopic examination. Brain MRI and CT revealed a $3.5 \times 2.5 \times 6$ -cm mixed type of intra-/suprasellar retrochiasmatic mass with partial calcification and hydrocephalus (Fig. 1).

First Operation and Postoperative Course. Gross-total resection of the tumor was achieved via a subfrontal and interhemispheric approach.

On pathological examination, the lesion was diagnosed as an adamantinomatous type of CRP. Left visual acuity did not recover, and panhypopituitarism occurred. On follow-up MR imaging, a small enhancing nodule was identified at the left supraoptic area 1 year after the first operation, and it progressively grew to a cystic mass at 3 years after the first operation. The child had a Lansky Play Performance Status¹³ (children's Karnofsky Performance Scale) of 90 (Fig. 2A).

Intracystic Bleomycin Administration and Follow-Up. The patient was referred to another institution for ICB treatment. We thought of ICB treatment as effective and minimally invasive because the patient had no related symptoms except for a recurrent cyst on imaging studies. A catheter was inserted into the largest cyst under stereotactic guidance and was connected to an Ommaya reservoir. Catheter placement was confirmed immediately, and a leakage test was performed 2 weeks later. After cystic fluid was withdrawn, ICB was administered at 3 mg per week for 14 weeks (total dose 42 mg). During ICB delivery, there were no problems. Four months later, however, physical activity began to decrease and right hemiparesis occurred. Cerebral MR imaging demonstrated an enlarged tumor cyst and infarction at the territory of the left MCA (Fig. 2B and C). On cerebral angiography, the left proximal ACA and MCA could not be identified, although stenosis of the left PCA was demonstrated (Fig. 3 left).

Second Operation and Postoperative Course. Decompressive radical resection was performed via a left frontotemporal craniotomy. A large subdural calcified mass covered the exposed frontal lobe, which was CRP that had metastasized via the previous catheter route. It was too tightly adhered to the adjacent cortical surface to be dissected without cortical damage. Transcortical removal of the huge cystic tumor revealed whitish fibrotic and cord-like left proximal segments of the ACA and MCA. They were very thin in diameter with uncertain blood flow (Fig. 3 right). There was no significant peritumoral scar interfering with dissection of the tumor. Although the cyst wall was totally removed without discernible major arterial injury, multiple border zone infarctions oc-

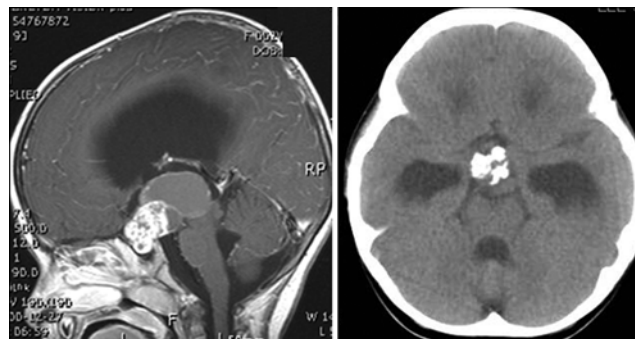


FIG. 1. Initial preoperative brain images showing an intra-/suprasellar retrochiasmatic mass of mixed type on a sagittal Gd-enhanced T1-weighted MR image (left), with calcifications on a CT scan (right).

curred postoperatively in the left hemisphere. Thereafter, a ventriculoperitoneal shunt operation was performed twice within a year. The patient was able to communicate but became dependent because of left blindness, panhypopituitarism, and right spastic hemiparesis.

Discussion

Bleomycin is an antineoplastic drug originally produced from the fungus *Streptomyces verticillus* in 1966.²⁶ It is systemically used for the treatment of lymphoma, testicular cancer, and squamous cell carcinoma. Fibrosis of the skin and lung is known as the major complication. However, this characteristic of bleomycin is used in the treatment of cystic tumor to scar and thicken the cyst wall. Some kinds of brain tumors, such as cystic CRPs and gliomas, have been indications for bleomycin therapy since 1973.¹⁷ Bleomycin is delivered directly into the brain tumor to overcome the blood-brain barrier, to escape the systemic complication, and to infuse a relatively high dose.¹⁵ In CRPs, ICB infusion is performed via an intracystic catheter. It is known to be very effective given that almost all cases have shown satisfactory results and a low complication rate.²³ Most of the complications have been minor symptoms such as transient fever, headache, nausea, vomiting, and fatigue. There have rarely been moderate to severe complications such as peritumoral edema, seizure, and hypothalamic injury.¹⁵ Among those cases with such complications, there have been 3 cases associated with intracranial vascular injury to date. One case had an infarction of the MCA territory 3 months after ICB injection,³ and another had a territorial infarction of the SCA 2 months after ICB injection.¹⁹ The third case involved angiographic confirmation of a vessel injury.²⁰ Internal carotid artery occlusion and PCA stenosis were incidentally found 19 years after ICB and ¹⁹⁸Au colloid injection in that case; however, radiation by ¹⁹⁸Au was considered the major factor in delayed vasculopathy. The present case is thought to be a bleomycin-induced fibrotic vasculopathy. It is unique in that vasculopathy was confirmed on operation as well as on cerebral angiography.

Bleomycin-related toxicity is thought to result from leakage or diffusion. Most complications are considered to occur as a result of diffusion because a leakage test is performed before ICB injection and peritumoral edema is

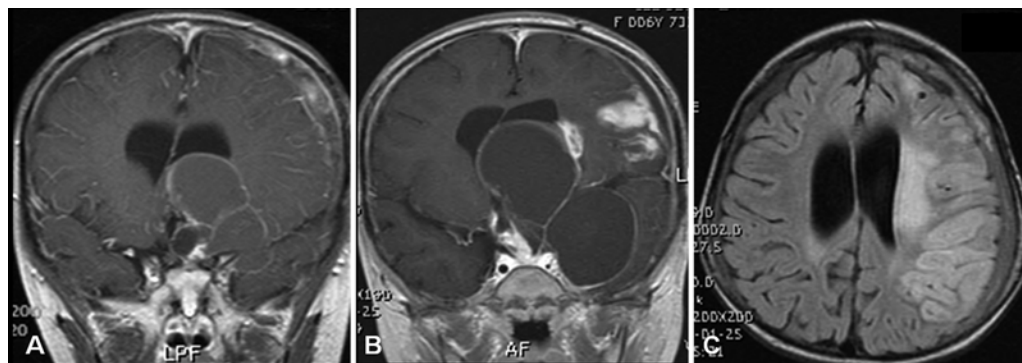


Fig. 2. Coronal Gd-enhanced T1-weighted MR image (A) obtained 3 years after the first operation, demonstrating a recurrent cystic mass. Coronal Gd-enhanced T1-weighted MR image (B) obtained 4 months after ICB injection, showing an enlarged cystic mass. A FLAIR image (C) demonstrating an infarction at the territory of the left MCA.

identified on brain imaging, which corresponds well with the clinical presentation. Nakazawa et al.¹⁷ demonstrated that bleomycin had a penetration capacity 2–3 cm into the brain. Moreover, leakage was a cause of complications in only 2 reports.^{3,28} A leakage test was not mentioned in Broggi et al.'s report,³ and Zanon²⁸ performed a leakage test. According to a report dealing with cases between 1990 and 2000,²⁹ the rate of catheter misplacement and contrast leakage from the cyst was as high as 16.3%, regardless of surgical modality. In our opinion, the leakage test cannot guarantee the real leakage-free status because the test is only an indirect gross visual radiological imaging study with a contrast agent and because physical properties, such as osmolality and viscosity, of bleomycin and contrast medium are different (contrast medium > bleomycin). Although the leakage of bleomycin appears to occur rarely after a leakage test, one should always be cautious because of the potentially disastrous situation. In the present case, leakage was thought to be the more plausible cause of vasculopathy rather than diffusion, even if the leakage test was negative. If vasculopathy results from diffusion of the bleomycin, it is hard to explain why parenchymal edema was not accompanied by a drug dose large enough to cause vascular injury. The recurrent leakage of a small amount of bleomycin and subsequent injury to the intracranial arteries might cause progression of the vasculopathy.

To reduce the chance of leakage, several recommendations have been made: a leakage test before injection, a lower single dose < 5 mg, a small total cumulative dose, and a longer interval between injection, that is, at least 1 injection every other day.^{2,15} However, these recommendations do not seem absolute. In reviewing the protocols of other studies (Table 1), we noted no significant differences in the single dose and total dose or in the interval of the ICB injection between cases with complications and other cases. The present case involved a leakage test, low-dose ICB injection (3 mg), small total dose (42 mg), and long interval (1 week), as compared with previous protocols. Therefore, empirical protocols of low single and total doses and long intervals may not guarantee the bleomycin leakage-free status. In a report, Lafay-Cousin and colleagues¹² emphasized close clinical observation prior to each bleomycin injection because initial signs of leak-

age are subtle and progressive. In addition, repeated leakage testing in between may be helpful when long-term ICB injection is planned.

A literature review of ICB administration for CPRs is summarized in Table 1.^{1,7–9–12,14,16,18–25,28} The number of patients treated with ICB injection is 162, and the number of complications is 27 (not counting the present case). In estimating a moderate-to-severe complication rate of ICB injection with case series of 2 or more patients,^{3,4,6,9–12,14,16,18,19,24,25,28} we found a rate of about 14.8% (23 of 155 patients). This rate is higher than the approximately 6% rate in a review article.¹⁵ Clinical manifestations included hypothalamic injury (somnolence, personality change, memory impairment, and thermal dysregulation), brain infarction (territories of MCA/SCA and thalamus), optic neuritis, visual disturbance, hypacusis, hemiparesis, mental change, seizure, panhypopituitarism, bedridden status, and death. Minor complications, such as transient headache, nausea, vomiting, and an increase in body temperature, occurred in most cases. Additionally, 2 cases with asymptomatic complications were reported: asymptomatic parenchymal edema during treatment,¹² and stenocclusion of the ICA and PCA 19 years after ICB and ¹⁹⁸Au colloid injection.²⁰ In most cases, clinical manifestation of a complication occurred within 2–3 months after ICB administration but ranged from after 1 cycle of ICB injection to 2 years after treatment. The management of

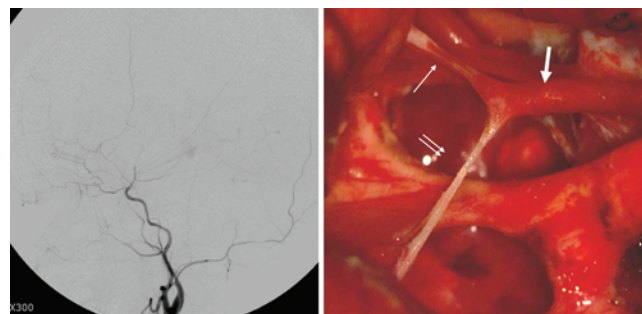


Fig. 3. Left: Cerebral angiogram showing occlusion of the left proximal ACA and MCA. Right: Intraoperative photograph demonstrating mild stenosis of the left distal ICA (thick arrow) and fibrotic stricture of the ACA and MCA (double and single thin arrows, respectively). Blood flow through the severely narrowed arteries was uncertain.

TABLE 1: Review of the literature on ICB administration for cystic CRPs*

Authors & Year	No. of Cxs/ Total No. of Patients	Occurrence of Cx (no. of patients)	Cx	Imaging (no. of patients)	Total ICB Dose in mg (individual dose)†	Cause of Cxs	Outcome of Tumor Cyst (no. of patients)	FU Period (yrs)	Tx‡
Takahashi et al., 1985	0/7	—	—	—	13–95 (1–5 qod)	—	CR (4), NA (3)	0.1–7	op + ICB
Haisa et al., 1994	1/1	on 13th ICB cycle	hypothalamic injury, personality change, memory impairment	none	27.5 (0.5–5 q 1–2 wks)	diffusion	CR	0.8	ICB
Cavalheiro et al., 1996	0/1	—	—	none	80 (10 qd)	—	CR	1	ICB
Broggi et al., 1995	2/14	3 mos (1) & few ds after Tx (1)	MCA infarct (1), bilat hypacusis (1)	MCA infarction (1), NA (1)	3–42 (1.5–5 qod)	leakage	CR (7), R (7)	0.2–7	ICB/op
Sagoh et al., 1997	1/1	soon after Tx	hemianopia, hemiparesis	ICA occlusion	5	diffusion + radiation	R	19	op + ICB + ICB ¹⁸⁵ Au/op
Zanon, 1998	2/21	NA (1), on 2nd ICB cycle (1)	transient optic neuritis (1), seizure (1)	NA (2)	15–100 (2–10 qd)	leakage	CR (3), PR (9), NA (9)	0.3–6	ICB/op or RT
Savas et al., 1999	0/1	—	—	—	140, 80§	—	CR	2	ICB/ICB
Savas et al., 2000	1/1	5 ds after Tx	hypothalamic injury, mental change, hypothyroidism	edema	56 (7 qd)	diffusion	R	0.1	ICB
Hader et al., 2000	1/7	soon after Tx	panhypopituitarism	edema	18–115 (2–5 qod)	diffusion	CR (1), PR (5), MR (1)	0.5–5	ICB/op
Mottolese et al., 2001	3/24	NA (1), few wks after Tx (2)	blindness (1), transient IICP sign (2)	NA (1), edema (2)	30–150 (3–5 qod)	diffusion	CR (9), R (15)	2–10	ICB ± op
Park et al., 2002	5/10	2 mos after Tx (1), on 1 cycle (1), NA (3)	unilat SCA territory infarct (1), bedridden (1), visual disturbance (1), hypothalamic injury/memory impairment (1), mental change (1)	SCA infarction, NA (4)	15–180 (2–5 q 2–7 ds)	diffusion	R or S (10)	1–2.4	ICB ± op
Alén et al., 2002	0/1	—	—	—	45, 30§	—	CR	1.5	op + RT/op/op/ICB/ICB
Jiang et al., 2002	3/14	1 mo (1) & 3 mos (1) after Tx, NA (1)	hemiparesis/seizure (1), hyponatremia/obesity/thalamic infarct (2)	NA (3)	60, 62.5, 100¶ (5–15 qd)	diffusion	CR (7), PR (6), S (1)	0.6–2	ICB or ICB + ICB ³² P
Nicolato et al., 2004	0/8	—	—	—	3–35 (1.5–3 q wk)	—	CR (3), PR (3), MR (2)	2.6–4.4	ICB + RS
Takahashi et al., 2005	0/11	—	—	—	30–40 (1–5 qod)	—	CR (4), PR (7)	3–16	op ± RS/ICB
Cáceres, 2005	0/2	—	—	—	40 (5 qod), 60 (10 qd)	—	CR (2)	8–10	op/ICB/RT/ICB
Lena et al., 2005	0/5	—	—	—	70 (10 qd)	—	CR (3), R (2)	7–14	ICB
Kim et al., 2007	0/7	—	—	—	15–180 (2–5 q 2–7 ds)	—	CR (2), PR (5)	0.8–6.6	ICB ± op

(continued)

TABLE 1: Review of the literature on ICB administration for cystic CRPs* (continued)

Authors & Year	No. of Cxs/ Total No. of Patients	Occurrence of Cx (no. of patients)	Cx	Imaging (no. of patients)	Total ICB Dose in mg (individual dose)†	Cause of Cxs	Outcome of Tumor Cyst (no. of patients)	FU Period (yrs)	Tx‡
Hukin et al., 2007	4/17	NA (2), 5 mos (1) & 2 yrs (1) after Tx	mental change/panhypopituitarism (1), multiple CN palsies/hemiparesis (1), precocious puberty (1), panhypopituitarism (1)	edema (2), none (2)	15–75	diffusion	CR (5), PR (6), MR (5), S (1)	0.5–10.2	ICB ± op, RT
Belen et al., 2007	1/1	6 wks after Tx	seizure, blindness	edema	75 (5 qod)	diffusion	R	0.5	op + RS/ICB
Lafay-Cousin et al., 2007	3/8	after 12 cycles (2), after 15 cycles (1)	CN III/VII palsies/hemiparesis (1), memory disturbance/hypothalamic injury/DI (1), asymptomatic edema (1)	edema (3)	45 (3 qod)	diffusion	R (3), NA (5)	0.2–1	ICB or ICB/op
present case	1/1	4 mos after Tx	hemiparesis	ACA/MCA occlusion	42 (3 qd)	leakage	NR	2	op/ICB/op

* CN = cranial nerve; CR = complete reduction (≥ 90% size reduction); Cx = complication; d = day; DI = diabetes insipidus; FU = follow-up; IC³²P = intracystic ³²P; IC¹⁹⁸Au = intracystic ¹⁹⁸Au injection; iICP = increased intracranial pressure; MR = minimal reduction (≤ 49% size reduction); NA = not available; NR = no response; op = operation; PR = partial reduction (size reduction between 50% and 89%); q = every; qd = every day; qod = every other day; R = reduction (no mention of size); RS = radiosurgery; S = stable; Tx = treatment; — = not applicable; ± = with or without.

† In all patients in the cited study.

‡ The + indicates a procedure performed simultaneously. The procedure after a forward slash (/) was performed at a later date.

§ Values listed indicate dose for each ICB procedure.

¶ Total dose classified into 3 different values.

complications has rarely been mentioned in the previous reports. Mostly, steroid infusion was used to resolve the parenchymal edema and neuropathy, with additional conservative treatments.

Intracystic bleomycin administration has been effective. According to the authors of one study,⁹ 94% of the patients achieved at least 25% shrinkage in the cyst size, and 29% of them showed a complete response. In Table 1, except in 17 patients with no mention of their results, 100% of the patients showed at least a stable cyst status, and 91.7% of the cysts were reduced in size. Moreover, 37.2% achieved a complete response. Meanwhile, the durability of ICB treatment still seems inconclusive. In one report,⁹ ICB injection was effective in 94% of the patients, and 53% of them maintained treatment efficacy for a median of 34 months. The other patients had a response lasting less than 1 year. Nonetheless, ICB injection would be advantageous in children with developing brain, in terms of delaying radiation therapy.^{6,9,23}

Retrospectively, several points are learned from the present case. First, close imaging follow-up and timely resection of cystic CRPs, even if the lesion is a recurrence, are important. The CRPs in the present case might have been cured if the recurrent small cystic mass had been removed before it became a larger, multiseptated cystic tumor. The recurrent cyst was initially small and resided in the left frontal lobe for 3 years. However, it rapidly progressed to a multicystic mass with extension to the hypothalamus and temporal lobe across the left sylvian fissure. Second, fenestration of the septae, making the lesion a single large cyst, and catheter insertion under direct approach to the cyst might have been more effective for ICB injection than catheter insertion under stereotactic guidance. Third, direct bypass surgery should have been considered in general. Stenoocclusion of the intracranial major vessels and their territorial infarctions were preoperatively identified. The risk of perioperative infarction already existed. However, direct bypass surgery seemed difficult to perform in this particular case because a bilateral subdural hematoma and ipsilateral subdural calcified metastatic CRP covered the cortex. In addition, the boy was very young with donor and recipient vessels too small for bypass surgery.

Conclusions

In summary, ICB administration is one of the effective alternative treatment modalities for cystic CRPs. However, complications via diffusion or leakage of bleomycin can be problematic. A leakage test with a contrast agent does not always guarantee a leakage-free status. Thus, every effort should be made to avoid complications. Preoperative risk evaluation is mandatory in cases of recurrent CRP with confirmed vasculopathy. Direct arterial bypass surgery, such as direct anastomosis between the superficial temporal artery and the cortical branch of the MCA, should be considered to combat postoperative infarction.

Disclosure

The authors report no conflict of interest concerning the mate-

Vasculopathy after intracystic bleomycin for recurrent cystic CRP

rials or methods used in this study or the findings specified in this paper.

Author contributions to the study and manuscript preparation include the following. Conception and design: BK Cho, WS Cho. Acquisition of data: all authors. Analysis and interpretation of data: BK Cho, WS Cho. Drafting the article: BK Cho, WS Cho. Critically revising the article: all authors. Reviewed submitted version of manuscript: all authors. Approved the final version of the manuscript on behalf of all authors: BK Cho. Study supervision: BK Cho, Kim, Wang, Phi.

References

- Alén JF, Boto GR, Lagares A, de la Lama A, Gómez PA, Lobato RD: Intratumoral bleomycin as a treatment for recurrent cystic craniopharyngioma. Case report and review of the literature. **Neurocirugia (Astur)** 13:479–485, 2002
- Belen D, Er U, Yigitkanli K, Bolay H: Delayed neurotoxic complication of intracavitary bleomycin therapy for craniopharyngioma in a child who had previously undergone radiosurgery. Case report. **J Neurosurg** 106 (5 Suppl):391–393, 2007
- Broggi G, Giorgi C, Franzini A, Leocata F, Riva D: Therapeutic role of intracavitary bleomycin administration in cystic craniopharyngioma, in Broggi G (ed): **Craniopharyngioma: Surgical Treatment**. Milan: Springer-Verlag, 1995, pp 113–119
- Cáceres A: Intracavitary therapeutic options in the management of cystic craniopharyngioma. **Childs Nerv Syst** 21:705–718, 2005
- Cavalheiro S, Sparapani FV, Franco JO, da Silva MC, Braga FM: Use of bleomycin in intratumoral chemotherapy for cystic craniopharyngioma. Case report. **J Neurosurg** 84:124–126, 1996
- Hader WJ, Steinbok P, Hukin J, Fryer C: Intratumoral therapy with bleomycin for cystic craniopharyngiomas in children. **Pediatr Neurosurg** 33:211–218, 2000
- Haisa T, Ueki K, Yoshida S: Toxic effects of bleomycin on the hypothalamus following its administration into a cystic craniopharyngioma. **Br J Neurosurg** 8:747–750, 1994
- Honegger J, Tatagiba M: Craniopharyngioma surgery. **Pituitary** 11:361–373, 2008
- Hukin J, Steinbok P, Lafay-Cousin L, Henderson G, Strother D, Mercier C, et al: Intracystic bleomycin therapy for craniopharyngioma in children: the Canadian experience. **Cancer** 109: 2124–2131, 2007
- Jiang R, Liu Z, Zhu C: Preliminary exploration of the clinical effect of bleomycin on craniopharyngiomas. **Stereotact Funct Neurosurg** 78:84–94, 2002
- Kim SD, Park JY, Park J, Lee JB, Kim SH, Lim DJ: Radiological findings following postsurgical intratumoral bleomycin injection for cystic craniopharyngioma. **Clin Neurol Neurosurg** 109:236–241, 2007
- Lafay-Cousin L, Bartels U, Raybaud C, Kulkarni AV, Guger S, Huang A, et al: Neuroradiological findings of bleomycin leakage in cystic craniopharyngioma. Report of three cases. **J Neurosurg** 107 (4 Suppl):318–323, 2007
- Lansky LL, List MA, Lansky SB, Cohen ME, Sinks LF: Toward the development of a play performance scale for children (PPSC). **Cancer** 56:1837–1840, 1985
- Lena G, Paz Paredes A, Scavarda D, Giusiano B: Craniopharyngioma in children: Marseille experience. **Childs Nerv Syst** 21:778–784, 2005
- Linnert M, Gehl J: Bleomycin treatment of brain tumors: an evaluation. **Anticancer Drugs** 20:157–164, 2009
- Mottolese C, Stan H, Hermier M, Berlier P, Convert J, Frappaz D, et al: Intracystic chemotherapy with bleomycin in the treatment of craniopharyngiomas. **Childs Nerv Syst** 17:724–730, 2001
- Nakazawa S, Ohwaki K, Shimura T, Itoh Y, Yajima K: [A new treatment of malignant brain tumor-I: local injection of bleomycin (author's transl).] **No Shinkei Geka** 9:1487–1493, 1981 (Jpn)
- Nicolato A, Foroni R, Rosta L, Gerosa M, Bricolo A: Multimodality stereotactic approach to the treatment of cystic craniopharyngiomas. **Minim Invasive Neurosurg** 47:32–40, 2004
- Park DH, Park JY, Kim JH, Chung YG, Lee HK, Lee KC, et al: Outcome of postoperative intratumoral bleomycin injection for cystic craniopharyngioma. **J Korean Med Sci** 17: 254–259, 2002
- Sagoh M, Murakami H, Hirose Y, Mayanagi K: Occlusive cerebrovasculopathy after internal radiation and bleomycin therapy for craniopharyngioma—case report. **Neurol Med Chir (Tokyo)** 37:920–923, 1997
- Savas A, Arasil E, Batay F, Selcuki M, Kanpolat Y: Intracavitary chemotherapy of polycystic craniopharyngioma with bleomycin. **Acta Neurochir (Wien)** 141:547–549, 1999
- Savas A, Erdem A, Tun K, Kanpolat Y: Fatal toxic effect of bleomycin on brain tissue after intracystic chemotherapy for a craniopharyngioma: case report. **Neurosurgery** 46:213–217, 2000
- Steinbok P, Hukin J: Intracystic treatments for craniopharyngioma. **Neurosurg Focus** 28(4):E13, 2010
- Takahashi H, Nakazawa S, Shimura T: Evaluation of postoperative intratumoral injection of bleomycin for craniopharyngioma in children. **J Neurosurg** 62:120–127, 1985
- Takahashi H, Yamaguchi F, Teramoto A: Long-term outcome and reconsideration of intracystic chemotherapy with bleomycin for craniopharyngioma in children. **Childs Nerv Syst** 21:701–704, 2005
- Umezawa H, Maeda K, Takeuchi T, Okami Y: New antibiotics, bleomycin A and B. **J Antibiot (Tokyo)** 19:200–209, 1966
- Wang KC, Hong SH, Kim SK, Cho BK: Origin of craniopharyngiomas: implication on the growth pattern. **Childs Nerv Syst** 21:628–634, 2005
- Zanon N: Craniopharyngiomas: intratumoral chemotherapy with bleomycin in children and adolescents [abstract]. Thesis, São Paulo 1997. **Arq Neuropsiquiatr** 56:859–864, 1998
- Zanon N, Cavalheiro S, da Silva MC: Does the choice of surgical approach to insert an intratumoral catheter influence the results of intratumoral cystic treatment? **Surg Neurol** 70:66–69, 2008

Manuscript submitted October 9, 2011.

Accepted January 6, 2012.

Please include this information when citing this paper: DOI: 10.3171/2012.1.PEDS11437.

Address correspondence to: Byung-Kyu Cho, M.D., Ph.D., Department of Neurosurgery, The Armed Forces Capital Hospital, Yul-dong 2-gil 66-ho, P.O. Box #99, Bundang-gu Seongnam-si Gyeonggi-do, 463-040, Republic of Korea. email: bkcho@snu.ac.kr.