

compared with the first, whereas the prolactin response was unaltered. We now report the endocrine effects of repeated intravenous infusions of RX77368 in MND.

Seven patients (six male, one female, age range 43–67) with MND³ were given six intravenous infusions of RX77368 on Mondays and Thursdays of three successive weeks, starting at 9.30 am on each occasion. The dose of RX77368 was 0.2 mg/kg, given over two hours. If side effects were unacceptable,^{2,4} the dose was reduced on subsequent infusions. Two patients failed to complete all the infusions, one having five, the other four. Of the other patients, three had dose reductions, to 0.15 or 0.1 mg/kg because of side effects. Blood samples were taken for measurement of T₄, T₃, TSH and prolactin

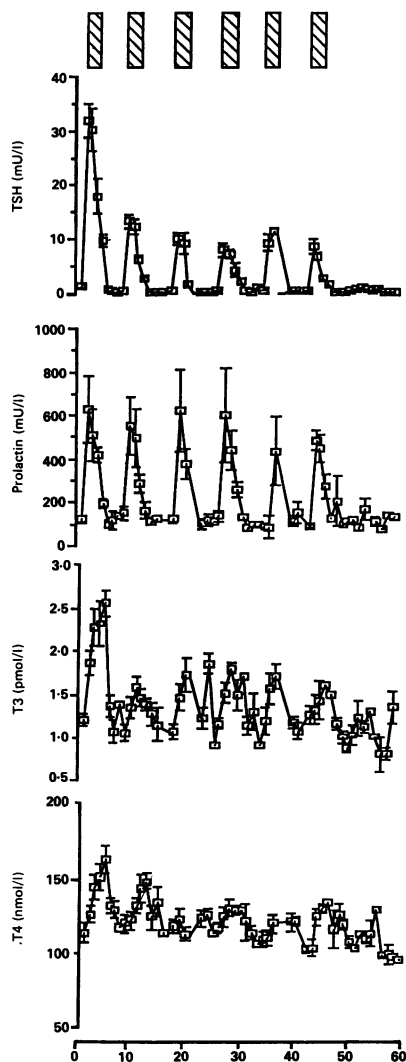


Figure Each point represents blood samples from up to seven patients. Samples were taken before each infusion, one hour through, immediately after, then four and six hours after each infusion. Further samples were then taken each day until the next infusion. There was a three to four day interval between infusions. Error bars represent standard error of the mean. Cross-hatched bars represent RX77368 infusions, 0.1–0.2 mg/kg over two hours. Base line TSH is suppressed between infusions compared with pre-treatment ($p < 0.05$), and peak TSH is greater after the first infusion than after subsequent infusions ($p < 0.05$). Peak values of T₃ and T₄ after the infusion follow the same pattern as TSH, being greatest after the first infusion ($p < 0.05$ in each case).

before, after one hour and at the end of the infusion, then at four and six hours after the infusion, and every morning at 9 am until the next infusion.

All hormones were measured as previously described,⁵ except that prolactin standards were obtained from the Division of Molecular Endocrinology, Hammersmith Hospital, London. The detection limit for prolactin was 40 mU/l. Results were analysed using analysis of variance with Duncan's test for multiple comparisons. Correlations between groups were described using Spearman's test. The study was approved by the local ethics committee.

Each time point has been ascribed a number in the order in which blood samples were taken, and is identified by this number in the graphs (fig). Samples were taken during and immediately after the infusions more rapidly than at other times, and thus the time scale of the points in the graph is not constant.

The first infusion caused a significantly greater TSH response than the subsequent infusions, each of which caused a response similar to each other. The basal trough levels of TSH between infusions were significantly lower than the TSH concentration before the first infusion, despite the fact that trough T₄ and T₃ concentrations were not significantly different from pre-treatment levels.

The marked prolactin response to each infusion was similar, and trough levels of prolactin were no different to pre-treatment levels.

The thyroid hormone responses to RX77368 reflect the TSH response. Trough levels of T₄ and T₃ between infusions were, however, not significantly different from pre-treatment levels.

Peak T₄ and T₃ responses correlate with peak TSH response ($p < 0.005$ and < 0.01 respectively)

There is continuing interest in the possible therapeutic use of TRH analogues in MND.^{2,6} If long term studies are planned, it is important to know the long term endocrine effects, and particularly whether thyrotoxicosis might occur.

A single infusion of RX77368 produces endocrine effects that are not dissimilar to those of native TRH.³ However, the biological effects of the analogue were not the same as TRH, in that the TSH released seemed to be of lesser biological potency.⁵ This study demonstrated again the reduction in TSH response to a second infusion,⁵ but there was no further decline in TSH response after repeated administration. The dose of RX77368 is far in excess of the maximally effective dose of RX77368 for hormonal release, so that the response seen still represents the maximum endocrine response to the analogue.³

It is notable that thyroid hormone concentrations return to an unaltered baseline before the next infusion of RX77368. Despite the normal T₄ and T₃, the subsequent infusions all produced lesser TSH responses than the first infusion. In addition, there was a permanent suppression of plasma TSH between infusions, suggesting a reduction in the tonic stimulatory effect of endogenous TRH on the thyrotrophs. This reduction might be caused by reduced endogenous TRH release, modification of numbers of TRH receptors on the cell surface, modification of intracellular transduction systems, or a delayed effect of the transient increase of thyroid hormones on TSH gene transcription. The reduction of TSH response, does

not, however, influence the effect of RX77368 on the release of prolactin, further evidence that the TRH stimulated post receptor events in lactotrophs and thyrotrophs are differentially regulated.

If RX77368 was administered on the present dose schedule over extended periods of time, thyrotoxicosis should not be a significant side effect. The baseline thyroid function would not alter, though there would be periods during and immediately after infusions when the peripheral thyroid hormones would be significantly elevated. The possibility thus exists of using RX77368 in such a way as to avoid the hazard of thyrotoxicosis.

This work was supported by the Motor Neuron Disease Association of Great Britain and by the Special Trustees of Westminster and Roehampton Hospitals. RX77368 was kindly supplied by Reckitt and Colman Ltd, Pharmaceutical Division, Hull, United Kingdom. We thank the Department of Chemical Pathology, Westminster Hospital for the radioimmunoassays.

DAVID JA ECKLAND
H MODARRRES-SADEGHI*
STAFFORD L LIGHTMAN
ROBERTO J GUILOFF*

Departments of Neuroendocrinology and Neurology,*
Charing Cross and Westminster Medical School,
Westminster Hospital, London

- Engel WK, Siddique T, Nicoloff JT. Effects on weakness and spasticity in amyotrophic lateral sclerosis of thyrotropin releasing hormone. *Lancet* 1983;ii:73–5.
- Modarres-Sadeghi H, Rogers H, Emami J, Guiloff RJ. Subacute administration of a TRH analogue in motor neurone disease. An open study. *J Neurol Neurosurg Psychiatry* 1988;51:1146–57.
- Guiloff RJ, Eckland DJA, Demaine C, Hoare RC, Macrae KD, Lightman SL. Controlled acute trial of a thyrotrophin releasing hormone analogue (RX77368) in motor neurone disease. *J Neurol Neurosurg Psychiatry* 1987;50:1359–70.
- Modarres-Sadeghi H, Guiloff RJ. Comparative safety and efficacy of intravenous and oral administration of a TRH analogue (RX77368) in motor neurone disease. (In press).
- Eckland DJA, Lightman SL. The TSH, T₄, T₃ and prolactin responses to consecutive infusions of a potent and stabilized thyrotrophin releasing hormone analogue, RX77368, in man. *Eur J Clin Invest* 1988;18:405–9.
- Guiloff RJ. Use of TRH analogues in motor neurone disease. In: Metcalfe G, Jackson I, eds. Thyrotrophin releasing hormone—biomedical significance. *Ann NY Acad Sci* 1989;553:399–421.

Carotid dissection: a new false localising sign

Spontaneous internal carotid artery dissection typically presents with ipsilateral head and neck pain, oculosympathetic paresis, transient ischaemic attacks and stroke.¹ Lower cranial nerve palsies are uncommon.² We describe a carotid dissection with tenth and twelfth cranial nerve involvement and hemiplegia which clinically mimicked medullary infarction.

A hypertensive 41 year old man developed right frontal and orbital pain. There was no history of trauma but there was a history of alcohol abuse. Three days later on awakening, the patient was unable to swallow. He also noticed weakness, numbness, and clumsiness of the left hand and leg. On physical examination his blood pressure was 140/90. There were no head, neck or orbital bruits. Mental status examination was normal. There was

dysarthria but no dysphasia. Vision and extraocular movements were normal. The corneal reflex was diminished on the left. There was mild weakness of the left lower facial muscles. Taste was preserved. The uvula deviated to the left and the gag reflex was diminished on the right. The tongue had no wasting but deviated to the right upon protrusion. There was no evidence of Horner's syndrome. There was pronator drift of the left upper extremity and mild weakness of the left leg. A left hemisensory deficit for pinprick, touch and proprioception involved the face, arm, leg and trunk. Muscle stretch reflexes were more active on the left and plantar responses were flexor. There was no ataxia.

Initial CT scan of the head was normal. At this point the diagnosis of medullary infarction on the right was considered but the left lower facial weakness and absent left corneal reflex could not be explained. A repeat CT scan of the head four days later revealed a right parietal infarction. Duplex ultrasound of the carotids revealed an occlusion of the distal right internal carotid artery. Magnetic resonance imaging ten days after presentation demonstrated dramatic enlargement of the diameter of the right internal carotid artery, beginning several centimeters above the bifurcation and extending to the base of the skull (fig). The signal was compatible with intramural haemorrhage. There was no flow void signal. Tapering occlusion of the right internal carotid artery was demonstrated by angiography. Heparin was started and then changed to warfarin. One year later the patient has improved ability to swallow but is otherwise unchanged. Repeat duplex ultrasound has shown no evidence of recanalisation.

Hypoglossal palsy in association with internal carotid artery dissection has been reported infrequently, occurring in 5% of cases.² The occurrence of both tenth and twelfth nerve palsies in this situation is rare.² Hypoglossal paralysis with contralateral motor and sensory symptoms simulating a crossed hemiplegia has been reported only once.³ That patient experienced two transient ischaemic attacks in association with a persistent hypoglossal paralysis. Our patient is unique in that the lower cranial nerve palsies began simultaneously with the contralateral motor and sensory signs and the deficits persisted. The presentation mimicked that of medullary infarction. The clues of mild left facial weakness and a diminished left corneal

reflex cautioned against this localisation.

MRI showed the enlarged internal carotid artery with intramural haemorrhage and loss of the flow void signal indicating occlusion. Angiography confirmed the presence of a tapering occlusion of the internal carotid artery. The close proximity of the pharyngeal branches of the vagus, glossopharyngeal and hypoglossal nerve to the internal carotid artery in the neck makes them susceptible to compression from an expanding internal carotid artery.⁴ However, other factors such as ischaemia may be involved in the pathogenesis of cranial nerve palsies. MRI is superior to angiography in that the vessel wall is visualised and not just the lumen.⁵ Internal carotid artery dissection with ipsilateral lower cranial nerve palsies and contralateral hemiplegia should be added to the better known false localising signs.⁶

DAVID C HESS
KAPIL D SETHI
FENWICK T NICHOLS
Department of Neurology,
Medical College of Georgia,
Augusta, Georgia, United States

- 1 Mokri B, Sundt TM Jr, Houser OW, Piegras DG. Spontaneous dissection of the cervical internal carotid artery. *Ann Neurol* 1986; 19:126-38.
- 2 Hart RG, Easton JD. Dissections of cervical and cerebral arteries. *Neurologic Clinics* 1983; 11:155-82.
- 3 Goodman JM, Zink WL, Cooper DF. Hemiliparalysis caused by spontaneous carotid artery dissection. *Arch Neurol* 1983;40:653-4.
- 4 Lieschke GJ, Davis S, Tress BM, Ebeling P. Spontaneous internal carotid artery dissection presenting as hypoglossal nerve palsy. *Stroke* 1988;19:1151-5.
- 5 Goldberg HI, Grossman RI, Gomori JM, Asbury AK, Bilaniuk LT, Zimmerman RA. Cervical internal carotid artery dissecting hemorrhage: diagnosis using MR. *Radiology* 1986;158:157-61.
- 6 Rowland LP. Tumors. In: Rowland LP, ed. *Merritt's textbook of neurology*, 7th ed. Philadelphia, Lea and Febiger 1984:222.

Pure optic ataxia associated with a right parieto-occipital tumour

Optic ataxia is defined as a disorder of hand movement when grasping an object in the peripheral visual field.^{1,4} Twenty or more cases of optic ataxia have been reported since 1967 when Garcin *et al*¹ originally introduced the idea of optic ataxia. Rondot *et al*,² colleagues of Garcin, established that a disturbance of visuo-motor coordination is responsible for optic ataxia. They insisted that motor, cerebellar, and somatosensory disturbances, visuo-spatial agnosia, apraxia, and visual field defects should be excluded in diagnosing optic ataxia. However, we have found that, among reported cases, pure optic ataxia without these symptoms has been confirmed in only two cases.^{3,4} We report a case of optic ataxia in a pure form. Our case supports Rondot's concept that optic ataxia is a specific entity independent of other neurological disorders.

In November 1983 a 47 year old right handed man with no previous disease noticed difficulties in grasping objects, errors in estimating distances, and misty vision. On 23 January 1984, when these symptoms became slightly aggravated, the patient was admitted to our hospital. On admission, he was alert and well-orientated. His verbal functions and memory were normal. Visual acuity was normal in each eye. The visual field was full in

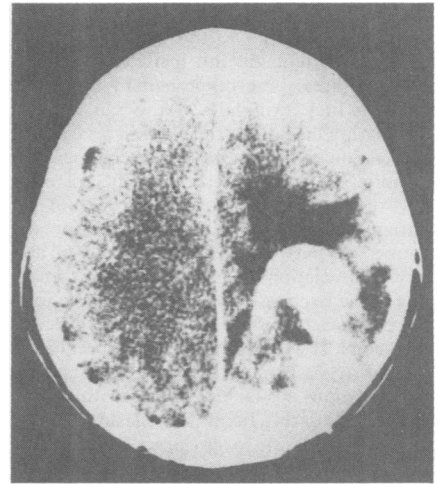


Figure Enhanced CT. A circular high density lesion is situated in the right parieto-occipital area.

each eye. External ocular movements were completely normal in every direction, and no diplopia was detected. Optic fundi were clear bilaterally. With the visual line fixed to the centre of the visual field, it was impossible for him to grasp an object at the periphery of the left homonymous visual field with the left hand, while easily possible with the right hand. Grasping an object in the right homonymous visual field with the left or right hand was performed smoothly. The patient did not exhibit visual inattention. Disturbances of the cranial nerves were not found. Muscle strength of the four extremities was symmetrically normal. Deep sensation such as joint sense, vibration sense, and deep pain was not disturbed. Two point discrimination, graphaesthesia, stereognosis, and double simultaneous stimulation were all normal. Superficial sensation was also normally preserved. There were no disorders of cerebellar functions. In the neuropsychological examination, there was no aphasia, apraxia, or visuo-spatial agnosia. On the basis of these neurological findings, it was diagnosed that the patient was suffering from optic ataxia.

Enhanced CT revealed a high density lesion in the right parieto-occipital region (fig). Subtotal removal of the tumour was performed, and it was histopathologically shown to be a malignant lymphoma. Systemic examinations revealed no malignant lymphoma elsewhere. We concluded that the tumour was a primary malignant lymphoma in the right parieto-occipital area. The residual tumour completely disappeared after whole brain irradiation of a total of 50 Gy.

In 1967 Garcin *et al* reported the case of a patient who had difficulty in grasping objects at the periphery of the visual field, when the patient's visual line was fixed.¹ They named this neurological disorder "optic ataxia (ataxie optique)". It has been revealed on CT and necropsy that optic ataxia is caused by a lesion at the junction of the parietal and occipital lobes.¹⁻⁴ Rondot *et al*² have established the concept that optic ataxia is a kind of disconnection syndrome which occurs due to interruption of nerve fibres connecting the visual association field (area 19) and the motor association field (area 6) which is responsible for identifying targets in space, for choosing a course of action, and for programming movement.⁵ It is thought that one half of the

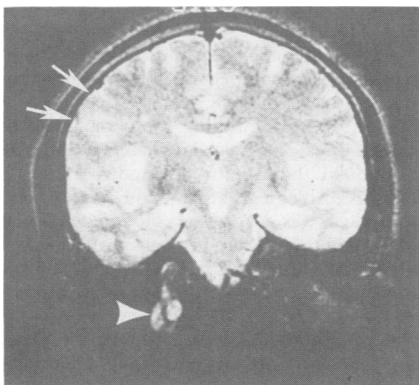


Figure Spin Echo T₂ weighted MRI (TR 2000 ms, TE = 70 ms) showing dissection of right internal carotid artery (arrowhead) and right parietal infarction (arrows).