


This article was downloaded by: [University of Winnipeg]

On: 08 September 2014, At: 12:30

Publisher: Routledge

Informa Ltd Registered in England and Wales Registered Number: 1072954 Registered office: Mortimer House, 37-41 Mortimer Street, London W1T 3JH, UK



## Neurocase: The Neural Basis of Cognition

Publication details, including instructions for authors and subscription information:  
<http://www.tandfonline.com/loi/nncs20>

### Spatial attention can transfer to the contralateral hemisphere in neonatal stroke patients: a case report following hemispherectomy

Zhanpeng Zhu <sup>a</sup>, Yu Cui <sup>b</sup>, Xiaobo Zhu <sup>c</sup>, Hongmei Song <sup>a</sup>, Haiyang Xu <sup>c</sup>, Hongquan Yu <sup>c</sup>, Lichao Sun <sup>a</sup> & Jiqing Qiu <sup>a</sup>

<sup>a</sup> Department of Neurology, First Hospital of Jilin University, Changchun 130021, P. R. China

<sup>b</sup> Department of Otolaryngology, First Hospital of Jilin University, Changchun 130021, P. R., China

<sup>c</sup> Department of Neurosurgery, First Hospital of Jilin University, Changchun 130021, P. R., China

Published online: 18 Apr 2012.

To cite this article: Zhanpeng Zhu, Yu Cui, Xiaobo Zhu, Hongmei Song, Haiyang Xu, Hongquan Yu, Lichao Sun & Jiqing Qiu (2013) Spatial attention can transfer to the contralateral hemisphere in neonatal stroke patients: a case report following hemispherectomy, *Neurocase: The Neural Basis of Cognition*, 19:2, 145-149, DOI: [10.1080/13554794.2011.654223](http://dx.doi.org/10.1080/13554794.2011.654223)

To link to this article: <http://dx.doi.org/10.1080/13554794.2011.654223>

PLEASE SCROLL DOWN FOR ARTICLE

Taylor & Francis makes every effort to ensure the accuracy of all the information (the "Content") contained in the publications on our platform. However, Taylor & Francis, our agents, and our licensors make no representations or warranties whatsoever as to the accuracy, completeness, or suitability for any purpose of the Content. Any opinions and views expressed in this publication are the opinions and views of the authors, and are not the views of or endorsed by Taylor & Francis. The accuracy of the Content should not be relied upon and should be independently verified with primary sources of information. Taylor and Francis shall not be liable for any losses, actions, claims, proceedings, demands, costs, expenses, damages, and other liabilities whatsoever or howsoever caused arising directly or indirectly in connection with, in relation to or arising out of the use of the Content.

This article may be used for research, teaching, and private study purposes. Any substantial or systematic reproduction, redistribution, reselling, loan, sub-licensing, systematic supply, or distribution in any form to anyone is expressly forbidden. Terms & Conditions of access and use can be found at <http://www.tandfonline.com/page/terms-and-conditions>

# Spatial attention can transfer to the contralateral hemisphere in neonatal stroke patients: a case report following hemispherectomy

Zhanpeng Zhu<sup>1</sup>, Yu Cui<sup>2</sup>, Xiaobo Zhu<sup>3</sup>, Hongmei Song<sup>1</sup>, Haiyang Xu<sup>3</sup>, Hongquan Yu<sup>3</sup>, Lichao Sun<sup>1</sup>, and Jiqing Qiu<sup>1</sup>

<sup>1</sup>Department of Neurology, First Hospital of Jilin University, Changchun 130021, P. R. China

<sup>2</sup>Department of Otolaryngology, First Hospital of Jilin University, Changchun 130021, P. R. China

<sup>3</sup>Department of Neurosurgery, First Hospital of Jilin University, Changchun 130021, P. R. China

Patients suffer hemispatial neglect after stroke. However, whether the function of spatial attention is reorganized to the contralateral brain remains poorly understood. Here we present a case report of neonatal stroke to demonstrate the reorganization of spatial attention in the contralateral hemisphere using a series of tests including star cancellation task, line bisection test, the bells test, letter cancellation test, and drawing tests. The patient underwent right hemispherectomy for treatment of refractory epilepsy and did not have hemispatial neglect after surgery, supporting transfer of function prior to the operation. After analyzing the literature in this field, we proposed that the function of spatial attention may transfer to the contralateral side in childhood. Thus, this study sheds new light on the preserved function of spatial attention in neonatal stroke patients even when hemispherectomy is performed.

**Keywords:** Epilepsy; Hemispatial neglect; Hemispherectomy; Neonatal stroke; Neuroplasticity.

Stroke is a cause of mortality and chronic neurological morbidity in children, frequently occurring during the neonatal period. The incidence of neonatal stroke is approximately 1 in 4000 children (Westmacott, MacGregor, Askalan, & deVeber, 2009). Unfortunately, the incidence of neonatal stroke has increased over the last decade due to higher detection rates related to improved neuroimaging. Complications of neonatal stroke include hemiparesis, language delay, behavioral problems, epilepsy (Adén 2009) and cognitive impairments (Nelson & Lynch, 2004). Nevertheless, it has been shown that the brain has enormous plasticity, and the prognosis in neonatal patients with stroke is better than that in adults (Härtel, Schilling, Sperner, & Thyen, 2004).

Hemispatial neglect is impairment of response or the inability to respond to or process sensory stimuli (such as visual, auditory, tactile and olfactory stimuli) presented contralateral to a lesion of the cerebral hemisphere (Kerkhoff, 2001). Neglect occurs in approximately 40–81% of stroke patients, and is especially prominent and severe after a right-hemisphere lesion (Arene & Hillis, 2007). Hemispatial neglect is a multicomponent syndrome and is not attributed to primary sensory and motor deficits. Just as the development of language is very well preserved in neonatal stroke patients, other cognitive functions such as hemispatial neglect may not be severe in these patients. Although previously reported by Larissa Bollea et al. (2007), it is not clear whether the function of spatial attention is

Address correspondence to Jiqing Qiu, Department of Neurology, First Hospital of Jilin University, Changchun 130021, P. R. China. (E-mail: [qiujiqing2008@163.com](mailto:qiujiqing2008@163.com)).

The authors thank Medjaden Bioscience Limited for assisting in the preparation of this paper.

rehabilitated in the injured hemisphere or transferred to the unaffected hemisphere. In this case report, we present well-preserved spatial attention function in a patient with neonatal stroke which persisted after hemispherectomy, supporting transfer of function to the unaffected hemisphere.

### CASE REPORT

Here we present a male born at 42 weeks of gestation by breech delivery who suffered a neonatal stroke. At approximately 1 month old, the mobility in his left arm and leg was diminished in comparison to the right side. By the age of 8 months old, he had severe left hemiplegia and he was subsequently treated with traditional Chinese medicine with minimal effect. At 3 years old, to rehabilitate his motor function, he was enrolled in a rehabilitation training program at Changchun Children's Hospital. The program included movement training of the left side limbs such as grasping, releasing, rotating, reaching, lifting, balance training and walking, allowing his left side muscle strength and motor function to partially recover.

He was diagnosed with complex partial seizures at 14 years of age, characterized by an aura, loss of consciousness, and generalized clonus lasting up to 1 minute, which were refractory to multiple treatments including topiramate, lamotrigine and trileptal. There was no family history of seizure.

He was recruited to epilepsy center of the First Hospital of Jilin University at 18 years old due to refractory seizures. Scalp electroencephalography revealed slow background activity in the left hemisphere, with spike-and-slow wave activity on the same hemisphere. Head magnetic resonance imaging (MRI) showed signal abnormalities in the temporo-parietal-occipital lobes and the frontal lobe of the right hemisphere, associated with severe enlargement of the subarachnoid space and of the lateral ventricle (Figure 1A). Head computed tomography angiography (CTA) revealed that the diameter of the right middle cerebral artery was smaller than that of the left middle cerebral artery.

Based on the clinical presentation, imaging data, and failure to respond to multiple treatments, anatomic hemispherectomy was performed (Figure 1B). Compared with his pre-surgical conditions, no change in motor activity of the left side was evident. The average number of antiepileptic drugs taken before surgery was three, and this was reduced to one drug after surgery.

To test whether the patient suffered from spatial neglect, a neglect-test battery was performed 2 months after the surgery. The tests included: (a) star cancellation task (Halligan, Marshall, & Wade, 1989), in which the patient was required to circle all small stars; (b) line bisection test (Eschenbeck et al., 2010), in which the patient was asked to mark the center of a line 20 cm in length; (c) bells test (Karnath, Himmelbach, & Rorden, 2002), in which the patient was required to circle all bells; (d) letter cancellation test (Karnath et al., 2002), in which the patient was required to circle all of the letters 'c' on a page; (e) drawing tests, in which the patient underwent copying tests and spontaneous drawing tests. The patient was required to make the drawing bilaterally (when a normal person draws a model using one hand, he draws the model bilaterally. When a patient has unilateral neglect, he can only draw the right side of the model); and (f) neglect dyslexia.

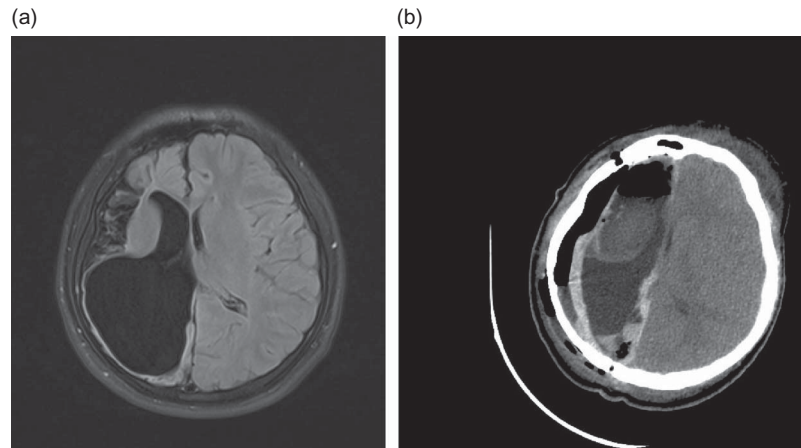
### DISCUSSION

The patient exhibited considerable motor function in his left limbs before and after surgery. This suggests that motor function on the right side of the hemisphere had been reorganized to the left side of the hemisphere during his childhood. If such reorganization indeed occurred, the patient should have the potential to achieve a spatial function transfer. We thus examined whether spatial function was preserved on the contralateral side of the brain.

A previous systematic review revealed that contralateral neglect occurs more often in strokes occurring on the right side of the hemisphere than on the left side (Bowen, McKenna, & Tallis, 1999). In the present case, the stroke also occurred on the right hemisphere.

Since this patient underwent a right side hemispherectomy, examination of the spatial neglect functions allowed us to determine that spatial attention and awareness functions had been preserved and most possibly transferred to the contralateral, undamaged left hemisphere. This observation provided new support to the way in which the contralateral hemisphere may compensate for functional loss in children with epilepsies after receiving a right hemispherectomy.

Signs of hemispatial neglect are often observed during daily activities, such as deflecting the head and eyes to the ipsilateral side (Adair & Barrett, 2008). However, we did not observe such features in the present case. Also, the patient did not have



**Figure 1.** (A) Pre-surgical neuroimaging: axial T<sub>1</sub> MRI showing the patient with cystic porencephaly. (B) Post-hemispherectomy neuroimaging: CT (computed tomography) scan showing the right anatomical hemispherectomy.

any typical clinical behaviors such as (1) orienting towards the ipsilateral side when addressed from the front or the left or (2) ignoring contralaterally located people or objects, for example, failure to eat the food from the left side of the plate.

A large trial conducted on patients with strokes of the right hemisphere has shown that the bells test, although not the most specific, was the most sensitive clinical indicator of spatial neglect (Adair & Barrett, 2008; Jalas, Lindell, Brunila, Tenovuo, & Hämäläinen, 2002). However, this test being negative with our patient clearly indicated no loss of function (Figure 2A).

Other methods for the detection of imaginal or representational neglect include drawing from memory (Adair & Barrett, 2008; Halligan, Fink, Marshall, & Vallar, 2003), bisection tests, cancellation tests, cancellation tasks and copying tests. Again, our patient performed well all in these tests (Figure 2B). Further, the patient had the ability to read a whole paragraph of Chinese characters from left side to right without difficulty, indicating no trace of neglect dyslexia.

A previous study conducted by Bollea et al. (2007) supports our results but did not show whether a patient with neonatal stroke would recover from hemispacial neglect. Our report is the first where all tests performed on a neonatal stroke patient strongly indicate well-preserved spatial awareness and normal visuospatial exploration, despite neonatal right-hemisphere stroke and anatomical right-hemispherectomy in early adolescence.

Although this report is more informative than previous reports, the mechanism of hemispacial

neglect and contralaterality transfer still remains unclear.

It has been reported that lesions of the right hemisphere are far more likely to have severe and enduring neglect than left hemisphere damage (Bowen et al., 1999; Stone, Patel, Greenwood, & Halligan, 1992). It was suggested that this was possibly due to the specialization of language on the left side of the hemisphere. It is generally accepted that cortical damage involving the right inferior parietal lobe or nearby temporo-parietal junction is implicated in causing neglect (Vallar & Perani, 1986). Moreover, the right superior temporal cortex may be an alternative location as well.

It is reported that the age of onset of seizures and the duration of a seizure have a significant influence on the mental and social age of the child during the first year of follow-up. Late onset and shorter duration of seizures prior to surgery have shown positive mental and social age gains during follow-up (Thomas, Daniel, Chacko, Thomas, & Russell, 2010). The patient in our case had epilepsy when he was 14 years old, during this time he had a slight left hemiplegia. This implies that his motor function was transferred to the contralateral side of the brain. Before the occurrence of epilepsy, he had completed 6 years at school. His recitation and writing were adequate, indicating that no hemispacial neglect had occurred. Because brain plasticity is greater in early childhood (Chiricozzi et al., 2005; Oguni et al., 2000), it is possible that under some extreme stress situation the spatial function transfers to the contralateral (left) side. Therefore, based on our observation, hemispherectomy has been a safe procedure. Most




Figure 2. (A) Evidence that the patient can circle all targets in the bells test. (B) Evidence that the patient can draw bilaterally.

particularly in terms of preservation of spatial function after adolescence in a patient with neonatal stroke after birth who could use his contralateral limbs.

In summary, a patient with neonatal ischemic infarction of the right middle cerebral artery and refractory epilepsy is reported. It was shown that spatial attention functions were well preserved despite neonatal stroke and extensive right cortical hemispherectomy in adolescence, suggesting that cerebral reorganization might effectively take place even when hemispherectomy is performed at a relatively late age. The observation supports that reorganization in the brain during childhood and late onset epilepsy might be due to post-surgical cognitive recovery (Chiricozzi et al., 2005). Further studies of hemispherectomy in patients with neglect will provide insight into the nature of the condition and perhaps also its relation to commonly associated clinical disorders such as hemiplegia.

Original manuscript received 26 July 2011

Revised manuscript accepted 31 October 2011

First published online 18 April 2012

## REFERENCES

- Adair, J. C., & Barrett, A. M. (2008). Spatial neglect: Clinical and neuroscience review: A wealth of information on the poverty of spatial attention. *Annals of the New York Academy of Sciences*, *1142*, 21–43.
- Adén, U. (2009). Neonatal stroke is not a harmless condition. *Stroke*, *40*(6), 1948–1949.
- Arene, N. U., & Hillis, A. E. (2007). Rehabilitation of unilateral spatial neglect and neuroimaging. *Europa Medicophysica*, *43*(2), 255–269.
- Bollea, L., Rosa, G. D., Gisoni, A., Guidi, P., Petrarca, M., Giannarelli, P., et al. (2007). Recovery from hemiparesis and unilateral spatial neglect after neonatal stroke. Case report and rehabilitation of an infant. *Brain Injury*, *21*(1), 81–91.
- Bowen, A., McKenna, K., & Tallis, R. C. (1999). Reasons for variability in the reported rate of occurrence of unilateral spatial neglect after stroke. *Stroke*, *30*(6), 1196–1202.
- Chiricozzi, F., Chieffo, D., Battaglia, D., Iuvone, L., Acquafondata, C., Cesarini, L., et al. (2005). Developmental plasticity after right hemispherectomy in an epileptic adolescent with early brain injury. *Child's Nervous System*, *21*(11), 960–969.
- Eschenbeck, P., Vossel, S., Weiss, P. H., Saliger, J., Karbe, H., & Fink, G. R. (2010). Testing for neglect in right-hemispheric stroke patients using a new assessment battery based upon standardized activities of daily living (ADL). *Neuropsychologia*, *48*(12), 3488–3496.
- Halligan, P. W., Fink, G. R., Marshall, J. C., & Vallar, G. (2003). Spatial cognition: Evidence from visual neglect. *Trends in Cognitive Science*, *7*(3), 125–133.
- Halligan, P. W., Marshall, J. C., & Wade, D. T. (1989). Visuospatial neglect: Underlying factors and test sensitivity. *Lancet*, *ii*(8668), 908–911.
- Härtel, C., Schilling, S., Sperner, J., & Thyen, U. (2004). The clinical outcomes of neonatal and childhood stroke: Review of the literature and implications for future research. *European Journal of Neurology*, *11*(7), 431–438.
- Jalas, M. J., Lindell, A. B., Brunila, T., Tenovuo, O., & Hämäläinen, H. (2002). Initial rightward orienting bias in clinical tasks: Normal subjects and right hemispheric stroke patients with and without neglect. *Journal of Clinical and Experimental Neuropsychology*, *24*(4), 479–490.
- Karnath, H. O., Himmelbach, M., & Rorden, C. (2002). The subcortical anatomy of human spatial neglect: Putamen, caudate nucleus and pulvinar. *Brain*, *125*(Pt 2), 350–360.
- Kerkhoff, G. (2001). Spatial hemineglect in humans. *Progress in Neurobiology*, *63*(1), 1–27.
- Nelson, K. B., & Lynch, J. K. (2004). Stroke in newborn infants. *The Lancet Neurology*, *3*(3), 150–158.
- Oguni, H., Mukahira, K., Tanaka, T., Awaya, Y., Saito, K., Shimizu, H., et al. (2000). Surgical indication for refractory childhood epilepsy. *Epilepsia*, *41*(Suppl. 9), 21–25.
- Stone, S. P., Patel, P., Greenwood, R. J., & Halligan, P. W. (1992). Measuring visual neglect in acute stroke and predicting its recovery: The visual neglect recovery index. *Journal of Neurology, Neurosurgery and Psychiatry*, *55*(6), 431–436.
- Thomas, S. G., Daniel, R. T., Chacko, A. G., Thomas, M., & Russell, P. S. (2010). Cognitive changes following surgery in intractable hemispheric and sub-hemispheric pediatric epilepsy. *Child's Nervous System*, *26*(8), 1067–1073.
- Vallar, G., & Perani, D. (1989). The anatomy of unilateral neglect after right-hemisphere stroke lesions. A clinical/CT-scan correlation study in man. *Neuropsychologia*, *24*(5), 609–622.
- Westmacott, R., MacGregor, D., Askalan, R., & deVeber, G. (2009). Late emergence of cognitive deficits after unilateral neonatal stroke. *Stroke*, *40*(6), 2012–2019.