



Published in final edited form as:

*Ann N Y Acad Sci.* 2012 April ; 1252: 237–245. doi:10.1111/j.1749-6632.2012.06454.x.

## When right is all that's left: plasticity of right-hemisphere tracts in a young aphasic patient

Lauryn Zipse<sup>1,2</sup>, Andrea Norton<sup>2</sup>, Sarah Marchina<sup>2</sup>, and Gottfried Schlaug<sup>2</sup>

<sup>1</sup>Department of Communication Sciences and Disorders, MGH Institute of Health Professions, Boston, Massachusetts

<sup>2</sup>Department of Neurology, Music, Neuroimaging, and Stroke Recovery Laboratory, Beth Israel Deaconess Medical Center, Boston, Massachusetts

### Abstract

Using an adapted version of melodic intonation therapy (MIT), we treated an adolescent girl with a very large left-hemisphere lesion and severe nonfluent aphasia secondary to an ischemic stroke. At the time of her initial assessment 1.25 years after her stroke, she had reached a plateau in her recovery despite intense and long-term traditional speech-language therapy (approximately five times per week for more than one year). Following an intensive course of treatment with our adapted form of MIT, her performance improved on both trained and untrained phrases, as well as on speech and language tasks. These behavioral improvements were accompanied by functional MRI changes in the right frontal lobe as well as by an increased volume of white matter pathways in the right hemisphere. No increase in white matter volume was seen in her healthy twin sister, who was scanned twice over the same time period. This case study not only provides further evidence for MIT's effectiveness, but also indicates that intensive treatment can induce functional and structural changes in a right hemisphere fronto-temporal network.

### Keywords

aphasia; melodic intonation therapy; brain plasticity; diffusion tensor imaging

### Introduction

First described nearly 40 years ago as a treatment for nonfluent aphasia,<sup>1,2</sup> melodic intonation therapy (MIT) was based on the clinical observation that individuals with severe nonfluent aphasia can often sing phrases that they cannot speak.<sup>3,4</sup> MIT capitalizes on this preserved ability by using words or phrases intoned (sung) on two pitches to exaggerate the natural prosody of speech. Over the course of treatment, patients are guided through a hierarchical series of steps designed to increase fluency while decreasing dependence on therapist support.<sup>5,6</sup> The original developers of MIT suggested that the treatment worked by engaging language-capable right-hemisphere regions to compensate for the damaged left-hemisphere.<sup>1,2</sup> To further encourage right-hemisphere activity and emphasize the production of each syllable, MIT also includes a motoric element, left hand-tapping, which may help to engage a right-hemispheric sensorimotor network shared by hand and articulatory actions.<sup>7,8</sup> Functional neuroimaging studies have sought to determine whether improvements seen with MIT are in fact associated with increased right-hemisphere activity. The findings have been

mixed.<sup>9-10</sup> This inconsistency is most likely due to differences in patient characteristics (e.g., lesion size and location, aphasia diagnosis (Broca's vs. global), time post-onset, etc.) as well as variations in study design (e.g., post-treatment assessment only, cross-sectional studies of singing without actual treatment, longitudinal treatment studies with pre- and post- assessments, etc.).

In a recently published case series, we used diffusion tensor imaging (DTI) to demonstrate an association between increases in a right-hemisphere fiber tract and improvements in verbal output following treatment with MIT. The case series included six adult patients with nonfluent aphasia secondary to left-hemisphere strokes. These patients showed increases in both volume and number of fibers of the right arcuate fasciculus (AF, a fiber tract that connects the superior temporal lobe to the inferior frontal gyrus and motor/premotor regions in a reciprocal way) that corresponded with speech output improvements after long-term and intense treatment.<sup>11</sup> In the current single case study, we aimed to determine whether functional and structural brain changes could also be observed in a young adolescent girl whose extensive left-hemisphere lesion included the middle and posterior cerebral artery territories and encompassed the classical Broca's and Wernicke's regions. This lesion left the patient, LF, with a nonfluent aphasia, and surprisingly, relatively unimpaired comprehension. In addition, we sought to determine whether plasticity processes would differ in this young patient compared to the previously described group of adult patients, since it has been suggested in the literature that recovery processes may be influenced by developmental trajectory.<sup>12</sup> To explore the neural basis of speech and language recovery, we assessed LF's functional communication abilities at several time points before, during, and after treatment and related them to functional and structural imaging changes. We also tracked her improvement on production of trained and untrained phrases during treatment. LF has a healthy twin sister who served as a control case. Her twin underwent two DTI studies at time points that corresponded to the interval between LF's Baseline and Post80 scans. LF was scanned more frequently and also had a long-term outcome measure.

Our goals were to test the efficacy of our adaptation of MIT for a patient who did not meet the traditional inclusion criteria for this treatment and to investigate which structural and functional changes might support MIT-induced improvement when no viable left-hemisphere areas remain to support recovery of speech function.

## Methods

### Patient

Prior to an ischemic stroke, LF was a healthy, right-handed 11-year-old girl with no significant events in her medical history. Her stroke resulted in a very large left-hemisphere lesion (Fig. 1a). The cause of LF's stroke remained unclear despite an extensive work-up. No dissection, vasculitis, or hypercoagulable state was detected. Furthermore, her cardiac work-up was negative. Thus, she was classified as a stroke of undetermined etiology. When we first evaluated LF at age 12;11, 15 months post-stroke, she had already received 1.25 years of intensive traditional speech therapy (at least five times per week). Her nonverbal IQ, as measured with *Raven's Coloured Progressive Matrices*,<sup>13</sup> was mildly impaired (28/36; norms are only available through age 11;8). Qualitatively, her speech was nonfluent and agrammatic, with notable word-finding difficulties. Word-finding difficulties were documented in her performance on the *Boston Naming Test*,<sup>14</sup> on which she scored 17/60. Her repetition was moderately impaired (8/10 on the Word Repetition subtest of the *Boston Diagnostic Aphasia Examination, BDAE*;<sup>15</sup> 40<sup>th</sup> percentile), and her auditory comprehension was relatively preserved (34/37 on *BDAE* Word Comprehension, 15/15 on Following Commands, and 9/12 on Complex Ideational Material). On the *Apraxia Battery for Adults-2<sup>nd</sup> edition (ABA-2)*,<sup>16</sup> LF's levels of impairment varied across subtests from

“None” to “Severe,” but severe deficits were only seen on the repetition of long words and sentences. Somewhat surprisingly considering the size of her lesion, there was no evidence of non-speech oral apraxia or limb apraxia. Overall, her profile was consistent with a diagnosis of Broca's aphasia.

### Experimental design

A multiple baselines design was used to evaluate treatment efficacy in terms of improvement on production of trained vs. untrained target phrases. Functional communication abilities were also assessed over time, using a picture description task and a semi-structured conversational interview. Performance on these functional communication tasks was documented prior to the initiation of treatment (Baselines 1-3), mid-way through treatment (after 40 treatment sessions; Post40), at the conclusion of treatment (Post80), and one month after the conclusion of treatment (Maintenance). Baselines 1 and 2 were separated by four months, and Baselines 2 and 3 were separated by one month. Functional imaging, using fMRI to assess cortical activity during the repetition of spoken phrases, was performed at Baseline, Post40, Post80, and Maintenance. At Baseline, Post40, Post80, and one year after the conclusion of treatment (1yearPost), the size and integrity of fiber tracts associated with speech and language processing were measured using DTI. LF's healthy identical twin sister served as a control for the DTI measures, undergoing scans at two time points that spanned the course of LF's treatment (corresponding to Baseline and Post80).

### Treatment

LF underwent an intensive course of adapted MIT, attending five, 1.5-hour treatment sessions per week for 16 weeks, totaling 80 sessions (120 hours of treatment). Sessions followed a format consistent with the original MIT methodology, with target phrases trained using a hierarchical series of steps that have been described in detail elsewhere.<sup>7</sup> The clinician presented a stimulus picture as a visual cue with each target phrase. Sentences were intoned (sung) on two pitches, while the clinician tapped LF's left hand once per syllable.

Treatment was divided into two phases, with 60 trained phrases per phase. Each phase was subdivided into two levels of difficulty (a and b). During Phase I, LF was introduced to the principles of MIT as it is applied in our clinic.<sup>7</sup> Accordingly, she was instructed to use inner rehearsal (i.e., “*hear* the phrase in your head *before* you sing out loud”) and was encouraged to use a slow, steady rate with continuous voicing. Phrases trained during Phase Ia consisted of four, six, and eight syllables, while those trained during Phase Ib contained either eight or ten syllables.

Phase II treatment followed the same general structure as Phase I, but added another element: an emphasis on syntax. Because LF had so readily mastered phrases in Phase I yet still lacked fluency, our rationale for placing special emphasis on structure and sequence in Phase II was to further improve LF's fluency while targeting areas of difficulty (i.e., gender-specific pronouns, prepositions, etc.) for remediation. By the end of Phase I, LF had succeeded in consistently singing, using a slower rate, and connecting her speech during treatment. Although her conversational speech had improved, it was still notably agrammatic, requiring the listener to interpret LF's telegraphic utterances and/or ask questions for clarification. Phase II was designed to reinforce the MIT principles introduced during Phase I as well as emphasize and train selected syntactic structures. During Phase IIa, the target phrases consisted of 10 intransitive verb sentences (e.g., *She is sneezing*), 10 direct object sentences (e.g., *He is feeding the cat*), and 10 sentences with prepositional phrases (e.g., *They are sledding down the hill*). During Phase IIb, the target phrases consisted of 20 sentences with prepositional phrases and 10 sentences with both direct objects and prepositional phrases (e.g., *She is playing a card game with her mom*).

### Behavioral data: treatment probes

Probes were conducted after every eight treatment sessions, with six probes during Phase I and 4 during Phase II. The probe task was repetition: the clinician intoned the target phrase while tapping, and LF was cued to repeat the target. Trained phrases were randomly interspersed with untrained phrases. In Phase I, trained and untrained phrases were matched on phrase length (number of syllables) and number of closed-class words. In Phase II, phrases were matched on phrase length and argument structure of the main verb.

### Behavioral data: functional speech and language

Language samples obtained from the picture description and semi-structured conversational interview were transcribed and scored. Picture description was presented as a timed task and assessed in terms of communicative efficiency; therefore, performance was measured as the number of *Correct Information Units (CIUs) per minute*. CIUs are defined as words that are informative, accurate, and relevant.<sup>17</sup> The interview was assessed for LF's ability to produce connected speech and share the conversational burden. These elements were quantified, respectively, as *syllables per phrase* and *CIUs per conversational turn*. Twenty-five percent of the language samples were double-scored by a trained research assistant. Inter-rater agreement was >85% for all measures.

### fMRI stimuli and MR data acquisition

For the fMRI task, LF heard two-syllable words or phrases *spoken* or *sung* at the rate of one syllable/sec. Following each word/phrase, LF repeated what she had heard after an auditory cue. In the control condition, LF waited for the auditory cue, and then took a breath as if she planned to speak or sing, but remained silent. The fMRI paradigm and data acquisition methods have been described in detail previously.<sup>18</sup>

### fMRI data analysis

fMRI data were analyzed using the SPM5 software package.<sup>19</sup> Pre-processing was done as previously described.<sup>19</sup> A left-hemisphere lesion mask was used to restrict the analysis to brain tissue outside of the large lesion area, since any task-related signal changes in the lesioned area would have to have been an artifact due, most likely, to changes in brain pulsation or fluid changes in the pseudocystic area.

A design matrix for each imaging time point was modeled to look at the *speaking* vs. *silence* (control) condition at each individual time point. In order to look at between-time points effects, we entered contrasts into a fixed-effects design matrix for two imaging time points at a time.

### Preprocessing and probabilistic tractography of DTI data

The pre-processing and fiber tracking was done with FSL version 4.1.4.<sup>20</sup> In order to correct for eddy currents and head motion,<sup>21</sup> a 3D affine registration was applied, followed by brain extraction.<sup>22</sup> We then fitted a diffusion tensor model at each voxel using FSL's FMRIB Diffusion Toolbox to calculate tract volume. Fiber tracking was performed using a probabilistic tractography method based on a multifiber model, and applied using tractography routines implemented in FSL's FDT toolkit.<sup>23-24</sup>

We considered two fiber tracts in LF's right hemisphere that, in the left hemisphere, have been associated with speech- and language-processing: the arcuate fasciculus (AF) and the uncinate fasciculus (UF). We assessed these same two fiber tracts in the right hemisphere of LF's twin sister. We have previously described details of the anatomical definitions of the AF and UF.<sup>25</sup> In order to account for possible variations in scan quality across scanning

sessions, the AF and UF were normalized to the volume of the right hemisphere corticospinal tract of each twin at each time point. For details on the definition and reconstruction of the corticospinal tract, see our publications by Lindenberg *et al.*<sup>33</sup> and Zhu *et al.*<sup>34</sup> The volumes of the various ROIs used to define the tracts did not differ significantly between time points within either sister.

## Results

### Treatment probes

LF showed improvement on both the trained and untrained phrases, but with a consistently steeper slope of improvement on the trained items (Fig. 2).

### Functional speech and language measures

LF's levels of ability to produce fluent speech in conversation (syllables/phrase) and share the conversational burden (CIUs/conversational turn) were stable at baseline, improved notably with treatment, and demonstrated reasonable maintenance of treatment gains (Fig. 3). In contrast, while LF's ability to efficiently describe pictures (CIUs/min) also improved over time, the steepest slope of improvement occurred between the second and third baseline measures, prior to treatment, but the treatment phase still showed pronounced improvements beyond the changes seen in this measure during baseline assessments.

### fMRI data

The only contrasts revealing activation in right-hemisphere frontotemporal regions were Post40 > Baseline, Post40 > Post80, Post40 > Maintenance, Baseline > Post80, and Baseline > Maintenance. Since regions of activation were essentially identical at Post80 and Maintenance, only the contrasts between Baseline, Post40, and Post80 are shown (Fig. 1b-d). There was an increase in activation in right supplementary motor areas after approximately eight weeks of treatment (Post40), but this additional activation slightly decreased after an additional eight weeks of treatment. The Baseline > Post80 contrast showed higher levels of activation in the right posterior middle temporal gyrus (MTG), occipital cortex, and possibly cerebellum.

### DTI data

For LF, both the AF and UF increased in volume between the beginning of treatment and the midpoint of treatment. While AF volume continued to increase slightly between the midpoint and the conclusion of treatment, UF volume appeared to decrease somewhat (Fig. 4) during that period. Both the AF and UF increased in volume between the end of treatment and the scan at one year post-treatment. DTI studies obtained in LFON's healthy twin sister revealed a higher volume of both AF and UF at the first imaging study, but then a slight decrease over time.

## Discussion

This study provides additional evidence for the efficacy of MIT in an adolescent with a large left-hemisphere stroke, and it supports the adaptation of MIT for use with a broader range of people with aphasia. LF showed greater improvement on trained phrases than untrained phrases across all treatment phases. Although she also showed improvement on untrained phrases, it was more modest and likely due in part to generalization. Most importantly, LF showed an increased ability to produce connected speech in conversation and share the conversational burden; these gains are both highly functional and clinically significant. As a reflection of this, family members commented positively on the noticeable gains LF made in her ability to communicate during the course of the treatment.

While the measures of LF's abilities in conversation showed stable baselines and steep slopes of improvement during treatment, the measure of communicative efficiency during picture description actually showed the steepest slope of improvement between the second and third baselines. We believe that this is a practice effect and, unfortunately, our study design failed to account for the likelihood of such an effect. In an attempt to keep the measures across time points as controlled as possible, we used the same three pictures at every time point. As a consequence, LF learned to efficiently describe these pictures, with the greatest rate of improvement seen between the two testing sessions that were closest in time, Baselines 2 and 3, which were only a month apart.

As revealed by the fMRI data, LF's pattern of cortical activity during speaking changed over the course of therapy. From baseline to midway through therapy (approximately eight weeks), she showed a strong increase in activation of right posterior middle frontal and inferior frontal areas. This activation then decreased back to baseline levels. While this finding may seem somewhat surprising, it could reflect an increased efficiency of a right-hemisphere fronto-temporal system that, as the DTI data showed, changed markedly during that time. Increased right-hemisphere activation following a left-hemisphere lesion has sometimes been interpreted as maladaptive and a consequence of disinhibition.<sup>26</sup> It has also been suggested that increased right-hemisphere activation may persist in people with very large left-hemisphere lesions in order to compensate for the damaged regions.<sup>27</sup> In LF's case, though, the biphasic change in activation occurred in the context of continuous behavioral improvement. We therefore suggest that activation increased initially in response to the demands of treatment, but then decreased as processes became more automatized. In other words, automatization was supported by the upregulation of the system of right frontotemporal region, which then became more efficient and less energy-demanding.

The structural white matter increases that we observed in the UF and AF must be interpreted with some caution, since these data are from a single patient. However, the observed changes in the AF are consistent with our previous findings in adult subjects undergoing intense treatment with MIT. Furthermore, we had an additional degree of experimental control since LF's healthy twin sister also underwent two DTI scans at time points that corresponded to the interval between LF's Baseline and Post80 scans. LF's twin showed higher AF and UF volumes than LF at baseline, presumably because the twin had typical speech while LF had very limited verbal output in the 15 months between the onset of her stroke and our first evaluation of her. While LF showed increases in her tract volumes from Baseline to Post80, her twin showed decreases in both the AF and the UF. With just two time points, we cannot rule out that these differences could be due to either random variation or differences in scan quality. However, we posit that these volume decreases could be due to synaptic pruning occurring during the pre-puberty period.<sup>28</sup>

The increases in this young patient's AF are exceptionally interesting because, in healthy individuals, the left AF links posterior language areas to frontal areas important for motor speech and for the mapping of sounds to motor actions.<sup>8,29</sup> Furthermore, the degree of damage to the left AF has been shown to be correlated with negative speech and language outcomes, at least in patients who sustained strokes as adults.<sup>27</sup> The observed increases in right AF volume may indicate that this tract can play an important role in mapping speech sounds to motor commands when left-hemisphere pathways are no longer available. Since LF no longer has a left perisylvian region, we believe the right hemisphere must have subsumed the processes that support her speech and language function, and that the increases in right AF volume reflect a stronger link between posterior sensory language areas, now presumably located in the right hemisphere, and frontal motor regions.

Although this degree of plasticity might appear surprising, LF's case is rather exceptional in that she is young and has so little left-hemisphere tissue remaining. Thus, it is clear that any observed improvements in speech and language function must be supported by the right hemisphere. It seems likely that LF's age was an important factor in her marked recovery. The impact of age at time of brain insult is a complex issue, since this variable apparently interacts with many others.<sup>13</sup> While some researchers and clinicians have stated that age six is the end of a critical period for language acquisition, at which time language function is firmly instantiated in the left hemisphere, there is evidence that the left-lateralization of language function occurs gradually throughout childhood, at least through age 11.<sup>30</sup> The present study provides further evidence that marked plasticity is possible into early adolescence. Some researchers have even suggested that large unilateral lesions may force interhemispheric transfer and lead to better functional outcomes than would be seen with moderate-sized lesions.<sup>13</sup> While LF was still noticeably aphasic after treatment concluded, her improvements in fluency were remarkable.

## Acknowledgments

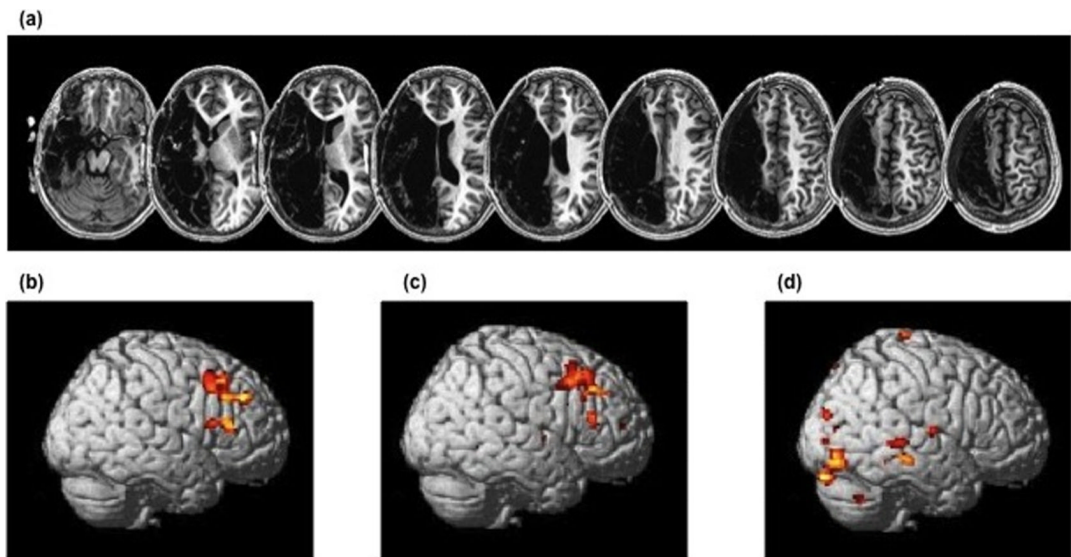
This work was supported by grants from the NIH/NIDCD to GS (RO1 DC008796). GS also acknowledges support from the Mary Crown and William Ellis Family Fund and the Rosalyn and Richard Slifka Family Fund.

## References

1. Albert ML, Sparks RW, Helm NA. Melodic intonation therapy for aphasia. *Arch. Neurol.* 1973; 29:130–131. [PubMed: 4717723]
2. Sparks R, Helm N, Albert M. Aphasia rehabilitation resulting from melodic intonation therapy. *Cortex.* 1974; 10:303–316. [PubMed: 4452250]
3. Gerstman HL. A case of aphasia. *J. Speech Hear. Dis.* 1964; 29:89–91.
4. Geschwind N. Current concepts: Aphasia. *New Engl. J. Med.* 1971; 284:654–656. [PubMed: 5545606]
5. Helm-Estabrooks, N.; Albert, ML. *Melodic Intonation Therapy: Manual of Aphasia and Aphasia Therapy.* 2nd ed.. Pro-Ed.; Austin, TX: 2004. p. 221-233.chapt.16
6. Helm-Estabrooks, N.; Nicholas, M.; Morgan, A. *Melodic Intonation Therapy.* Pro-Ed., Inc.; Austin, TX: 1989.
7. Norton A, Zipse L, Marchina S, Schlaug G. Melodic intonation therapy: shared insights on how it is done and why it might help. *Ann. NYAS.* 2009; 1169:431–436.
8. Schlaug G, Norton A, Marchina S, Zipse L, Wan CY. From singing to speaking: facilitating recovery from nonfluent aphasia. *Future Neurol.* 2010; 5:657–665. [PubMed: 21088709]
9. Belin P, Van Eeckhout P, Zilbovicius M, Remy P, François C, Guillaume S, Chain F, Rancurel G, Samson Y. Recovery from nonfluent aphasia after melodic intonation therapy: a PET study. *Neurology.* 1996; 47:1504–1511. [PubMed: 8960735]
10. Schlaug G, Marchina S, Norton A. From singing to speaking: why singing may lead to recovery of expressive language function in patients with Broca's aphasia. *Music Percept.* 2008; 25:315–323. [PubMed: 21197418]
11. Schlaug G, Marchina S, Norton A. Evidence for plasticity in white-matter tracts of patients with chronic Broca's aphasia undergoing intense intonation-based speech therapy. *Ann. NYAS.* 2009; 1169:385–394.
12. Anderson V, Spencer-Smith M, Wood A. Do children really recover better? Neurobehavioral plasticity after early brain insult. *Brain.* 2011; 134:2197–2221. [PubMed: 21784775]
13. Raven, JC. *Coloured Progressive Matrices.* Oxford Psychologists Press; Oxford, United Kingdom: 1995.
14. Kaplan, E.; Goodglass, H.; Weintraub, S. *Boston Naming Test.* 2nd Edition. Lippincott Williams & Wilkins; Baltimore: 2001.

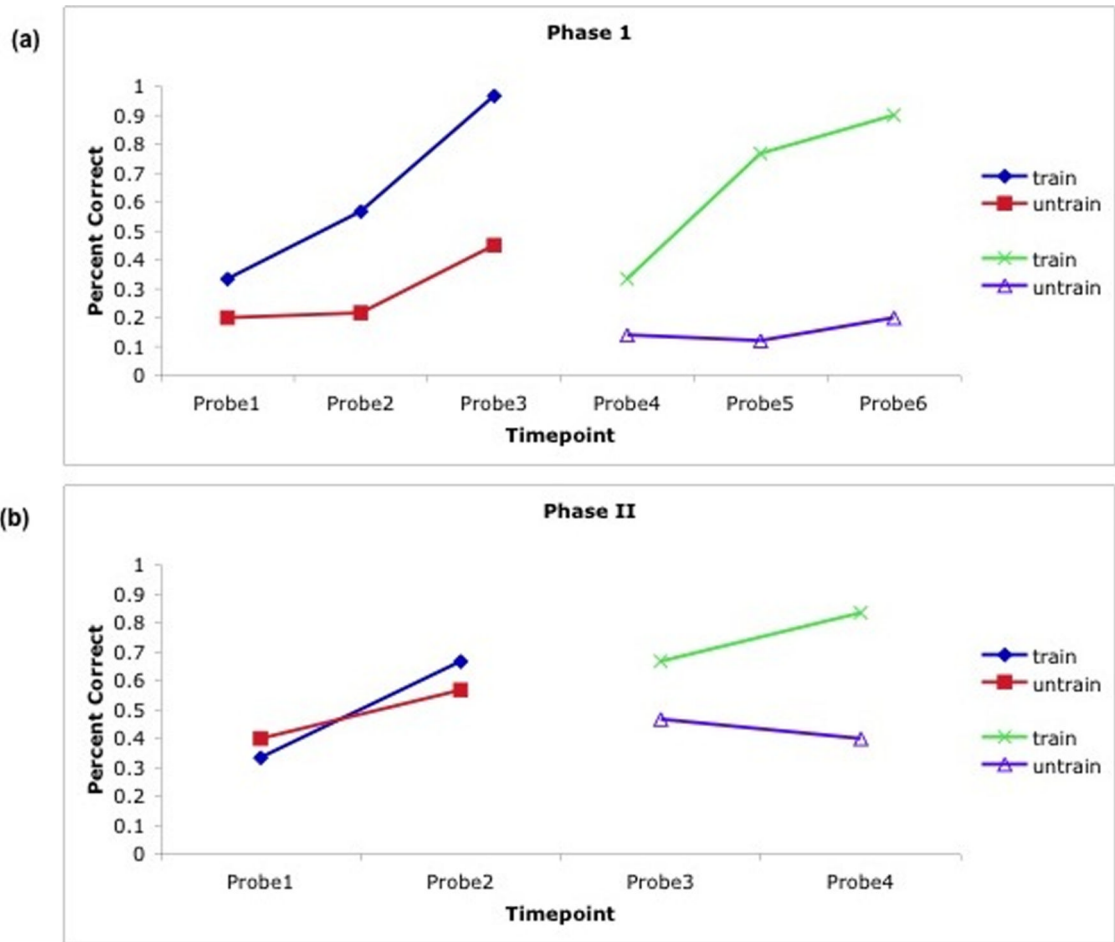
15. Goodglass, H.; Kaplan, E.; Barresi, B. *The Assessment of Aphasia and Related Disorders*. 3rd Edition. Lippincott, Williams and Wilkins; Baltimore: 2001.
16. Dabul, BL. *Apraxia Battery for Adults*. 2nd edition. Pro-Ed; 2000.
17. Nicholas L,E, Brookshire RH. A system for quantifying the informativeness and efficiency of the connected speech of adults with aphasia. *J. Speech Hear. Res.* 1993; 36:338–350. [PubMed: 8487525]
18. Ozdemir E, Norton A, Schlaug G. Shared and distinct neural correlates of singing and speaking. *Neuroimage.* 2006; 33:628–635. [PubMed: 16956772]
19. Institute of Neurology. London, UK:
20. <http://www.fmrib.ox.ac.uk/fsl>
21. Jenkinson M, Smith S. A global optimization method for robust affine registration of brain images. *Med. Image Anal.* 2001; 5:143–156. [PubMed: 11516708]
22. Smith SM. Fast robust automated brain extraction. *Hum. Brain Mapp.* 2002; 17:143–155. [PubMed: 12391568]
23. Behrens TE, Berg HJ, Jbabdi S, Rushworth MF, Woolrich MW. Probabilistic diffusion tractography with multiple fibre orientations: what can we gain? *NeuroImage.* 2007; 34:144–155. [PubMed: 17070705]
24. Smith SM, Jenkinson M, Woolrich MW, Beckmann CF, Behrens TE, Johansen-Berg H, Bannister PR, De Luca M, Drobnjak I, Flitney DE, Niazy RK, Saunders J, Vickers J, Zhang Y, De Stefano N, Brady JM, Matthews PM. Advances in functional and structural MR image analysis and implementation in FSL. *NeuroImage.* 2004; 23:S208–S219. [PubMed: 15501092]
25. Marchina S, Zhu LL, Norton A, Zipse L, Wan CY, Schlaug G. Impairment of speech production predicted by lesion load of the left arcuate fasciculus. *Stroke.* 2011; 42:2252–2256.
26. Naeser MA, Martin PI, Nicholas M, Baker EH, Seekins H, Kobayashi M, Theoret H, Fregni F, Maria-Tormos J, Kurland J, Doron KW, Pascual-Leone A. Improved picture naming in chronic aphasia after TMS to part of right Broca's area: an open-protocol study. *Brain Lang.* 2005; 93:95–105. [PubMed: 15766771]
27. Saur D, Lange R, Baumgaertner A, Schraknepper V, Willmes K, Rijntjes M, Weiller C. Dynamics of language reorganization after stroke. *Brain.* 2006; 129:1371–1384. [PubMed: 16638796]
28. Sowell ER, Thompson PM, Leonard CL, Welcome SE, Kan E, Toga AW. Longitudinal mapping of cortical thickness and brain growth in normal children. *J. Neurosci.* 2004; 24:8223–8231. [PubMed: 15385605]
29. Lahav A, Saltzman E, Schlaug G. Action representation of sound: audiomotor recognition network while listening to newly-acquired actions. *J. Neurosci.* 2007; 27:308–314. [PubMed: 17215391]
30. Hertz-Pannier L, Chiron C, Jambaqué I, Renaux-Kieffer V, Van de Moortele P, Delalande O, Fohlen M, Brunelle F, Le Bihan D. Late plasticity for language in a child's non-dominant hemisphere. *Brain.* 2002; 125:361–372. [PubMed: 11844736]
33. Lindenberg R, Renga V, Zhu LL, Betzler F, Alsop D, Schlaug G. Structural integrity of corticospinal motor fibers predicts motor impairment in chronic stroke. *Neurology.* 2010; 74:280–287. [PubMed: 20101033]
34. Zhu LL, Lindenberg R, Alexander MP, Schlaug G. Lesion load of the corticospinal tract predicts motor impairment in chronic stroke. *Stroke.* 2010; 41:910–915. [PubMed: 20378864]





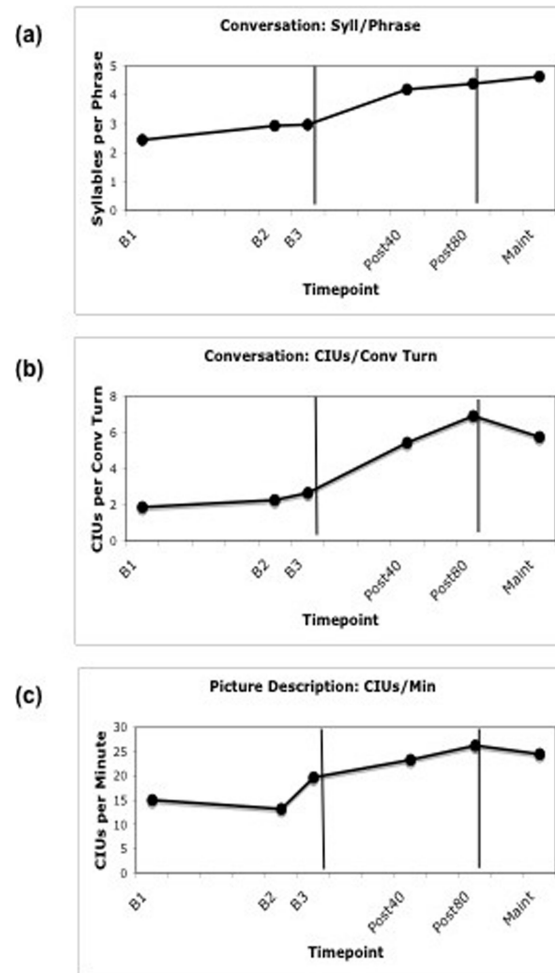
**Figure 1.**

Structural MRI and functional fMRI images. (a) T1-weighted images of LF's brain, showing the large left-hemisphere lesion. (b) Post40 > Baseline, showing regions of greater activation after 40 treatment sessions with MIT compared to baseline. (c) Post40 > Post80, showing regions of greater activation after 40 treatment sessions compared to after 80 sessions. (d) Baseline > Post80, showing regions of greater activation at baseline compared to after 80 sessions. For functional images, yellow indicates regions of highest activation (thresholded at  $p < 0.001$ , uncorrected). Areas of activation are superimposed on a spatially-standardized normal brain. All contrasts compare speaking > silence between time points.

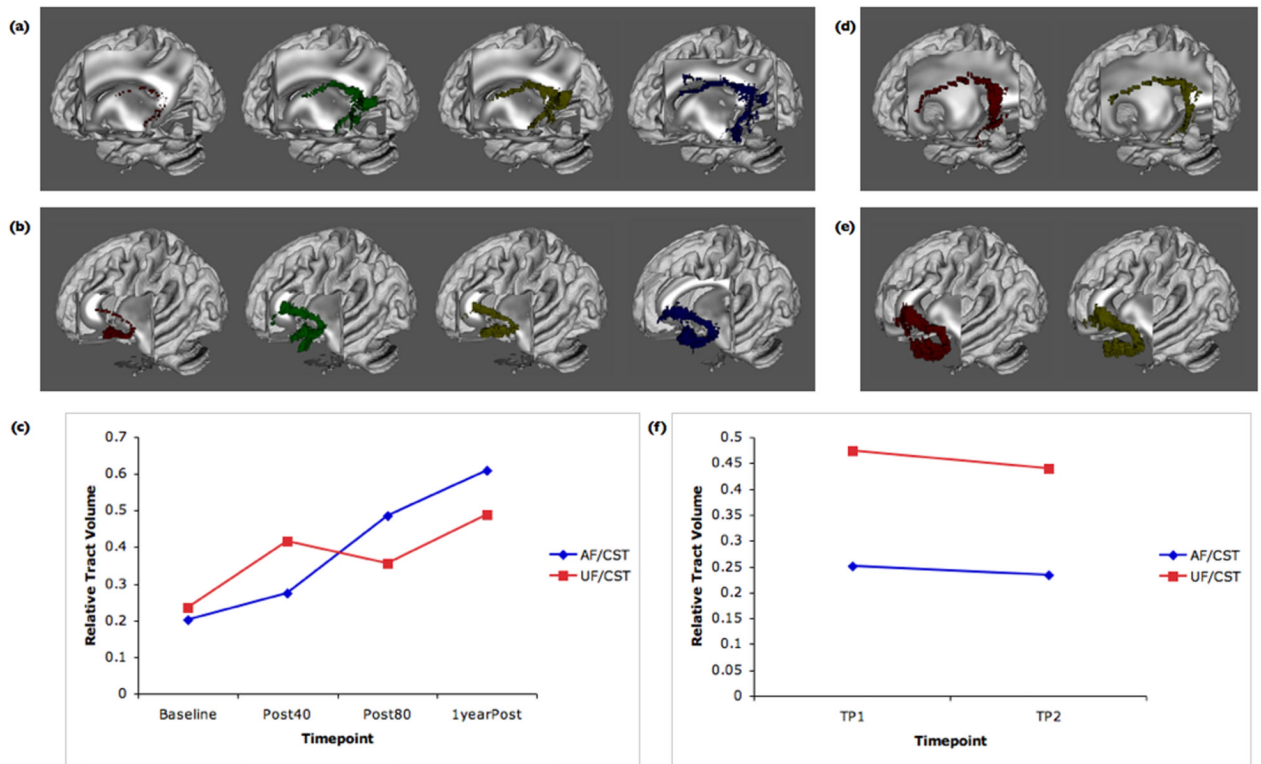


**Figure 2.**

Improvement on trained vs. untrained phrases. (a) Treatment in Phase I introduced the principles of MIT as it is applied in our clinic, and emphasized slow, intoned speech with continuous voicing, and the use of inner rehearsal. (b) Treatment in Phase II reinforced the principles introduced in Phase I, and also trained syntactic structures. Across all phases, the rate of improvement was greater for the trained compared to the untrained phrases.



**Figure 3.** Generalization to functional language tasks. Improvement on a measure of fluency, Syllables per Phrase (a), and ability to share the conversational burden, Correct Information Units (CIUs) per conversational turn, during a semi-structured conversation. (b) Improvement on a measure of communicative efficiency, CIUs per minute, during a picture description task.



**Figure 4.**

Changes in the AF and UF after treatment with MIT. LF's AF (a) and UF (b) are shown at Baseline, Post40, Post 80, and at one year post-treatment, and (c) volumes for the two tracts are plotted for the same four time points normalized by the corticospinal tract volume of the right hemisphere. For LF's twin sister, the AF (d) and UF (e) are shown at time points 1 and 2, and (f) relative volumes for these tracts are plotted over time. Time points 1 and 2 for LF's twin sister were separated by approximately four months, to match the interval between LF's Baseline and Post80 scans, which is the period during which the maximal structural change occurred.