

A surgical case of cerebral hemorrhage in a patient with factor XI deficiency

Yukihiro Goto^a, Ichita Taniyama^b, Toshihiko Ebisu^a and Katsuyoshi Mineura^b

A 63-year-old man suddenly presented with right hemiplegia and was taken to our hospital. Computed tomography (CT) scan revealed subcortical hemorrhage of the left parietal lobe. He had no medical history except hypertension; thus, it initially appeared to be a typical hypertensive hemorrhage. However, blood analysis showed an abnormally elevated activated partial thromboplastin time. One hour after admission, his Glasgow Coma Scale fell from 14 to 11. We performed an echo-guided stereotaxic removal of the hematoma. He improved immediately and was diagnosed with congenital factor XI (FXI) deficiency a few days after surgery. FXI deficiency, described as hemophilic syndrome C, rarely manifests as spontaneous bleeding, but surgical intervention has been known to manifest as bleeding. This case highlights the importance of evaluation of coagulopathies in patients with intracerebral hemorrhage before surgery, and, in cases wherein blood

analysis results suggest coexisting coagulation disorders, less invasive surgical methods would likely lead to good outcomes. *Blood Coagul Fibrinolysis* 23:456–458 © 2012 Wolters Kluwer Health | Lippincott Williams & Wilkins.

Blood Coagulation and Fibrinolysis 2012, 23:456–458

Keywords: cerebral hemorrhage, factor XI deficiency, surgery

^aDepartment of Neurosurgery, Nantan General Hospital, Nantan-city and ^bDepartment of Neurosurgery, Kyoto Prefectural University Graduate School of Medicine, Kamigyo-ku, Kyoto, Japan

Correspondence to Yukihiro Goto, MD, Department of Neurosurgery, Nantan General Hospital, Yagicho-Yagiueno 25, Nantan-city, Kyoto 629-0197, Japan
Tel: +81 771 42 2510; fax: +81 771 42 2096;
e-mail: yoursongmysong@hotmail.com

Received 13 December 2011 **Revised** 17 February 2012
Accepted 13 March 2012

Introduction

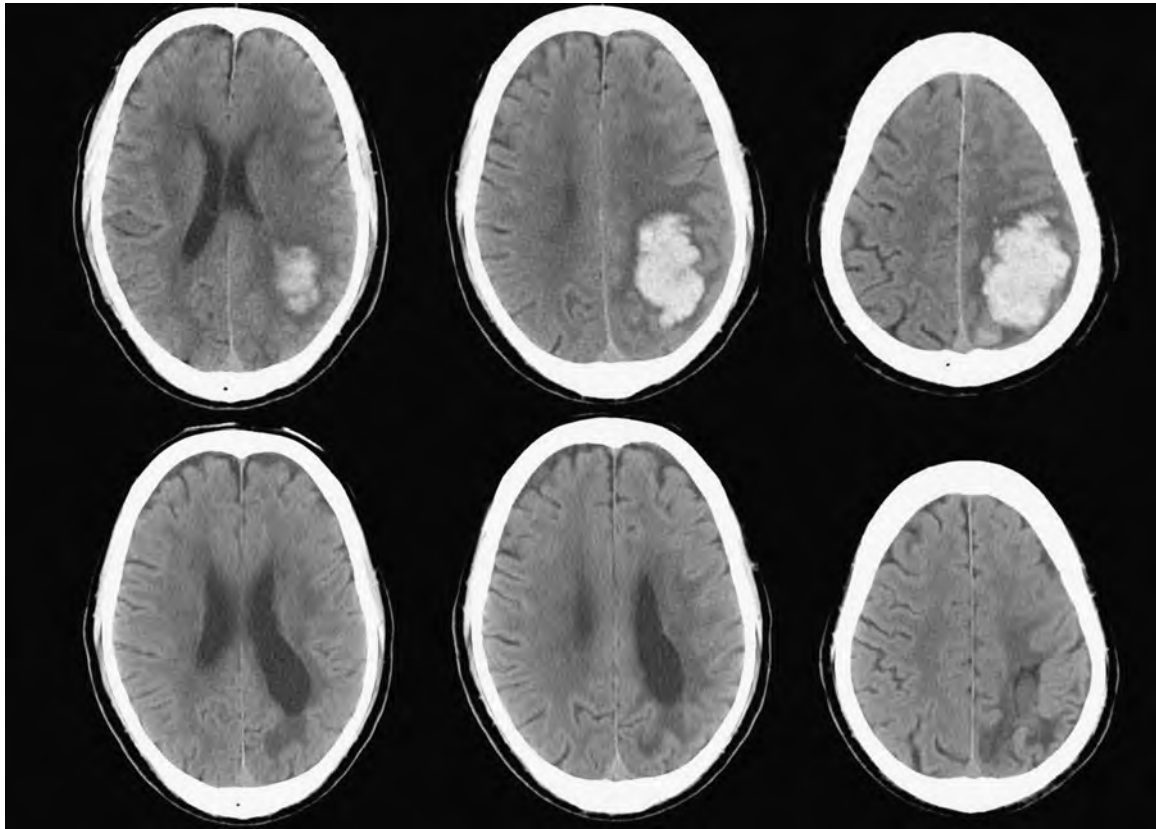
Factor XI (FXI) deficiency, described as hemophilic syndrome C or plasma thromboplastin antecedent deficiency, represents 7% of all hereditary coagulation factor deficiencies [1]. This deficit has been reported in many racial groups, but occurs predominantly in the Ashkenazi Jewish population [2]. In factor VIII and IX deficiency (hemophilia A and B), bleeding tendency is related to its plasmatic level, and requires awareness of the potential for spontaneous bleeding [3]. Compared with these deficiencies, FXI deficiency rarely manifests as spontaneous bleeding. In general, patients with FXI deficiency are known to have unpredictable bleeding tendencies after surgery [1,2]. To date, only seven hemorrhagic cases related to the central neural system have been reported in FXI deficiency [4–10]. Herein, we report a case of cerebral hemorrhage in a FXI deficiency patient who was first diagnosed after surgery.

Case presentation

A 63-year-old right-handed man presented with right hemiplegia for the past hour after falling asleep and was admitted to our emergency ward. He exhibited slight chronic hypertension, but did not undergo medical treatment. The Glasgow Coma Scale (GCS) upon arrival was 14. Neurologic examination revealed restlessness and sensory aphasia in addition to right hemiplegia. Brain computed tomography (CT) scan showed a subcortical hemorrhage of the left parietal lobe (Fig. 1). CT angiography showed no obvious vascular abnormalities. Routine

blood analysis conducted just after admission indicated a prolonged activated partial thromboplastin time (APTT) of 101 s (normal range 25–40 s) and a normal prothrombin time (PT) of 104% (normal range 70–140%). A repeat blood analysis indicated the same findings. He and his family had not previously been diagnosed as having hereditary coagulation factor deficiencies, and we believed he had an acquired coagulation disorder, such as circulating anticoagulants, including antiphospholipid syndrome. After infusion of fresh-frozen plasma (FFP), his APTT improved to 47 s, but 1 h after admission, his neurological examination was impaired and the GCS fell to 11. We performed echo-guided stereotactic removal of hematoma and silicone tube insertion, focusing on less traumatic methods of clot evacuation. After the surgery, the clinical status recovered immediately. In order to drain the residual hematoma, we injected urokinase, 12 000 U in 2 ml saline, into the hematoma cavity and reopened the space 8 h after the administration. The plasmatic FXI level at admission was reported to us after surgery. The level was at 3 U/dl (i.e., 3%, normal range 75–145%) and the patient was diagnosed as having congenital FXI deficiency. During the postoperative period, we intermittently applied FFP infusion for 2 weeks. After the infusion of FFP was ceased, his APTT score reverted to around 100 s, but no rebleeding or new bleeding was observed (Fig. 1). His aphasia and right hemiplegia improved by degrees and he was discharged from our hospital 6 weeks after admission. Six months after the onset, his modified Rankin Scale grade increased to 1.

Fig. 1



Upper panel: CT images on admission demonstrated subcortical hemorrhage in the left parietal region. Lower panel: CT images obtained 6 weeks after stereotaxic evacuation of hematoma and drainage insertion.

Discussion

FXI deficiency was first described as hemophilic syndrome C or plasma thromboplastin antecedent deficiency by Rosenthal *et al.* in 1953 [11]. This deficit occurs predominantly in the Ashkenazi Jewish population, but has been reported in many other racial groups [1,2]. The inheritance of this deficiency is autosomal, affecting men and women equally. In this case, the patient and his daughter were both diagnosed as having FXI deficiency after his admission.

In factor VIII and IX deficiency, a certain proportion of patients suffer spontaneous bleeding [3]. It depends to their plasmatic level, and severe deficiency requires replacement therapy. The incidence of intracerebral hemorrhage in factor VIII and IX deficiency ranges from 2.2 to 7.8% [3]. In comparison, FXI deficiency rarely manifests as spontaneous bleeding. The deficiency is usually asymptomatic with a mild-to-moderate bleeding tendency in few patients [1,2].

Patients with FXI deficiency are known to have an unpredictable tendency to bleed after surgery. This tendency is not fully understood and is not directly

related to its plasmatic level [1,2]. In this case, coagulation tests were performed, and revealed a decrease of FXI coagulant activity of 3 U/dl. Severe FXI deficiency is defined as levels less than 15–20 U/dl, and individuals with severe deficiency have a high likelihood to develop postoperative hemorrhage [2]. Patients with FXI levels of 65–80 U/dl are classified as having partial or mild deficiency, and exhibit variable severity that does not necessarily correlate with the plasma FXI coagulant activity [1,2]. Studies have confirmed that 20–50% of patients with partial deficiency experience excessive bleeding after surgery [1].

An optimal therapeutic strategy when one suffers from unanticipated bleeding is the administration of human FXI concentrate (HFC) [7]. However, infusion of HFC should be approached with caution, because fatal thrombosis events have been reported in some cases. Siao *et al.* [7] reported the administration of HCF under strict monitoring to maintain the target concentration, which required a multidisciplinary approach. Furthermore, in some countries, including Japan, FXI concentrate is not commercially available or licensed for use. When FXI

concentrate is not available, the next best choice is FFP. Its advantage is that their use is familiar, but has a greater risk of virus infection compared with HFC and because the plasma half-life of FXI is approximately 80 h [1], considerable volume infusions are needed to maintain the FXI level for struggling patients. Fibrin glue or tranexamic acid has also been reported to be useful in preventing postoperative bleeding.

The cause of intracerebral hemorrhage (ICH) is generally classified as primary or secondary. Primary ICH, due to spontaneous rupture of damaged small vessels or amyloid angiopathy, accounts for 78–88% of all cases [3]. Secondary ICH, associated with vascular anomalies, tumors, or impaired coagulation, occurs only in a minority of patients. In this case, high blood pressure was evident upon admission. As FXI deficiency is an uncommon cause of ICH, hypertension would be the primary etiological factor. It is not certain whether deficit of FXI coagulant activity together with the occurrence of a cerebral hemorrhage leads to a potential increase in hemorrhagic stroke or possible extension of the hematoma. However, increase in hemorrhage or bleeding during surgery or the postoperative period could lead to an extremely terrible neurological outcome. Therefore, at least replacement therapy should be done and in cases in which a surgical procedure is necessary, a less invasive method should be selected.

The management of ICH remains controversial [12]. A surgical approach should be considered for a lobar clot within 1 cm of the surface to prevent any progressive neurologic deficit [13]. The three generally accepted surgical options are conventional craniotomy, stereotactic evacuation of the hematoma, which can be performed under local anesthesia, and more recently, endoscopic methods. To avoid disruption of the surrounding brain and on the assumption that there could be a coagulation disorder, we focused on less traumatic methods. We carried out echo-guided stereotactic removal of the hematoma and silicone tube insertion to allow us to inject urokinase. This led to a good outcome, but it was unclear whether this was the best, the mildest, and the most effective operative method. Generally in cases of spontaneous ICH, Kim reported that stereotactic evacuation of hematoma and drainage insertion is a simple, well tolerated, and brief procedure with a very low rebleeding rate, but that endoscopic methods and drainage insertion also provided a similar outcome [14].

This case highlights the importance of evaluation of coagulopathies in this patient who appeared to exhibit a typical hypertensive hemorrhage. Seven hemorrhagic cases have been reported related to the central neural system in FXI deficiency and most cases, except one, were diagnosed after admission. Among these seven cases, there were two cases of subarachnoid hemorrhage (SAH) [7,8], two cases of spinal hemorrhage [6,10], and

one case of cerebellar hemorrhage [4] who underwent surgical treatment. Both SAHs were due to ruptured aneurysm; one was treated using the clipping method and another the coiling method, which reportedly led to a second episode of SAH due to aneurysmal revascularization and rupture. Cerebellar hemorrhage requires drainage due to obstruction of the fourth ventricle and both spinal hemorrhages require laminectomy. Among seven cases, five cases had a good prognosis. On the contrary, two cases had a poor prognosis. This is the first reported case of a FXI deficiency patient who underwent evacuation of hematoma for ICH. When one encounters an ICH patient whose blood analysis suggests a coexisting coagulation disorder, it is useful to take minor coagulation disorders into consideration and in cases of hematoma evacuation, the stereotactic method and drainage insertion should be considered as one of the good procedures.

Acknowledgements

Conflicts of interest

There are no conflicts of interest.

References

- Bolton-Magga PH. Factor XI deficiency and its management. *Haemophilia* 2000; **6**:100–109.
- Keeling D, Tait C, Makris M. Guideline on the selection and use of therapeutic products to treat haemophilia and other hereditary bleeding disorders. A United Kingdom Haemophilia Center Doctors Organisation (UKHCDO) guideline approved by the British Committee for Standards in Haematology. *Haemophilia* 2008; **14**:671–684.
- Quinones-Hinojosa A, Gulati M, Singh V, Lawton MT. Spontaneous intracerebral hemorrhage due to coagulation disorders. *Neurosurg Focus* 2003; **15**:E3.
- Brichant S, Vokaer M, Beukinga I, De San N, Bleic SA, Kentos A, et al. Cerebellar hemorrhage due to factor XI deficiency. *Cerebrovasc Dis* 2005; **19**:138–139.
- Khealani B, Farhat Z, Mozaffar T. Factor XI deficiency-related spontaneous primary intraventricular hemorrhage. *South Med J* 2000; **93**:1017–1018.
- Mustafa MH, Bernstein RA. Spontaneous spinal epidural hematoma. Brown-Sequard syndrome, and factor XI deficiency. *Ann Intern Med* 1987; **106**:477–478.
- Siao D, Seetapah A, Ryman A, Guerin V, Mesli A, Maurette P. Optimal management of aneurysmal subarachnoid hemorrhage in a patient with known factor XI deficiency: a case report. *Clin Appl Thromb Hemost* 2008; **14**:108–111.
- Slade WR Jr, Rabiner AM. Plasma thromboplastin antecedent deficiency and subarachnoid hemorrhage. *Angiology* 1973; **24**:533–537.
- Vasileiadis I, El-Ali M, Nanas S, Koliass S, Zacharatos P, Christopoulou-Cokkinou V, et al. First diagnosis of factor XI deficiency in a patient with subarachnoid haemorrhage. *Blood Coagul Fibrinolysis* 2009; **20**:309–313.
- Wisoff JH, Rovit RL, Ho V, Leventhal H. Spontaneous hematomyelia secondary to factor XI deficiency. Case report. *J Neurosurg* 1985; **63**:293–295.
- Rosenthal RL, Dreskin OH, Rosenthal N. New hemophilia-like disease caused by deficiency of a third plasma thromboplastin factor. *Proc Soc Exp Biol Med* 1953; **82**:171–174.
- Pantazis G, Tsitsopoulos P, Mihas C, Katsiva V, Stavrianos V, Zymaris S. Early surgical treatment vs conservative management for spontaneous supratentorial intracerebral hematomas: a prospective randomized study. *Surg Neurol* 2006; **66**:492–501.
- Morgenstern LB, Hemphill JC 3rd, Anderson C, Becker K, Broderick JP, Connolly ES Jr, et al. American Heart Association Stroke Council and Council on Cardiovascular Nursing. Guidelines for the management of spontaneous intracerebral hemorrhage: a guideline for healthcare professionals from the American Heart Association/American Stroke Association. *Stroke* 2010; **41**:2108–2129.
- Kim MH, Kim EY, Song JH, Shin KM. Surgical options of hypertensive intracerebral hematoma: stereotactic endoscopic removal versus stereotactic catheter drainage. *J Korean Med Sci* 1998; **13**:533–540.