

Novel treatment (new drug/intervention; established drug/procedure in new situation)

# Neurosurgical management of L-asparaginase induced haemorrhagic stroke

Elisha Ogbodo, Chandrasekaran Kaliaperumal, Michael O'Sullivan

Department of Neurosurgery, Cork University Hospital, Cork, Ireland

**Correspondence to** Mr Chandrasekaran Kaliaperumal, ckaliaperumal@gmail.com

## Summary

The authors describe a case of L-asparaginase induced intracranial thrombosis and subsequent haemorrhage in a newly diagnosed 30-year-old man with acute lymphoblastic leukaemia who was successfully managed by surgical intervention. At presentation, he had a Glasgow Coma Score of 7/15, was aphasic and had dense right hemiplegia. Neuroimaging revealed an acute anterior left middle cerebral artery infarct with parenchymal haemorrhagic conversion, mass effect and subfalcine herniation. He subsequently underwent left frontal craniotomy and evacuation of large frontal haematoma and decompressive craniectomy for cerebral oedema. Six months postoperatively he underwent titanium cranioplasty. He had made good clinical recovery and is currently mobilising independently with mild occasional episodes of expressive dysphasia, difficulty with fine motor movement on the right side, and has remained seizure free. This is the first documented case of L-asparaginase induced haemorrhagic stroke managed by neurosurgical intervention. The authors emphasise the possible role of surgery in managing chemotherapy induced intracranial complications.

## BACKGROUND

The association between malignancy and thromboembolic disease has long been established in medical literature.<sup>1</sup> The release of procoagulant factors by tumour cells, the interaction with cells of the macrophage lineage and the subsequent release of tumour necrosis factor, interleukin-1 (IL-1) and IL-6, which are potent activators of the coagulation cascade, form the basis for this association. However, antineoplastic agents have been associated with cerebral haemorrhage, infarction and cerebral venous thrombosis. The mechanisms by which antineoplastic agents may lead to stroke include endothelium toxicity, abnormalities of coagulation factors and depletion of plasma proteins involved in coagulation and fibrinolysis. Medical management of these vascular complications have largely been described in literature.<sup>2-5</sup>

We describe a case of cerebrovascular complication arising from L-asparaginase based chemotherapy, and surgical management of the same. We emphasise the possible role of surgery along with medical management of this condition.

## CASE PRESENTATION

A 30-year-old man presented to us after an episode of collapse. At presentation, his Glasgow Coma Score was 7/15; he was aphasic and had a dense right hemiplegia. He was intubated and ventilated and transferred to the intensive care unit. He was on day 19 of induction phase I LKALL 14 protocol (daunorubicin D 1, 8, 15, 22; vincristine D1, 8, 15, 22; dexamethasone D1-5, 8-11, 15-18; polyethylene glycol-asparaginase D4, 18; and intrathecal methotrexate D14). He was a non-smoker and had no co-morbidities associated with acute lymphoblastic leukaemia (ALL). He had no predisposing factors to provoke thrombosis and was not on any medication which induces thrombosis.

There was no history of thrombotic episodes before the diagnosis of leukaemia, and he had no family history of the same.

## INVESTIGATIONS

Coagulation profile revealed an international normalised ratio within the first 2 weeks of admission ranging between 1.2 and 3.4. Prothrombin time during this period ranged between 12.9 and 34.5 s while activated partial thromboplastin time was between 22 and 33 s. He had been on prophylactic low-molecular weight (LMW) heparin before this presentation. Other laboratory investigations were within normal limits.

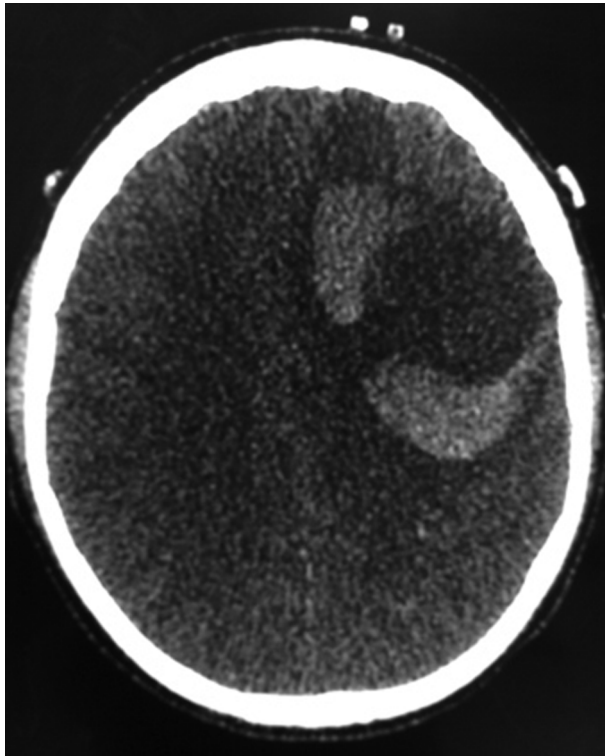
Thrombophilia screen was negative for Factor V Leiden, anticardiolipin and lupus anticoagulant. Antithrombin was slightly reduced at 65% (normal is >80), and protein S at 52%. Protein C level was normal. However, prothrombin gene analysis did not reveal any abnormality. Non-contrast CT brain (figure 1) revealed an acute anterior left middle cerebral artery infarct with parenchymal haemorrhagic conversion, mass effect and subfalcine herniation.

## DIFFERENTIAL DIAGNOSIS

- ▶ Ischaemic stroke with haemorrhagic transformation
- ▶ L-asparaginase induced thrombosis and secondary intracerebral haemorrhage.

## TREATMENT

With this background, the patient was offered surgical intervention, and he subsequently underwent left frontal craniotomy and evacuation of large frontal haematoma. Postevacuation of the haematoma there was significant cerebral oedema and because of this the decompressive craniectomy was performed in the same setting.

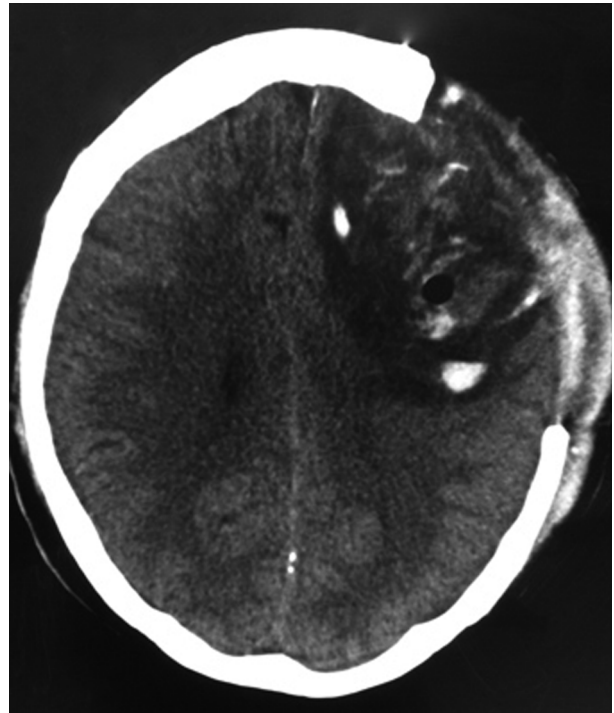


**Figure 1** CT brain demonstrating left frontal MCA territory ischaemic stroke with haemorrhagic transformation.

An intracranial pressure (ICP) monitor was inserted and was managed in the intensive care unit for 4 days postevacuation of haematoma. CT brain 2 days postsurgery demonstrated satisfactory reduction of mass effect and resolution of haematoma (figure 2). Half the usual dose of tinzaparin was administered to our patient on the morning before surgery with no additional heparin. Postoperatively, we re-introduced the prophylactic dose of LMW heparin for 6 weeks, and then increased to therapeutic dose. Our aim was to discontinue long-term anticoagulation once his mobility improved. As the ICP was well controlled at that stage, he was successfully extubated and was left with a mild right-sided hemiparesis. Few days later, he had worsening headaches, and a repeat CT brain raised the possibility of an intracranial collection suggestive of an abscess. He underwent a wound re-exploration and aspiration of residual haematoma. No evidence of infection was noted from microscopic analysis of the aspirated fluid and culture and sensitivity were normal.

During the recovery phase, he also developed a left above-knee deep vein thrombosis. A Greenfield filter was inserted, and was subsequently removed in 3 weeks time, when the patient was more ambulant and was commenced on LMW heparin treatment. Both thrombotic events were considered to have been provoked by the L-asparaginase treatment. He also developed one episode of grand mal seizures for which he was commenced on sodium valproate.

He received cyclophosphamide – total body irradiation allogeneic bone marrow transplant resulting in complete remission, but this was complicated by graft-versus-host-disease, which later resolved.



**Figure 2** CT brain postdecompressive craniectomy and evacuation of the frontal haemorrhage.

#### OUTCOME AND FOLLOW-UP

Six months later, he underwent titanium cranioplasty for the cranial defect and made a significant symptomatic recovery. He is currently mobilising independently with mild occasional expressive dysphasia, difficulty with fine motor movement on the right side and has remained seizure free.

#### DISCUSSION

L-Asparaginase is a well-known component of combination chemotherapy for ALL. There is a variety of complications arising from the use of L-asparaginase including thrombotic and/or haemorrhagic ones. The majority of these thrombotic and/or haemorrhagic complications occur in the central nervous system. The incidence of this occurrence is approximately 1–2%.<sup>4</sup>

L-asparaginase hydrolyses asparagine to aspartic acid, depleting asparagine and inhibiting protein synthesis. This inhibition is thought to be the basis of its antineoplastic effect, but it also leads to the depletion of other plasma proteins including those involved in coagulation and fibrinolysis. Decreased levels of fibrinogen, factor IX, factor XI, plasminogen, antithrombin III, protein C, protein S,  $\alpha_2$ -antiplasmin, histidine-rich glycoprotein and  $\alpha_2$ -macroglobulin have been reported.<sup>5–7</sup> Deficiencies become progressively more severe with repeated doses of L-asparaginase, in protocols with two or three doses per week, and in daily regimens. L-asparaginase is also known to affect fibrinolysis. Plasma from patients during L-asparaginase therapy shows reduced inhibition of the fibrinolytic activities of plasmin, urokinase and human tissue plasminogen activator.<sup>8</sup> A change occurs in the relative concentrations of the two forms of  $\alpha_2$ -antiplasmin, with a decrease in the ratio of the plasminogen-binding form

**Table 1** Cerebrovascular complications from L-asparaginase chemotherapy

Author/Year	Age/Sex	Symptoms*	Diagnosis	Therapy	Outcome
Ganick <i>et al</i> <sup>11</sup>	6/M	MS, HA, SZ, HP	SSS thrombosis, haemorrhagic infarct	NR	Died
Priest <i>et al</i> <sup>3, 4</sup>	6/F	SZ, MS	R frontal haemorrhage, haemorrhagic infarct	None	Complete recovery
Cairo <i>et al</i> <sup>12/</sup> Priest <i>et al</i> <sup>4</sup>	2/F	SZ, HP	L frontal haemorrhage, haemorrhagic infarct	FFP, cryoprecipitate	Complete recovery
Priest <i>et al</i> <sup>4</sup>	5/M	HA, SZ, HP	L frontal haemorrhage, haemorrhagic infarct	None	Complete recovery
	NR/NR	Weakness, MS	Bilateral thalamic haemorrhages, haemorrhagic infarcts	FFP	Complete recovery
	NR/NR	HA, SZ, V, MS	R frontal and L parietal haemorrhages	FFP, cryoprecipitate	Complete recovery
	NR/NR	HA, SZ, V, MS	R parieto-occipital haemorrhage	FFP, cryoprecipitate, platelets	Complete recovery
	NR/NR	HP, MS, SZ, HA	Bilateral frontoparietal haemorrhages	FFP, cryoprecipitate	Mild hemiparesis
	NR/NR	SZ, HA, MS	L frontal haemorrhage	None	Complete recovery
	NR/NR	HA, MS, SZ, HP	R frontal haemorrhage, L iliofem venous thrombosis	FFP, craniotomy	Occipital seizure
White <i>et al</i> <sup>13</sup>	13/M	SZ, HP	R frontoparietal haemorrhage, SSS thrombosis	NR	Died
	NR/F	Confusion, memory loss	Bilateral thalamic haemorrhages	NR	Complete recovery
Urban <i>et al</i> <sup>14</sup>	10/M	HA, HP, focal SZ, aphasia	L parietal haemorrhage	None	Mild residual
	5/M	Focal SZ, HP	L parietal haemorrhage	None	Recovery
Lederman <i>et al</i> <sup>15</sup>	44/F	MS, aphasia	L intracerebral haemorrhage	Craniotomy	Nearly complete recovery
Packer <i>et al</i> <sup>16</sup>	13/NR	SZ, HP, MS	SSS thrombosis, cortical haemorrhage	NR	Died
Pui <i>et al</i> <sup>7</sup>	NR/NR	NR	R parital haemorrhagic infarct, SSS thrombosis	FFP	Died
	NR/NR	NR	L frontoparietal haemorrhagic infarct	FFP	NR
	NR/NR	NR	R basal ganglia haemorrhagic infarct	FFP	NR
Feinberg <i>et al</i> <sup>17</sup>	13/F	HA, MS, HP, CrN III	R parietal haemorrhagic infarct	Dexamethasone	Mild hemiparesis, CrN III
Index case/2011	30/M	HA, SZ, HP	L frontal haemorrhagic infarct	Craniotomy	Mild residual

\*The initial symptom is listed first.

CrN, cranial nerve palsy; FFP, fresh frozen plasma; HA, headache; HP, hemiparesis; L, left; MS, alteration in mental status; NR, not reported; R, right; SSS, superior sagittal sinus; SZ, seizure; V, vomiting.

to the non-plasminogen-binding form. A rebound effect occurs after stopping therapy.<sup>8</sup> This may lead to alteration of the free fraction of plasminogen and affect fibrinolysis. Fibrin degradation products however, do not increase during L-asparaginase therapy.<sup>6, 8</sup>

The timing of vascular events (VE) suggests a strict relation with the administration of chemotherapy. In our case, our patient's VE occurred after day 19 of chemotherapy. In the series by Weijl *et al*, the timing of the VE was similar: They reported that VEs occurred a median of 50 days after the start of chemotherapy and approximately 1 week after the last cisplatin administration.<sup>9</sup> The incidence of VEs were noted to suddenly decrease after the completion of chemotherapy.

Weijl *et al* also demonstrated that arterial and venous events share the same risk factors, and both can occur in the same patient in their study.<sup>9</sup> In our case, the patient suffered a cerebrovascular accident and a deep vein thrombosis. He also had a second transient VE after continuing the treatment. It may be of benefit to discontinue chemotherapy once a VE is detected, but this is again debatable.

A review of existing literature suggests most chemotherapy-induced stroke events have been managed either by administration of fresh frozen plasma, cryoprecipitate, platelets, anticoagulant therapy, or steroidal agents, in various combinations (table 1).

Some studies have shown that the patients with intracranial complications from L-asparaginase were managed conservatively and various degrees of outcome measures ranging from complete recovery to death have been reported.

This complication induced by L-asparaginase is considered an adverse drug reaction (ADR). Analysing L-asparaginase induced ADR according to Naranjo algorithm score<sup>10</sup> yields a score of 5, suggesting a probable relation of this drug causing the intracranial complication.

To summarise and to ascertain the temporal association of L-asparaginase with the hemorrhagic stroke, we reiterate three important aspects, which were analysed. The first point was to rule out all other possible causes which may lead to stroke including thrombophilia screen, absence of co-morbidities, smoking, medications and other factors including prolonged bed rest and recumbency.

The second point is regarding temporal relationship and pharmacological time plausibility, which was addressed. The third point is the positive dechallenge/rechallenge response. Dechallenge was demonstrated by discontinuing L-asparaginase and because of the seriousness of this adverse drug reaction, rechallenge was not attempted.

We report the first documented case of L-asparaginase-induced stroke that made good recovery after decompressive craniectomy. The place of accurate diagnostic neuroimaging, good ICP monitoring and adequate anticoagulation peri-operatively, as adjuncts to successful surgical outcomes cannot be overemphasised. We also conclude that surgical management may prove beneficial in selected group of patients with CVA from chemotherapy considering the following factors: age of the patient, type of tumour, location of the haematoma, co-morbidities and overall clinical condition of the patient. This may also improve the quality of life of patients with cancer in selected group of patients based on all the above-mentioned factors.

Learning points

- ▶ L-asparaginase induced thrombosis and stroke is known and must be anticipated when combination chemotherapy is planned.
- ▶ Naranjo algorithm score for L-asparaginase induced thrombosis and stroke suggests a probable relation of L-asparaginase causing this ADR.
- ▶ Different factors like patients age, type of tumour and location of the intracerebral hematoma, co-morbidities and overall clinical condition of the patient should be taken into account before considering surgery.
- ▶ Though neurosurgical intervention is fraught with morbidity and mortality, it should be considered an option and this may potentially improve the quality of life and outcome in patients with cancer.

**Competing interests** None.

**Patient consent** Obtained.

REFERENCES

1. **Trousseau A.** Phlegmasia alba dolens. In: *Clinique Medicale De L'hotel-Disu De Paris*. Vol. 3. Second Edition. Paris: Balliere 1865.
2. **Doll DC,** Ringenberg QS, Yarbrow JW. Vascular toxicity associated with antineoplastic agents. *J Clin Oncol* 1986;**4**:1405–17.
3. **Priest JR,** Ramsay NK, Latchaw RE, *et al.* Thrombotic and hemorrhagic strokes complicating early therapy for childhood acute lymphoblastic leukemia. *Cancer* 1980;**46**:1548–54.
4. **Priest JR,** Ramsay NK, Steinherz PG, *et al.* A syndrome of thrombosis and hemorrhage complicating L-asparaginase therapy for childhood acute lymphoblastic leukemia. *J Pediatr* 1982;**100**:984–9.
5. **Ramsay NKC,** Coccia PF, Krivit W, *et al.* The effect of L-asparaginase on plasma coagulation factors in acute lymphoblastic leukemia. *Cancer* 1977;**4**:1398–01.
6. **Priest JR,** Ramsay NK, Bennett AJ, *et al.* The effect of L-asparaginase on antithrombin, plasminogen, and plasma coagulation during therapy for acute lymphoblastic leukemia. *J Pediatr* 1982;**100**:990–5.
7. **Pui CH,** Jackson CW, Chesney C, *et al.* Sequential changes in platelet function and coagulation in leukemic children treated with L-asparaginase, prednisone, and vincristine. *J Clin Oncol* 1983;**1**:380–5.
8. **Vellenga E,** Klufft C, Mulder NH, *et al.* The influence of L-asparaginase therapy on the fibrinolytic system. *Br J Haematol* 1984;**57**:247–54.
9. **Weijl NI,** Rutten MF, Zwinderman AH, *et al.* Thromboembolic events during chemotherapy for germ cell cancer: a cohort study and review of the literature. *J Clin Oncol* 2000;**18**:2169–78.
10. **Naranjo CA,** Busto U, Sellers EM, *et al.* A method for estimating the probability of adverse drug reactions. *Clin Pharmacol Ther* 1981;**30**:239–45.
11. **Ganick DJ,** Robertson WC Jr, Viseskul C, *et al.* Dural sinus thrombosis in leukemia. *Am J Dis Child* 1978;**132**:1040–1.
12. **Cairo MS,** Lazarus K, Gilmore RL, *et al.* Intracranial hemorrhage and focal seizures secondary to use of L-asparaginase during induction therapy of acute lymphocytic leukemia. *J Pediatr* 1980;**97**:829–33.
13. **White L,** Fishman LS, Shore NA. Strokes and the neurotoxicity of L-asparaginase. *J Pediatr* 1981;**99**:168.
14. **Urban C,** Sager WD. Intracranial bleeding during therapy with L-asparaginase in childhood acute lymphocytic leukemia. *Eur J Pediatr* 1981;**137**:323–7.
15. **Lederman GS.** Stroke due to treatment with L-asparaginase in an adult. *N Engl J Med* 1982;**307**:1643.
16. **Packer RJ,** Rorke LB, Lange BJ, *et al.* Cerebrovascular accidents in children with cancer. *Pediatrics* 1985;**76**:194–201.
17. **Feinberg WM,** Swenson MR. Cerebrovascular complications of L-asparaginase therapy. *Neurology* 1988;**38**:127–33.

This pdf has been created automatically from the final edited text and images.

Copyright 2012 BMJ Publishing Group. All rights reserved. For permission to reuse any of this content visit <http://group.bmj.com/group/rights-licensing/permissions>.

BMJ Case Report Fellows may re-use this article for personal use and teaching without any further permission.

Please cite this article as follows (you will need to access the article online to obtain the date of publication).

Ogbodo E, Kaliaperumal C, O'Sullivan M. Neurosurgical management of L-asparaginase induced haemorrhagic stroke. *BMJ Case Reports* 2012; 10.1136/bcr.11.2011.5240, Published XXX

Become a Fellow of BMJ Case Reports today and you can:

- ▶ Submit as many cases as you like
- ▶ Enjoy fast sympathetic peer review and rapid publication of accepted articles
- ▶ Access all the published articles
- ▶ Re-use any of the published material for personal use and teaching without further permission

For information on Institutional Fellowships contact [consortiasales@bmjgroup.com](mailto:consortiasales@bmjgroup.com)

Visit [casereports.bmj.com](http://casereports.bmj.com) for more articles like this and to become a Fellow

Keep up to date with all published cases by signing up for an alert (all we need is your email address) <http://casereports.bmj.com/cgi/alerts/etoc>