

Unusual presentation of more common disease/injury

Calcified chronic subdural haematoma

Asifur Rahman, Moududul Haque, Paawan Bahadur Bhandari

Neurosurgery Department, Bangabandhu Sheikh Mujib Medical University, Dhaka, Bangladesh

Correspondence to Dr Asifur Rahman, bijoun14@yahoo.com

Summary

Chronic subdural haematoma (CSH) is a well-known disease entity; however, calcified CSH (CCSH) is quite rare. Here the authors report on a 65-year-old man who developed gradual left hemiparesis and had gradually deteriorating level of consciousness for 1 month. CT scan revealed a huge right-sided CCSH. He underwent surgery and the CCSH was excised totally. The patient recovered well and was able to do his daily activities by himself. Surgical treatment for CCSH results in good neurological outcome.

BACKGROUND

To the best of our knowledge this is the first reported case in our country and we report it for its rarity.

CASE PRESENTATION

A 65-year-old right-handed farmer came to us with the complaints of gradually increasing weakness of the left side of body for 1 month and gradual deterioration of level of consciousness that started with mild disorientation about 20 days back. His attendants gave history of a minor trauma to head 20 years back and also of occasional headache for last 1 year. On examination his Glasgow coma

score was 10 (E2V3M5). He had left hemiparesis (grade 3 in both upper and lower limbs).

INVESTIGATIONS

CT scan revealed a huge right fronto-temporo-parietal CCSH (figure 1). All the biochemical parameters were within normal limits except serum Na⁺ level which was low (127 meq/l).

DIFFERENTIAL DIAGNOSIS

- ▶ Calcified epidural haematoma
- ▶ Calcified subdural empyema
- ▶ Meningioma
- ▶ Calcified arachnoid cyst
- ▶ Calcified convexity dura mater with acute epidural haematoma

TREATMENT

Serum Na⁺ was corrected and alertness of the patient improved. After preparing the patient, a large fronto-temporo-parietal craniotomy was done and the huge CCSH was removed totally. The appearance was like that of a double layered packet stuffed with soft materials of varied consistency. The interface between the calcified inner membrane and the arachnoid was quite distinct, so the CCSH could be dissected out relatively easily without injuring the brain parenchyma (figure 2).

OUTCOME AND FOLLOW-UP

The postoperative period was uneventful. At discharge, 12 days after surgery, the patient was well oriented and was able to walk without support and to carry out his daily activities.

DISCUSSION

Chronic subdural haematoma (CSH) is a frequently encountered disease entity in neurosurgical practice. However, calcified and/or ossified CSH is uncommon and is very rare.¹⁻³ Incidence of organisation, calcification or ossification of CSH that is radiologically demonstrable, has been reported to be 0.3%–2.7% of all cases of CSH.³⁻⁷

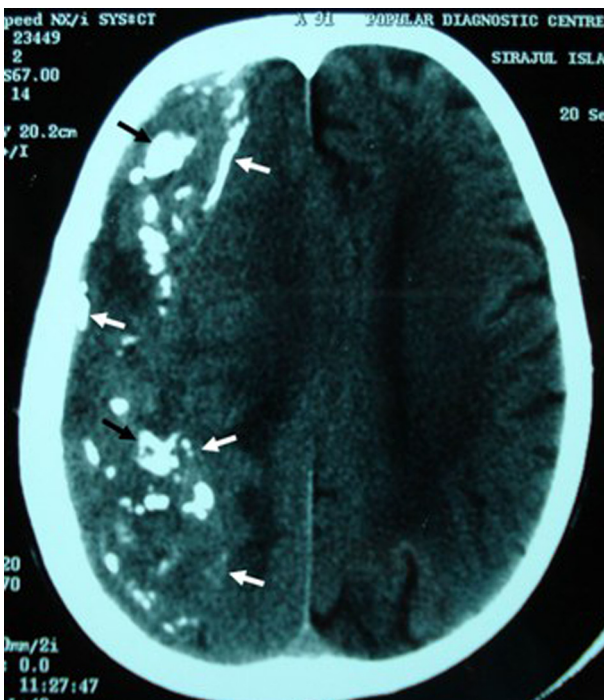


Figure 1 CT scan of head showing right fronto-temporo-parietal huge CCSH with calcification of the inner and outer membranes (white arrows) and calcification inside (black arrow).

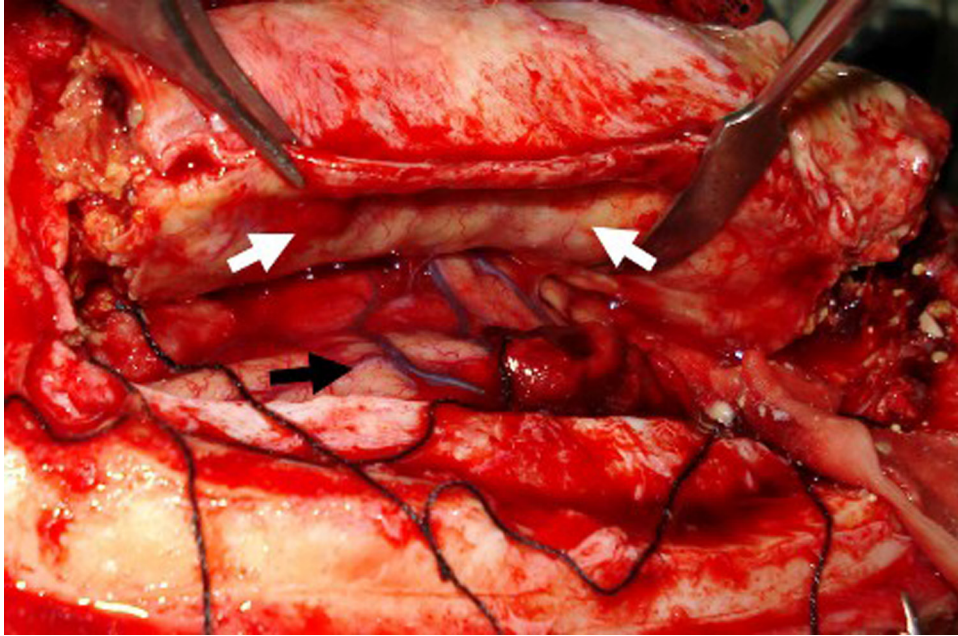


Figure 2 Per operative picture of CCSH showing that the inner membrane (white arrow) peeled off easily from the brain parenchyma (black arrow).

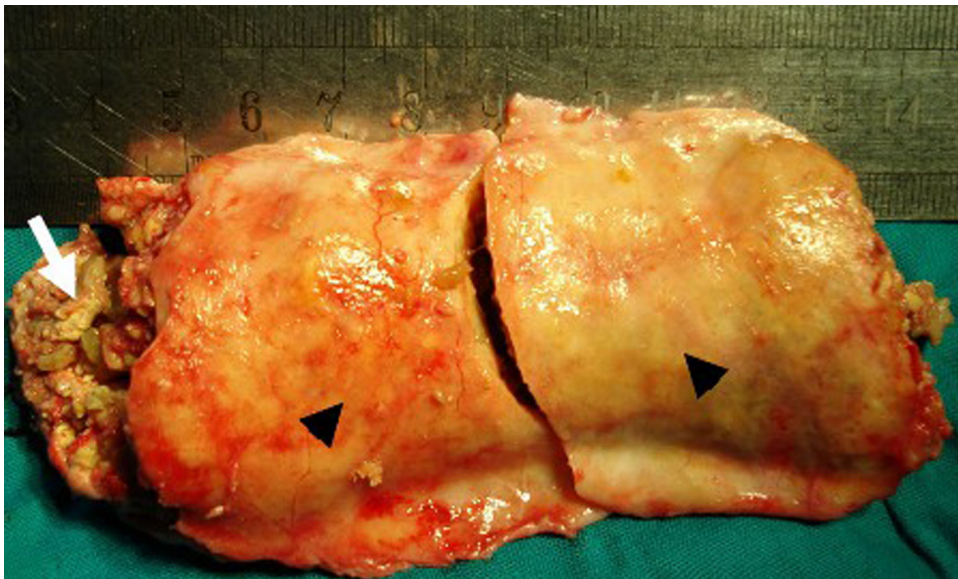


Figure 3 Cut specimen of the CCSH showing calcified membranes (black arrow heads) and calcified clay-like materials inside (white arrow).

Calcified CSH (CCSH) was first described as a finding at autopsy in 1884. The first operation on a large, calcified cystic CSH was done in 1930.^{4 6 8} An adhering calcification extending to the cerebral cortex corresponding to the inner membrane of a CSH has been termed ‘armoured brain’, especially when it covers most of the cortical surface. This name well reflect the CT, where another concentric skull, like a shell or carapace appears to be inside the cranium.^{5 7 9}

A large CCSH, on plain skull x-ray, CT and MRI, may show as an adhering calcification extending to the whole cerebral cortex, as if the skull has another concentric skull inside it. Hence it is termed ‘Armoured brain’, and

sometimes also called ‘Matrioska head’, recalling the famous Russian ‘Matrioska’ doll.^{7 9 10}

CCSH is uncommon and occurs more frequently in children and young adults than in the aged, though it has been reported in all age groups.^{3 7} Most CCSHs are located at the convexity and the extent of the calcification varies widely, sometimes involving the entire hemispheric surface. The interval between the occurrence of the haematoma and the development of the calcification varies from 6 months to many years.^{5 8} The CCSH in our patient was at the convexity as described in literatures, although he was older than most patients reported. It seems that the process took a long time as there is history

of a minor trauma 20 years back which could be the inciting factor.

Most CCSHs can be diagnosed by CT or MRI and differentiated from the usual CSH by imaging studies and gross pathology. CCSHs have the following characteristics: (1) elliptical shape with the longest diameter in the frontotemporal direction; biconvex or flat shape on cross section, (2) the content is gelatinous or clay-like, but not liquefied, (3) the inner membrane is thick and has sinusoidal blood vessels, (4) the inner membrane is partially adhered to and evaginated into the cerebral cortex.³ The present case was diagnosed preoperatively with CT findings of chronic subdural hematoma with calcified wall and peroperatively the CCSH had all the characteristics mentioned above except the inner membrane was not adhered to the brain (figure 3). CCSH is most often confused with calcified subdural empyema and intraoperative aspiration of pus is diagnostic.³ Our patient was afebrile and was in good general condition except his neurological impairments; and the operative findings confirmed the lesion to be a CCSH.

Several aetiologies for CSH have been suggested, such as minor trauma, vitamin K deficiency, coagulopathy, intracranial hypotension, chronic alcoholism, vascular malformations, and primary and metastatic tumours, subduro-peritoneal or ventriculo-peritoneal shunt and seizure.^{1 4 7} Our patient gave a history of minor trauma to head 20 years back which might be the reason of having CSH initially that later turned into CCSH with time.

The mechanism underlying the calcification remains unclear. Acute inherent metabolic tendency to calcification, prolonged existence of the haematoma in the subdural space, stagnant blood due to insufficient arterial supply and/or inadequate venous return, thick connective tissue membrane, and other local factors are considered to contribute to the development of calcification of CSH.^{1 3-5 7 8} We had no evidence to indicate any of these mechanisms contributing to the development of the CCSH in our patient, though prolonged existence of the haematoma in the subdural space could not be ruled out.

CCSHs may manifest in lethargy, confusion, amnesia, seizures, hemiparesis and gait disturbance in addition to headache as the most frequent symptom; however, some patients are asymptomatic in spite of a large haematoma.^{3 7 8} Our patient had gradually developing left hemiparesis and had gradually increasing confusion. Confusion of the patient was most likely due to electrolyte imbalance which improved after correction of the serum Na⁺ level. His hemiparesis was due to compression by the CCSH mass, which improved after removal. As it was a long standing lesion, it seems to be tolerated well without producing any

symptom so far until the brain compensation was no more effective. Whether the development of CCSH follows a regressive or progressive course is still controversial. A CCSH can be an active lesion which grows like a neoplasm. Thus, surgical intervention is favoured for a progressively enlarging CCSH that gives symptoms. Removal of the CCSH reduces the mass effect and cerebral irritation, and increases the cerebral blood flow, thus patients can improve neurologically after surgery.^{3 8} The good postoperative neurological recovery in our patient confirmed that surgery is beneficial for patients with symptomatic CCSH, especially for those who have clinical deterioration.

Learning points

- ▶ CCSH is very rare.
- ▶ A haematoma membrane may be calcified or even ossified long after the occurrence of a CSH.
- ▶ The calcified capsule of CCSH may inhibit brain expansion like armour and may cause neurological symptoms.
- ▶ CCSH can be successfully excised resulting in a good recovery.

Competing interests None.

Patient consent Obtained.

REFERENCES

1. **Kaplan M**, Akgün B, Seçer H. Ossified chronic subdural hematoma with armored brain. *Turk Neurosurg* 2008;**18**:420–4.
2. **Per H**, Gümüş H, Tucer B, et al. Calcified chronic subdural hematoma mimicking calvarial mass: a case report. *Brain Dev* 2006;**28**:607–9.
3. **Yang HZ**, Tseng SH, Chen Y, et al. Calcified chronic subdural hematoma – case report. *Tzu Chi Med J* 2004;**16**:261–5.
4. **Cho HR**, Kim Y, Sim HB, et al. An organized chronic subdural hematoma with partial calcification in a child. *J Korean Neurosurg Soc* 2005;**37**:386–8.
5. **Dammers R**, ter Laak-Poort MP, Maas AI. Neurological picture. Armoured brain: case report of a symptomatic calcified chronic subdural haematoma. *J Neurol Neurosurg Psychiatr* 2007;**78**:542–3.
6. **Imaizumi S**, Onuma T, Kameyama M, et al. Organized chronic subdural hematoma requiring craniotomy—five case reports. *Neural Med Chir (Tokyo)* 2001;**41**:19–24.
7. **Al Wohaibi M**, Russell N, Al Ferayan A. A baby with an armoured brain. *CMAJ* 2003;**169**:46–7.
8. **Park JS**, Son EI, Kim DW, et al. Calcified chronic subdural hematoma associated with intracerebral hematoma. *J Korean Neurosurg Soc* 2003;**34**:177–8.
9. **Yamada K**, Ohta T, Takatsuka H, et al. High-field magnetic resonance image of a huge calcified chronic subdural haematoma, so-called “armoured brain”. *Acta Neurochir (Wien)* 1992;**114**:151–3.
10. **Sgaramella E**, Sotgiu S, Miragliotta G, et al. “Matrioska head”. Case report of calcified chronic subdural hematoma. *J Neurosurg Sci* 2002;**46**:28–31; discussion 31.

This pdf has been created automatically from the final edited text and images.

Copyright 2012 BMJ Publishing Group. All rights reserved. For permission to reuse any of this content visit <http://group.bmj.com/group/rights-licensing/permissions>.
BMJ Case Report Fellows may re-use this article for personal use and teaching without any further permission.

Please cite this article as follows (you will need to access the article online to obtain the date of publication).

Rahman A, Haque M, Bhandari PB. Calcified chronic subdural haematoma. *BMJ Case Reports* 2012;10.1136/bcr.01.2012.5499, Published XXX

Become a Fellow of BMJ Case Reports today and you can:

- ▶ Submit as many cases as you like
- ▶ Enjoy fast sympathetic peer review and rapid publication of accepted articles
- ▶ Access all the published articles
- ▶ Re-use any of the published material for personal use and teaching without further permission

For information on Institutional Fellowships contact consortiasales@bmjgroup.com

Visit casereports.bmj.com for more articles like this and to become a Fellow

Keep up to date with all published cases by signing up for an alert (all we need is your email address) <http://casereports.bmj.com/cgi/alerts/etoc>