

Case Reports

Eagle Syndrome Revisited: Cerebrovascular Complications

Tsuyoshi Todo,¹ Michael Alexander,² Colin Stokol,³ Patrick Lyden,³ Glenn Braunstein,⁴
and Bruce Gewertz,¹ Los Angeles, California

Cervical pain caused by the elongation of the styloid process (Eagle syndrome) is well known to otolaryngologists but is rarely considered by vascular surgeons. We report two patients with cerebrovascular symptoms of Eagle syndrome treated in our medical center in the past year. Case 1: an 80-year-old man with acromegaly presented with dizziness and syncope with neck rotation. The patient was noted to have bilateral elongated styloid processes impinging on the internal carotid arteries. After staged resections of the styloid processes through cervical approaches, the symptoms resolved completely. Case 2: a 57-year-old man presented with acute-onset left-sided neck pain radiating to his head immediately after a vigorous neck massage. Hospital course was complicated by a 15-minute transient ischemic attack resulting in aphasia. Angiography revealed bilateral dissections of his internal carotid arteries, with a dissecting aneurysm on the right. Both injuries were immediately adjacent to the bilateral elongated styloid processes. Despite immediate anticoagulation therapy, he experienced aphasia and right hemiparesis associated with an occlusion of his left carotid artery. He underwent emergent catheter thrombectomy and carotid stent placement, with near-complete resolution of his symptoms. Elongated styloid processes characteristic of Eagle syndrome can result in both temporary impingement and permanent injury to the extracranial carotid arteries. Although rare, Eagle syndrome should be considered in the differential diagnosis in patients with cerebrovascular symptoms, especially those induced by positional change.

In 1937, Eagle first described a set of symptoms associated with the elongation of the temporal styloid process and/or calcification of the stylohyoid or stylomandibular ligaments.^{1,2} The diagnosis implies identification of a styloid process longer

than 2.5 cm. The classical symptoms of “Eagle syndrome” include odynophagia and cervical or facial pain with neck rotation. Most commonly, patients are referred to and treated by otolaryngologists and oral and maxillofacial surgeons. In this report, we describe two patients who presented with vascular symptoms associated with styloid process elongation.

CASE REPORTS

Case 1

An 80-year-old man was referred by his primary physicians for symptoms of dizziness and multiple episodes of near syncope that had progressed in frequency and severity over the course of 2 years. The patient underwent a thorough evaluation by a neurologist for his dizziness and was diagnosed with stylo-carotid symptoms of Eagle syndrome. He was referred to vascular surgery for

¹Department of Surgery, Cedars-Sinai Medical Center, Los Angeles, CA.

²Department of Neurosurgery, Cedars-Sinai Medical Center, Los Angeles, CA.

³Department of Neurology, Cedars-Sinai Medical Center, Los Angeles, CA.

⁴Department of Medicine, Cedars-Sinai Medical Center, Los Angeles, CA.

Correspondence to: Bruce Gewertz, MD, Department of Surgery, Cedars-Sinai Medical Center, 8700 Beverly Boulevard, North Tower, Suite 8215, Los Angeles, CA 90048, USA; E-mail: bruce.gewertz@cshs.org

Ann Vasc Surg 2012; 26: 729.e1–729.e5

DOI: 10.1016/j.avsg.2011.12.005

© Annals of Vascular Surgery Inc.

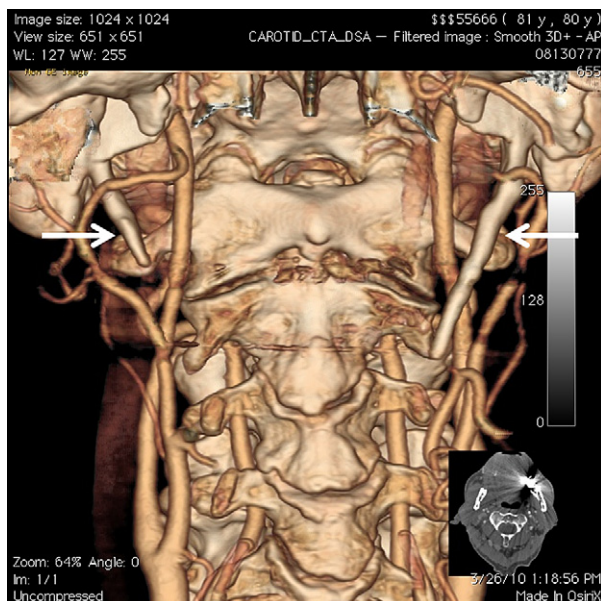


Fig. 1. Case 1. CT angiogram shows bilateral elongated styloid processes as indicated by the two arrows. Left, 5.6 cm; right, 2.5 cm.

definitive management. Medical history was significant for acromegaly treated with radiation. He denied any history of cervical trauma or focal neurological deficits. Computed tomography (CT) angiography revealed bilateral elongated styloid processes, which projected from the base of the skull (5.6 cm on the left and 2.5 cm on the right, Fig. 1). The images revealed that the distal portion of the left styloid process was in contact with the left internal carotid artery (Fig. 2). Both internal carotid arteries contained calcified plaques, which were not hemodynamically significant.

The decision was made to resect the left styloid process using a cervical approach. A 6-cm incision was made anterior to the sternocleidomastoid muscle just inferior to the angle of the mandible. Dissection exposed the carotid arteries and enabled the identification of the hypoglossal and vagus nerves. We continued the dissection cephalad until the tip of the styloid process was palpated. A periosteal elevator was used to carefully remove the attachments to the styloid process, and the bony prominence was resected just distal to the base of the skull. Care was exercised during bone transection to avoid injury to the facial nerve, which travels lateral to the base of the styloid process.

Postoperatively, the patient was followed for 5 months and reported substantial resolution of the neurologic symptoms. However, he did complain of persistent difficulty in swallowing localized to his right cervical region. Accordingly, he returned for a resection of the contralateral styloid process. Three months after the second procedure, he reported complete resolution of all symptoms.

Case 2

A 57-year-old otherwise healthy man presented to the emergency department of another hospital, complaining of transient aphasia, severe left neck pain, and unsteady

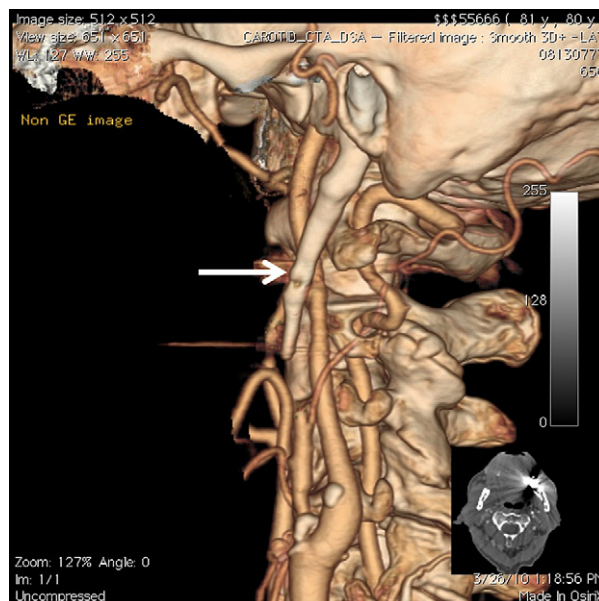


Fig. 2. Case 1. CT angiogram (*lateral view*) shows the left styloid process in contact with the internal carotid artery (arrow).

gait. The patient had received a vigorous cervical massage 1 day before the initial presentation. His diagnostic evaluation included a head CT and carotid arterial duplex ultrasonography, findings of which were unremarkable.

He subsequently presented to our institution the following day and was reevaluated. Brain magnetic resonance imaging performed the same evening revealed small left-sided frontoparietal cortical and subcortical ischemic infarcts. Magnetic resonance imaging angiography suggested possible bilateral carotid dissections. A subsequent CT angiogram performed the next day confirmed the arterial pathology and demonstrated bilateral elongated styloid processes consistent with Eagle syndrome (Fig. 3). The patient was treated with intravenous anticoagulation therapy with heparin, but he was observed to suddenly become hemiparetic (right) and aphasic the following morning. He immediately underwent endovascular thrombectomy of his occluded left carotid artery followed by balloon angioplasty and stent placement. He experienced immediate relief of his hemiparesis and substantial improvement in his aphasia.

One year after the treatment, the patient has recovered from his cerebrovascular accident, with barely detectable expressive aphasia. Follow-up angiography shows a stable dissecting aneurysm of the right internal carotid artery, with a moderately stenosed, but patent, distal left carotid artery (Fig. 4). Currently, the patient is prescribed warfarin anticoagulation, with plans to follow both the lesions prospectively with duplex scans and CT angiograms as appropriate.

DISCUSSION

The styloid process originates from the base of the skull anterior to the mastoid bone and extends

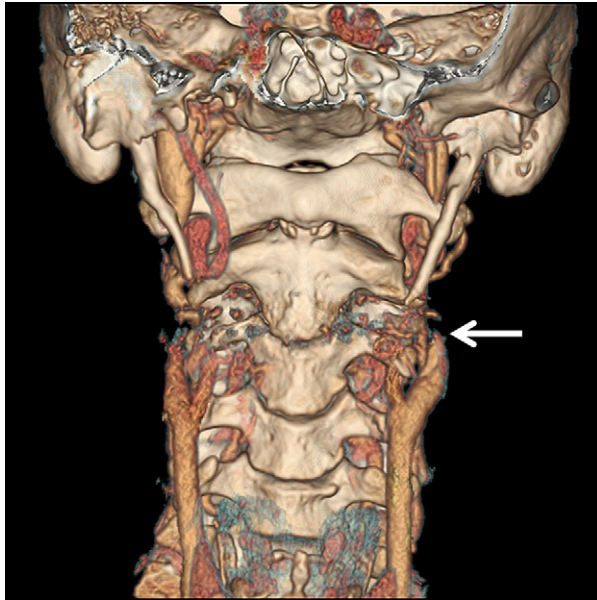


Fig. 3. Case 2. CT angiogram shows bilateral elongated styloid processes. The left styloid process is adjacent to the occluded left internal carotid artery (arrow).

inferiorly and anteriorly.³ Attachments include the stylohyoid and stylomandibular ligaments and the stylopharyngeus, styloglossus, and stylohyoid muscles. The styloid process lies close to major cervical vascular structures and to the facial and hypoglossal nerves. These structures cross between the internal and external carotid arteries as the vessels course cephalad from the carotid bifurcation. The mechanism involved in the calcification of the stylohyoid ligament is not fully understood, but has been associated with neck torsion and trauma as well as the aging process. In the presence of an abnormally elongated styloid process, neck rotation or neck compression can occlude or injure the internal carotid arteries.

In his original reports, Eagle documented a number of cerebrovascular complaints (which he called “stylocarotid symptoms”), which ranged from positional dizziness to more specific signs of cerebral ischemia. The incidence of vascular symptoms are uncommon even in patients with elongated styloid processes and other more classic cervical symptoms.⁴

The cerebrovascular manifestations of Eagle syndrome could reflect a wide range of mechanisms, including 1) cerebral ischemia from vascular compression, 2) injury to the carotid arteries with embolization or dissection, or 3) a vasovagal response. The two cases reported herein are most consistent with the first two mechanisms.

Vascular Compression

A recent report from Tubbs et al. focused on the relationship between the internal carotid artery and the stylopharyngeus muscle.⁵ The stylopharyngeus muscle originates at the medial base of the styloid process and attaches to the posteriolateral pharynx juxtaposed to the stylohyoid ligament. The authors assessed 20 cadavers and evaluated the frequency and degree of compression of the internal carotid arteries with lateral rotation of the neck. Before rotation, they noted that 13% of the internal carotid arteries were compressed by the stylopharyngeus muscle, with a degree of effacement of 30% to 50%. The degree of stenosis was increased by approximately 25% with rotation of the neck. One could hypothesize that the elongated styloid process enhances lateral support of the stylopharyngeus muscle and would potentiate vascular effacement during neck rotation.

Although such conformational changes may or may not be observed in the living state with normal distending arterial blood pressure, the relevance of these observations is supported by at least one case report of a patient with Eagle syndrome who presented with transient ischemic attack after rotation of his neck.⁶ Dynamic angiography clearly demonstrated a delay in carotid blood flow with neck rotation.

Another case report describes transient ischemic attacks associated with the compression of the internal carotid artery from mild neck trauma.⁷ The report describes an elongated styloid process of 3.5 cm, which was located close to the internal carotid artery. The patient was treated with resection of the styloid process, without complications.

The CT angiogram of our patient in case 1 depicts the proximity of the elongated styloid process to the internal carotid artery, but no vessel injury. The relief of his positional symptoms after resection of the styloid processes strongly argues for intermittent vascular compression as a mechanism. However, we cannot rule out the involvement of a vasovagal component associated with these symptoms. Regardless of the cause, surgical resection was successful in ameliorating the complaints.

Vessel Injury

Many of the case reports in the literature associate the onset of symptoms of Eagle syndrome with cervical trauma or manipulations such as chiropractic treatments or massage.⁸ Multiple case reports have documented similar injuries to the vertebral and carotid arteries as a result of such interventions and neck hyperextension.⁹ The

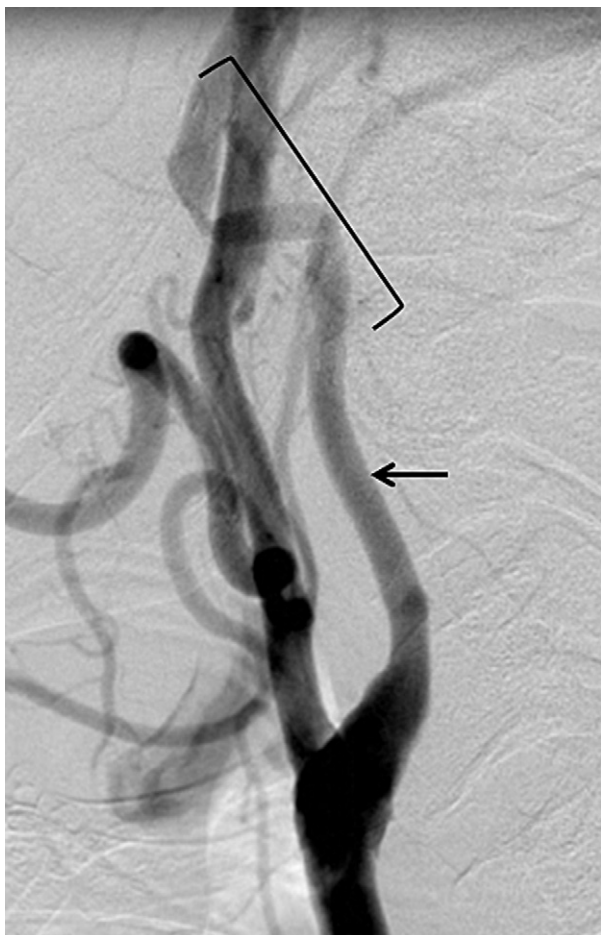

Fig. 4. Case 2. CT angiogram of the left carotid artery showing a patent left internal carotid artery after angioplasty (arrow). Bracket indicates internal carotid stent.

common mechanism is rupture of the intima, the least elastic element of the blood vessel, when vessels are stretched in proximity to a fixating bony structure.¹⁰ The patient described in case 2 underwent aggressive neck massage before presentation. It is likely that intense compression of the neck posterior to the angle of the mandible on both sides precipitated the bilateral intimal dissections where the internal carotid arteries were stretched over the bony prominence of the styloid processes.

The best approach for the long-term management of the vascular lesions in case 2 remains unclear. Certainly, the urgent revascularization and stenting of his left carotid was efficacious and necessary. The need for treatment of his dissecting aneurysm of the right internal carotid artery is less obvious. The diameter of the aneurysm remains stable, and no symptoms have appeared after the procedure. While he has recovered, it is possible that resumption of normal vigorous activity may

further injure his blood vessels. Resection of the styloid process would necessarily require exposure of the dissected portion and might precipitate expansion or even rupture. Currently, we are not planning a resection of the styloid processes unless the dilation increases.

Surgical Treatment

Treatment of Eagle syndrome requires resection of the styloid process by intraoral or extraoral approaches. The intraoral approach is performed by palpating the tonsillar fossa for the tip of the styloid process. The oral mucosa is incised longitudinally over the styloid process, the muscle attachments are carefully removed, and the styloid process is transected.¹¹ The method of exposure for the extraoral or cervical approach is similar to that of dissection for a carotid endarterectomy. When transecting the styloid process, one must avoid angulation and injury to the facial nerve, which runs lateral to the base of the styloid process.

Ceylan et al. have reported 61 cases with classical (nonvascular) symptoms successfully treated by resection of the styloid process using a cervical approach.¹² Comparing the cervical approach with the intraoral approach, De Souza Carvalho et al. report: "The extraoral approach has the advantages of providing better visualization of the operative field, so if there is any vascular lesion it is possible to resolve it without major problems."¹³

There are no prospective randomized trials comparing the two approaches. That said, it is our belief that patients with stylocarotid symptoms and presumptive vascular involvement are more safely treated with the cervical approach.

CONCLUSION

Cerebrovascular symptoms associated with styloid process elongation are an unusual presentation of Eagle syndrome. Styloid resection with a high cervical approach appears to offer the safest approach to those patients presenting with vascular compromise.

REFERENCES

1. Eagle WW. Elongated styloid process. *Arch Otolaryngol* 1937;25:584–7.
2. Eagle WW. Symptomatic elongated styloid process: report of two cases of styloid process-carotid artery syndrome with operation. *Arch Otolaryngol* 1949;49:490–503.
3. Netter F. Atlas of human anatomy. 5th Ed. Saunders, Philadelphia, Pennsylvania, 2006.
4. Piagkou M, Anagnostopoulou S, Kouladouros K, Piagkos G. Eagle's syndrome: a review of the literature. *Clin Anat* 2009;22:545–58.

5. Tubbs RS, Loukas M, Dixon J, Cohen-Gadol AA. Compression of the cervical internal carotid artery by the stylopharyngeus muscle: an anatomical study with potential clinical significance. Laboratory investigation. *J Neurosurg* 2010;113:881–4.
6. Farhat HI, Elhammady MS, Ziaee H, et al. Eagle syndrome as a cause of transient ischemic attacks. *J Neurosurg* 2009;110:90–3.
7. Infante-Cossío P, García-Perla A, González-García A, et al. Compression of the internal carotid artery due to elongated styloid process [in Spanish]. *Rev Neurol* 2004;39:339–43.
8. Blythe JN, Matthews NS, Connor S. Eagle's syndrome after fracture of the elongated styloid process. *Br J Oral Maxillofac Surg* 2009;47:233–5.
9. Hufnagel A, Hammers A, Schönle PW, et al. Stroke following chiropractic manipulation of the cervical spine. *J Neurol* 1999;246:683–8.
10. Schievink WI. Spontaneous dissection of the carotid and vertebral arteries. *N Engl J Med* 2001;344:898–906.
11. Chrcanovic BR, Custódio AL, de Oliveira DR. An intraoral surgical approach to the styloid process in Eagle's syndrome. *Oral Maxillofac Surg* 2009;13:145–51.
12. Ceylan A, Köybaşıoğlu A, Çelenk F, et al. Surgical treatment of elongated styloid process: experience of 61 cases. *Skull Base* 2008;18:289–95.
13. de Souza Carvalho AC, Magro Filho O, Garcia IR Jr, et al. Intraoral approach for surgical treatment of Eagle syndrome. *Br J Oral Maxillofac Surg* 2009;47:153–4.