

## Reminder of important clinical lesson

## Spontaneous perinatal epidural haemorrhage in a newborn

Elke Kroon, Levinus A Bok, Feico Halbertsma

Pediatrics Department, Maxima Medisch Centrum Veldhoven, Veldhoven, Netherlands

Correspondence to Dr Feico Halbertsma, f.halbertsma@mmc.nl

**Summary**

A full-term neonate, born by caesarean section, presents with focal seizures. EEG and cranial ultrasound are normal. MRI of the cerebrum shows an epidural haematoma. Perinatal intracranial haemorrhage in the full-term newborn is an important cause of morbidity and mortality. Most perinatal intracranial haemorrhages are located either subdural or intracerebral, rarely epidural. Epidural haemorrhage is usually a complication of assisted delivery, however it may also occur without forcipal or vacuum extraction, as demonstrated in this case. An epidural haemorrhage should be suspected on clinical findings, even in the absence of an assisted delivery. As cranial ultrasound sonography often misses epidural haemorrhage due to parietal location of the haemorrhage, the diagnosis needs either cerebral CT or MRI.

**BACKGROUND**

Intracranial haemorrhage in the full-term neonate is an important cause of morbidity and mortality. Although the prevalence is low, it should be included in the differential diagnosis of perinatal neurologic morbidity, because early diagnosis can be lifesaving. Symptoms at presentation, such as seizures, anaemia, apnoea and bradycardia, are non-specific.<sup>1</sup>

Most perinatal intracranial haemorrhages are either subdural or intracerebral. A spontaneous perinatal epidural haemorrhage as reported in this case is seldom seen, and is especially rare in the absence of vacuum or forceps assisted delivery. Nevertheless, it should be included in the differential diagnosis of perinatal neurologic symptoms, as early recognition favours better outcome. Diagnostic investigation consisting of only ultrasound may easily miss epidural haematoma, due to its peripheral location, and should consist of also include MRI or CT to detect parietal abnormalities.

**CASE PRESENTATION**

A male full-term neonate, born after an uneventful pregnancy, was seen at the maternity ward 30 h postpartum with focal seizures of his left hand and forearm. He was born by caesarean section, after a prolonged second stage delivery of 19 h. During the caesarean section, several manipulations were necessary for the delivery of the head. The Apgar score was 4 at 1 min and 9 at 5 min. At physical examination no congenital abnormalities or malformations were seen.

**INVESTIGATIONS**

Physical examination 30 h after birth showed twitches in the patient's left hand and forearm. Neurologic and general paediatric physical examination was normal. The cerebral function monitoring (CFM) suggested a centro-parietal epileptic focus however the EEG was normal. Cranial sonography showed no abnormalities. Culture of cerebrospinal fluid was sterile, but the cerebrospinal fluid contained some erythrocytes. MRI of the cerebrum (figure 1) showed an epidural haematoma and a small arachnoidal haematoma on the right parietal side. Diffusion-weighted imaging

showed cortical highlighting on both parietal-occipital sides. Screening for haematological and metabolic disorders was negative. Phenobarbital stopped the epileptic activity.

**OUTCOME AND FOLLOW-UP**

At follow-up at 6 months of age the child had a normal neurologic development and antiepileptic medication was discontinued. Head circumference was frequently measured, and remained within normal range.

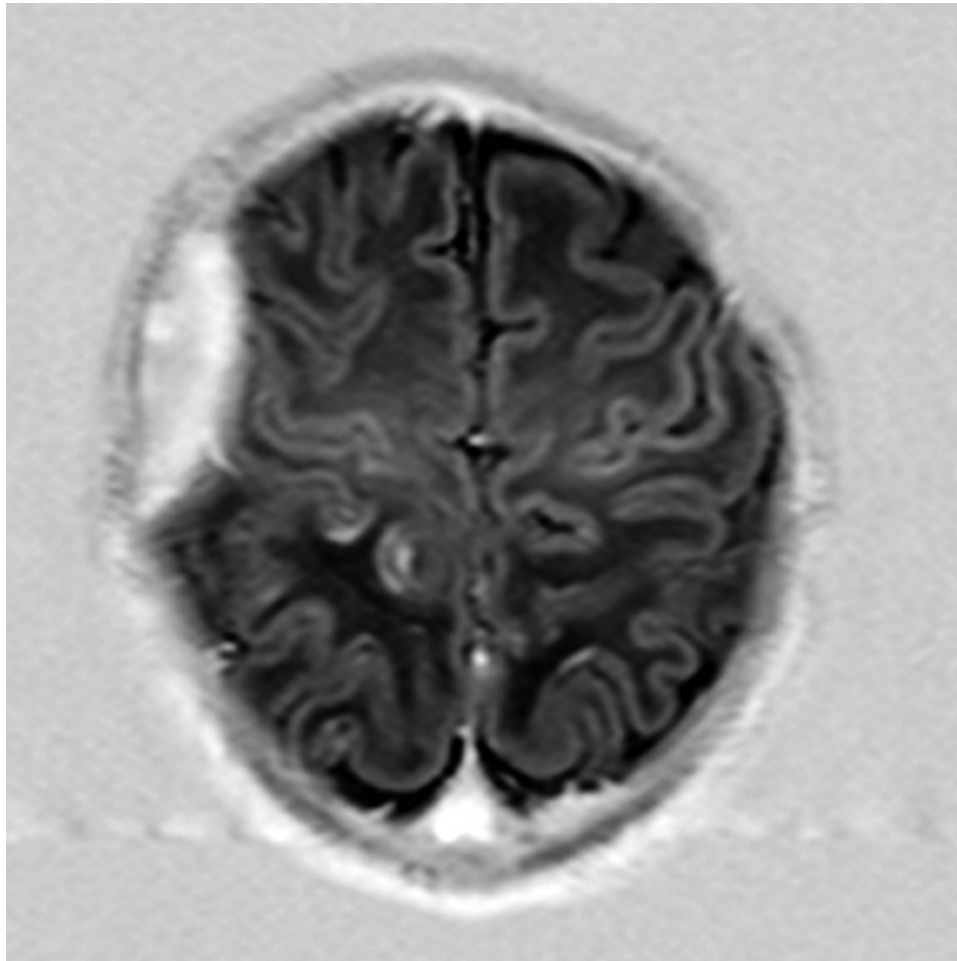
**DISCUSSION**

Neonatal epidural haemorrhage is very uncommon, but when it occurs it is often a complication of vacuum and forceps assisted delivery. Perinatal epidural haemorrhage in the absence of both vacuum/forceps assisted delivery and underlying disorders is even more rare. Previous case reports describe perinatal epidural haemorrhage in association with co-morbidities, such as Prader-Willi syndrome, Chiari malformation, haemophilia or other haemostasis disorders. Contrary to older children and adults, vascular malformations are not reported as a cause of epidural haemorrhages.<sup>1</sup>

Although cranial sonography is the initial diagnostic modality used in children suspected of intracranial haemorrhage, it is not an appropriate tool to visualise epidural haematoma, because they are typically located in the parietal area. Therefore CT scan or MRI of the cerebrum are more appropriate; where CT has the advantage of not needing anaesthesia/sedation contrary to MRI, the latter provides more detailed information about the brain tissue and structural changes.<sup>1</sup>

Epileptic activity can be diagnosed and monitored by both CFM and EEG although CFM may miss focal epileptic activity due to limited number of leads. Surprisingly in this case, EEG showed no abnormalities whereas CFM was positive for epileptic activity, demonstrating that occasionally also malpositioning of EEG probes can miss focal epileptic activity.

The anatomic site of an epidural haematoma – blood located between the periosteal membrane and the underlying



**Figure 1** Inversion recovery prepared turbo spin echo sequence MRI: epidural haematoma on the right parietal side.

outer dural fibrous stratum or between any skull bone and its periost – explains why this can arise during birth: to cause an epidural hematoma there must be a cleavage between bone and dura mater, which is always traumatic. The bone can be dislocated due to an increased moulding of the vault's bones during labour. Dura-bone cleavage occurs when the elasticity limits of the fetal dura mater is exceeded, usually during forceps or vacuum extraction, or incidentally during unassisted birth as in this case.<sup>2 3</sup>

As in neonates the meningeal arteries are not embedded in the skull, this allows for larger moulding without vascular rupture. This probably explains that when epidural haemorrhage occurs it is not confined to arterial rupture (as in children and adults), but can also arise from capillary or (sino)venous rupture when the fibro-vascular connection between the dura and bone becomes detached.

The presentation of neonatal epidural haemorrhage can be heterogeneous. It can present with a variety of symptoms or can be asymptomatic. The most common symptoms are pallor, a decrease of the haematocrit and an increasing head circumference. Neurological symptoms can be decreased consciousness, central apnea, hypotonia and/or seizures. In most cases symptoms develop within the first 24 h after birth.<sup>2 4</sup> Because the skull plates are not fused, classic raised intracranial pressure features due to brain shift can present late. Monitoring fontanel turgor,

head circumference, feeding behaviour and seizure frequency is vital.

When the haemorrhage results in an increased intracranial pressure, compression of brain tissue and eventually a shift of the brain, surgical evacuation is necessary. Some epidural haematomas communicate with cephalic haematomas and may respond to aspiration.<sup>5</sup> Small epidural haemorrhage usually resolve in time. Prognosis and outcome of perinatal epidural haemorrhage is generally good, when diagnosed in an early stage.

In conclusion, epidural haemorrhage is a rare complication of birth and can follow in a delivery without vacuum or forceps assistance. Diagnosis should be suspected following clinical symptoms. As cranial sonography is not an appropriate diagnostic modality due to parietal location of the haemorrhage, either CT or MRI is warranted.

#### Learning points

- ▶ Epidural haemorrhage, although very rare, should be a differential diagnosis in neonatal convulsions.
- ▶ Epidural haemorrhage can also be a complication of non-vacuum or non-forceps assisted birth.
- ▶ Cranial sonography is insufficient as diagnostic tool for detecting epidural haemorrhage.

**Acknowledgements** The authors thank Dr Walther Tjon a Ten for critically reviewing the manuscript.

**Competing interests** None.

**Patient consent** Obtained.

## REFERENCES

1. **Heyman R**, Heckly A, Magagi J, *et al*. Intracranial epidural hematoma in newborn infants: clinical study of 15 cases. *Neurosurgery* 2005;**57**:924–9; discussion 924–9.
2. **Gama CH**, Fenichel GM. Epidural hematoma of the newborn due to birth trauma. *Pediatr Neurol* 1985;**1**:52–3.
3. **Hamlat A**, Heckly A, Adn M, *et al*. Pathophysiology of intracranial epidural haematoma following birth. *Med Hypotheses* 2006;**66**:371–4.
4. **Ou-Yang MC**, Huang CB, Huang HC, *et al*. Clinical manifestations of symptomatic intracranial hemorrhage in term neonates: 18 years of experience in a medical center. *Pediatr Neonatol* 2010;**51**:208–13.
5. **Yamamoto T**, Enomoto T, Nose T. Epidural hematoma associated with cephalohematoma in a neonate—case report. *Neural Med Chir (Tokyo)* 1995;**35**:749–52.

This pdf has been created automatically from the final edited text and images.

Copyright 2012 BMJ Publishing Group. All rights reserved. For permission to reuse any of this content visit <http://group.bmj.com/group/rights-licensing/permissions>.

BMJ Case Report Fellows may re-use this article for personal use and teaching without any further permission.

Please cite this article as follows (you will need to access the article online to obtain the date of publication).

Kroon E, Bok LA, Halbertsma F. Spontaneous perinatal epidural haemorrhage in a newborn. *BMJ Case Reports* 2012;10.1136/bcr.09.2011.4735, Published XXX

Become a Fellow of BMJ Case Reports today and you can:

- ▶ Submit as many cases as you like
- ▶ Enjoy fast sympathetic peer review and rapid publication of accepted articles
- ▶ Access all the published articles
- ▶ Re-use any of the published material for personal use and teaching without further permission

For information on Institutional Fellowships contact [consortiasales@bmjgroup.com](mailto:consortiasales@bmjgroup.com)

Visit [casereports.bmj.com](http://casereports.bmj.com) for more articles like this and to become a Fellow

Keep up to date with all published cases by signing up for an alert (all we need is your email address) <http://casereports.bmj.com/cgi/alerts/etoc>