

## Rare disease

# Intracranial dural arterio-venous fistula presenting with progressive myelopathy

Ebere Sunny Ogbonnaya,<sup>1</sup> Irfan Yousaf,<sup>1</sup> Taufiq Mohammed Sattar<sup>2</sup>

<sup>1</sup>Neurosurgery Department, Cork University Hospital, Cork, Ireland;

<sup>2</sup>Neurosurgery Department, Beaumont Hospital, Dublin, Ireland

**Correspondence to** Dr Ebere Sunny Ogbonnaya, eskay0177@yahoo.com

## Summary

Spinal dural arterio-venous fistula (DAVF) is rare and usually involves the thoracic segments. The classical presentation is a slowly progressive ataxia. Clinical presentation of intracranial DAVF depends on the site of the DAVF, as well as the vessels involved. Patients may present with pulsatile tinnitus, occipital bruit, headache, dementia, visual impairment as well as neurological deterioration distant from the DAVF as a result of venous hypertension and cortical haemorrhage. The authors present a rare case of progressive myelopathy secondary to an intracranial DAVF.

## BACKGROUND

It is worthwhile to think of possible remote, intracranial cause of cervical cord 'tumour' manifesting as myelopathy when no intrinsic spinal cause is found.

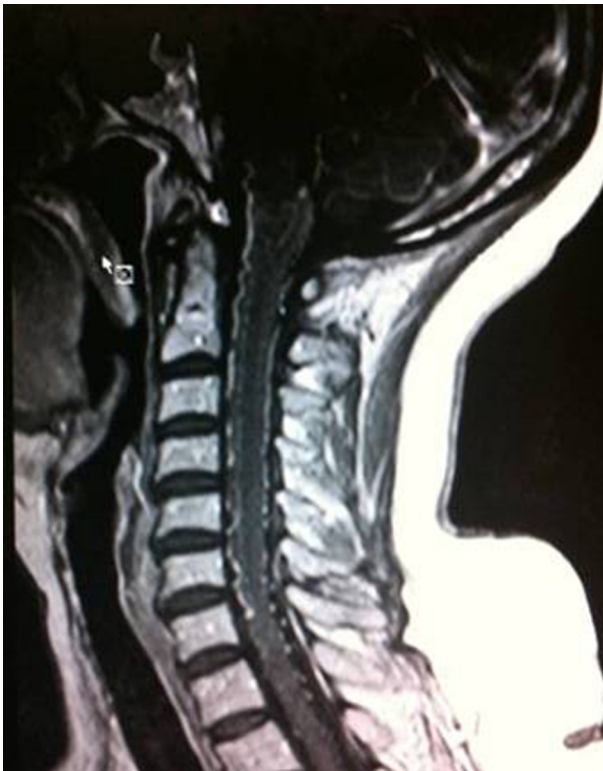## CASE PRESENTATION

A 64-year-old female presented with a 3-month history of bilateral lower limb weakness and a 2-week history of

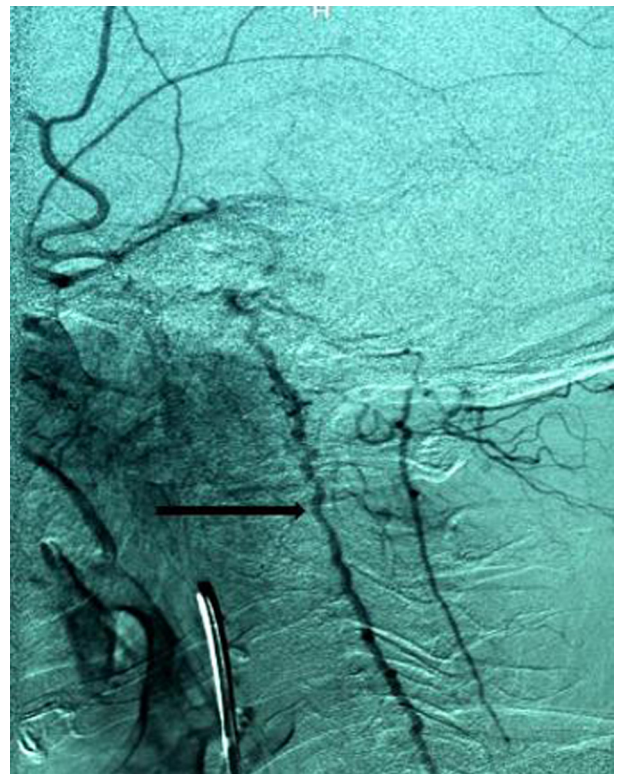
unsteady gait. Examination revealed mild ataxia with evidence of myelopathic signs in the lower limbs. Power was preserved at 4/5. Upper limb and cranial nerve examination was normal. No sensory level was noted.

## INVESTIGATIONS

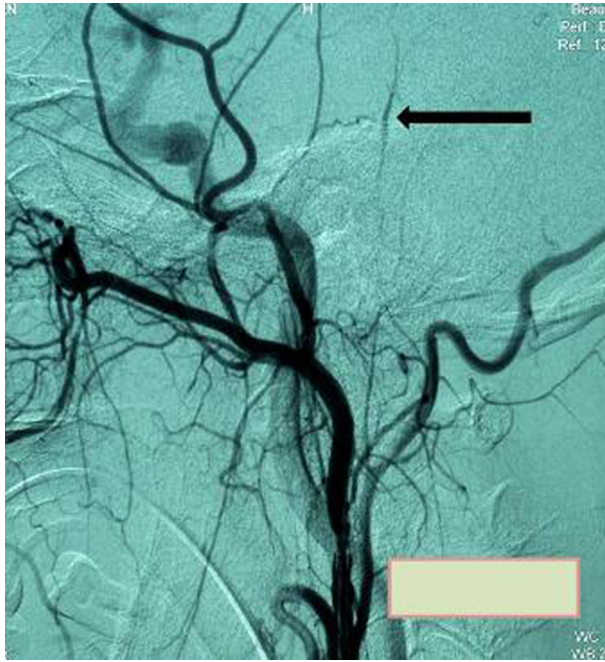MRI of the cervical spine showed extensive diffuse cervical cord swelling, as well as flow voids (figure 1). Spinal angiography confirmed dilated spinal perimedullary veins



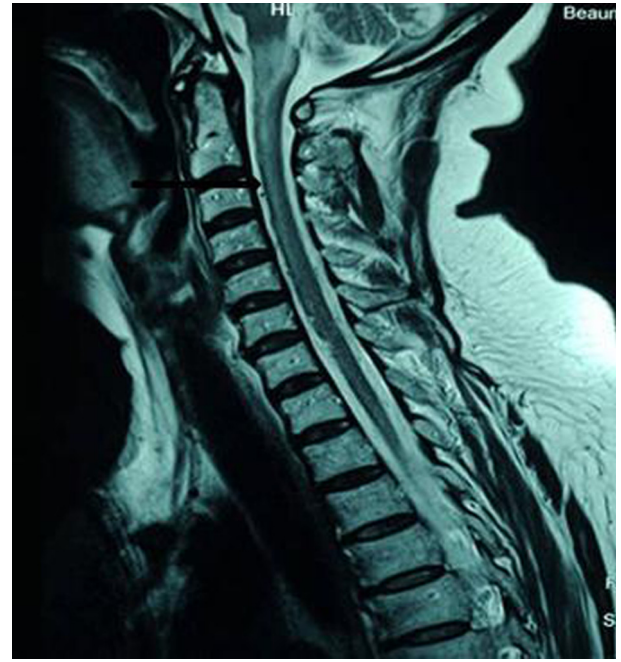
**Figure 1** MRI cervical spine showing cord swelling with vascular flow voids.



**Figure 2** Spinal angiogram showing dilated perimedullary veins.



**Figure 3** Cerebral angiogram showing dural arterio-venous fistula as shown by the arrow.



**Figure 4** MRI cervical spine showing decreased cord swelling post embolisation of dural arterio-venous fistula.

**Table 1** Cognard classification<sup>4</sup>

Type I	Normal antegrade flow into dural sinus
Type IIa	Drainage into a sinus with retrograde flow within sinus
Type IIb	Drainage into a sinus with retrograde flow to cortical veins
Type III	Direct drainage into a cortical vein without venous ectasia
Type IV	Direct drainage into a cortical vein with ectasia >5 mm and 3x larger than the diameter of the draining vein
Type V	Direct drainage into spinal perimedullary veins

(figure 2) suggestive of arterio-venous malformation (AVM) but no obvious spinal vascular malformation was demonstrated. Cerebral angiography revealed an intracranial dural arterio-venous fistula (DAVF) causing the cervical venous engorgement and cord oedema (figure 3).

### TREATMENT

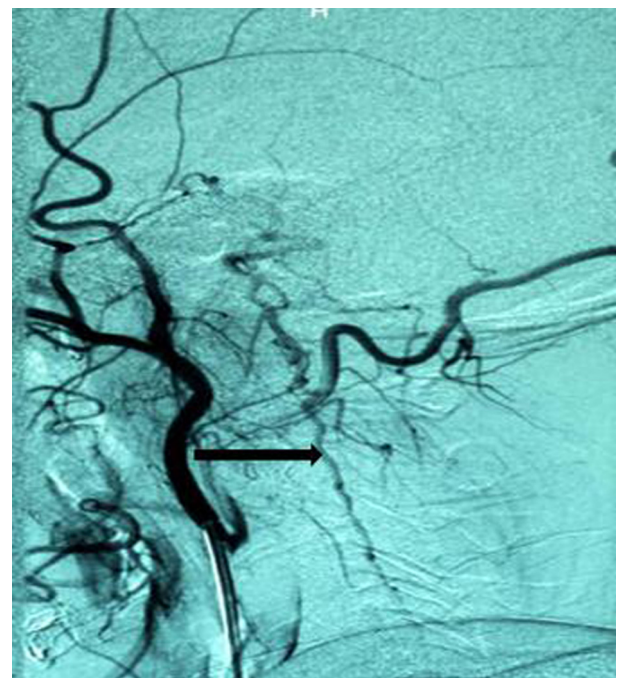
Trans-arterial embolisation of the fistula was carried out successfully.

### OUTCOME AND FOLLOW-UP

Trans-arterial embolisation of the fistula was carried out successfully. Post embolisation angiography confirmed significant reduction of the fistula as well as improvement in the dilatation of cervical cord veins (figures 4 and 5).

### DISCUSSION

AVFs are rare variety of vascular malformations characterised by single or multiple dilated arterioles that connect directly to a vein without a nidus, unlike the AVM which has interposed tangle of abnormal vessels. DAVFs account for 10–15% of all intracranial AVMs.<sup>1</sup> 61–66% occurs in females, and patients are usually in the 5th decade of life.



**Figure 5** Spinal angiogram showing decreased dilatation of the cervical perimedullary veins post embolisation of dural arterio-venous fistula (compare figures 2 and 5).

DAVFs are probably acquired since reported cases present about middle age or beyond.<sup>2</sup> The possible pathogenesis involves collateral revascularisation following thrombosis of a dural venous sinus.<sup>3</sup> They are contained within the leaflets of the dura mater, and are usually adjacent to dural venous sinuses. The transverse sinus is most commonly involved with slightly left preponderance. The severity of

adverse effects is related to the degree of venous hypertension and retrograde flow in the venous sinus and cortical veins as depicted in the classification by Borden and Cognard. The reported case is classified as Borden type III and Cognard type V.

Borden classification<sup>2</sup>

- ▶ Type I: Dural arterial supply drains antegrade into a dural venous sinus or meningeal vein. Usually benign clinical behaviour.
- ▶ Type II: Dural arterial supply drains into venous sinus. High pressure in sinus results in both antegrade and retrograde drainage via subarachnoid veins. May present with haemorrhage.
- ▶ Type III: Dural arterial supply drains retrograde into subarachnoid veins. This causes venous hypertension with risk of haemorrhage (table 1).

The aim of treatment is to interrupt or eliminate communication between the draining vein and the fistula and resolve venous congestion. Early treatment has proven to be beneficial as patients tend to improve neurologically. The first line of treatment is endovascular obliteration of the fistula. If embolisation fails, surgical interruption of the DAVF can be attempted if the site is amenable to surgical access. Stereotactic radio-surgery is also another option. This usually resolves the venous congestion of the cord occasioned by arterialisation of the anterior and posterior spinal medullary veins.

### Learning points

- ▶ DAVF is a documented cause of spinal cord 'tumour' leading to neurological deterioration as initially reported in our case.
- ▶ If spinal angiography is negative in a case of suspected DAVF, cerebral angiography is indicated to rule out intracranial DAVF connected to the spinal perimedullary venous system.
- ▶ Early interruption of DAVF permits recovery.

**Competing interests** None.

**Patient consent** Obtained.

### REFERENCES

1. **Newton TH**, Cronqvist S. Involvement of dural arteries in intracranial arteriovenous malformations. *Radiology* 1969;**93**:1071–8.
2. **Borden JA**, Wu JK, Shucart WA. A proposed classification for spinal and cranial dural arteriovenous fistulous malformations and implications for treatment. *J Neurosurg* 1995;**82**:166–79.
3. **Kwon BJ**, Han MH, Kang HS, *et al*. MR imaging findings of intracranial dural arteriovenous fistulas: relations with venous drainage patterns. *AJNR Am J Neuroradiol* 2005;**26**:2500–7.
4. **Cognard C**, Gobin YP, Pierot L, *et al*. Cerebral dural arteriovenous fistulas: clinical and angiographic correlation with a revised classification of venous drainage. *Radiology* 1995;**194**:671–80.

This pdf has been created automatically from the final edited text and images.

Copyright 2011 BMJ Publishing Group. All rights reserved. For permission to reuse any of this content visit

<http://group.bmj.com/group/rights-licensing/permissions>.

BMJ Case Report Fellows may re-use this article for personal use and teaching without any further permission.

Please cite this article as follows (you will need to access the article online to obtain the date of publication).

Ogbonnaya ES, Yousaf I, Sattar TM. Intracranial dural arterio-venous fistula presenting with progressive myelopathy.

*BMJ Case Reports* 2011;10.1136/bcr.09.2011.4828, date of publication

Become a Fellow of BMJ Case Reports today and you can:

- ▶ Submit as many cases as you like
- ▶ Enjoy fast sympathetic peer review and rapid publication of accepted articles
- ▶ Access all the published articles
- ▶ Re-use any of the published material for personal use and teaching without further permission

For information on Institutional Fellowships contact [consortiasales@bmjgroup.com](mailto:consortiasales@bmjgroup.com)

Visit [casereports.bmj.com](http://casereports.bmj.com) for more articles like this and to become a Fellow