

Reminder of important clinical lesson

Locked in and out: a case of emerging basilar artery obstruction secondary to vertebral artery dissection thrombolysed with intravenous rt-PA

Y H Al-Raweshidy, D M Sinha, L J Coward, P C Guyler, A O'Brien

Southend University Hospital, Southend, UK

Correspondence to Dr Paul C Guyler, Paul.Guyler@southend.nhs.uk

Summary

The authors present a case in which intravenous thrombolysis with recombinant tissue plasminogen activator (rt-PA) potentially saved a young man from locked-in syndrome or life threatening consequences. The patient presented with acute stroke secondary to vertebral artery dissection and was treated with intravenous rt-PA. There were no post thrombolysis complications and the patient left hospital with mild neurological symptoms. Our report suggests that in cases of acute posterior circulation stroke due to arterial dissection, treatment with intravenous thrombolysis is safe, practicable and effective.

BACKGROUND

Vertebral artery dissection accounts for 20% of all strokes in patients less than 45 years old. The majority of brain stem infarcts are due to basilar artery occlusion (BAO). Locked in syndrome is one of the most feared consequences of vertebrobasilar disease, occurring in 10–15% of all patients with BAO.¹ Patients with complete locked in syndrome are unable to move and are only able to communicate by blinking. The syndrome has been described as 'the closest thing to being buried alive'. Evidence from previous trials has shown that intravenous thrombolysis should be considered when attempting to prevent the consequences of BAO. Our case demonstrates the importance of intensive monitoring after acute stroke in order to detect deterioration and facilitate treatment with thrombolysis. It also makes the point that treatment of threatened BAO secondary to vertebral artery dissection with intravenous recombinant tissue plasminogen activator (rt-PA) is practicable in a district general hospital setting.

CASE PRESENTATION

A 44-year-old male catering manager suffered sudden onset left-sided paraesthesia, dysarthria and vertigo. He was unable to walk but managed to crawl to his wife to seek help. He arrived in accident and emergency 7 h after the onset of symptoms. During the initial assessment he mentioned that he had sustained neck strain while diving on holiday 5 weeks earlier. There had been intermittent pain at the base of the skull ever since and persistent right-sided frontal headache. Prior to admission he had attended his local medical centre and was diagnosed with musculoskeletal pain and instructed to take analgesia when required.

The patient had no vascular risk factors and there was no significant family history.

On examination blood pressure was 132/85, pulse was 65 beats/min and regular and Glasgow coma scale score

was 15/15. Neurologically, the patient was dysarthric and there was mild weakness of the left arm and leg. The weakness was worse distally in both limbs. National Institute of Health Stroke Scale (NIHSS) score was 3.²

INVESTIGATIONS

A cervical spine x-ray was requested and did not demonstrate any significant abnormality. This was shortly followed by CT of the head which showed no intracerebral haemorrhage or signs of established or early ischaemia (figure 1). The patient had MRI and magnetic resonance angiogram (MRA) which confirmed an acute brainstem infarct and a vertebral artery dissection (figures 2–4).

ECG showed sinus rhythm.

TREATMENT

A diagnosis of posterior circulation stroke was made and the patient was admitted to the acute stroke unit (ASU) for cardiovascular and neurological monitoring and was started on aspirin 75 mg and clexane 40 mg. The patient was monitored at 30 min intervals. A few hours after admission the patient's condition suddenly deteriorated and he complained of difficulty swallowing his own saliva. On examination there was gaze evoked horizontal nystagmus on looking to the right, dysarthria and deviation of the tongue to the right side on protrusion. The left-sided weakness had worsened and there was objective sensory impairment of the left arm and leg. The NIHSS score was 11. Symptoms and signs were consistent with brainstem ischaemia and treatment with intravenous thrombolysis was given promptly on ASU. There was a rapid improvement and the NIHSS score at 2 h post thrombolysis was 8 and had fallen to 6 at 24 h. The patient was given 300 mg aspirin daily after the repeat CT brain scan confirmed no haemorrhage.

OUTCOME AND FOLLOW-UP

The patient was transferred to the neurorehabilitation ward on day 4 and dipyridamole 200 mg twice daily was added to aspirin. The patient was discharged with a Modified Rankin Score of 2.³ He was seen in the outpatient clinic 6 weeks later and it was noted that he was back to playing table tennis.

DISCUSSION

Vertebral artery dissection accounts for 20% of strokes in people under the age of 45 years.⁴ Dissection can result

in ischaemic stroke either by thromboembolism or (less commonly) from haemodynamic insufficiency due to severe arterial stenosis or occlusion.⁵ The best treatment option remains uncertain, a recent Cochrane review failed to demonstrate superiority of either anticoagulation or antiplatelet therapy.⁶

The majority of brain stem infarcts are due to BAO, mostly commonly caused by atherosclerotic stenosis at the origin of the vertebral artery.⁷ Other notable causes of BAO include neck manipulation, migraine and temporal arteritis. Initial symptoms are sudden onset of headaches, dizziness, dysarthria, unilateral paresthesias or confusion.⁸ These symptoms may later be accompanied by motor deficits such as hemiplegia.

We believe this case is important for several reasons. The patient presented more than 7 h after the onset of symptoms and with only a mild neurological deficit (NIHSS 3) therefore thrombolysis was not appropriate at that stage. Studies have demonstrated that patients with dysarthria, lower cranial nerve involvement or impaired consciousness as a result of basilar artery territory ischaemia have a poor prognosis.⁹ On this basis it was felt very likely that the patient's condition may worsen and he was intensively monitored so that deterioration could be detected as soon as possible. As the best treatment of arterial dissection remains uncertain our patient received aspirin only since anticoagulation would have prevented the use of thrombolysis at a later stage.

In BAO the overall, mortality at 4 months is 90%.¹⁰ Therefore although the optimal treatment remains uncertain, most experienced stroke centres would consider thrombolysis in this situation on a patient by patient basis. BASICS (Basilar Artery International Cooperation Study) has evaluated the use of intrarterial thrombolysis, anti-thrombotics and intravenous thrombolysis in 619 patients with BAO and the results suggest that intravenous thrombolysis is more effective than antithrombotics and is not inferior to intrarterial thrombolysis.¹¹

Our stroke service is based in a district general hospital without easy access to interventional neuroradiology or

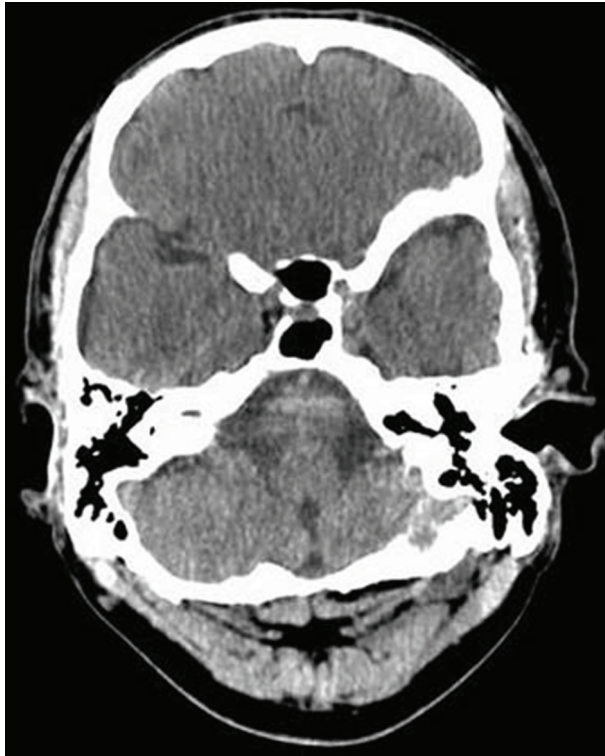


Figure 1 Admission CT – no infarct.

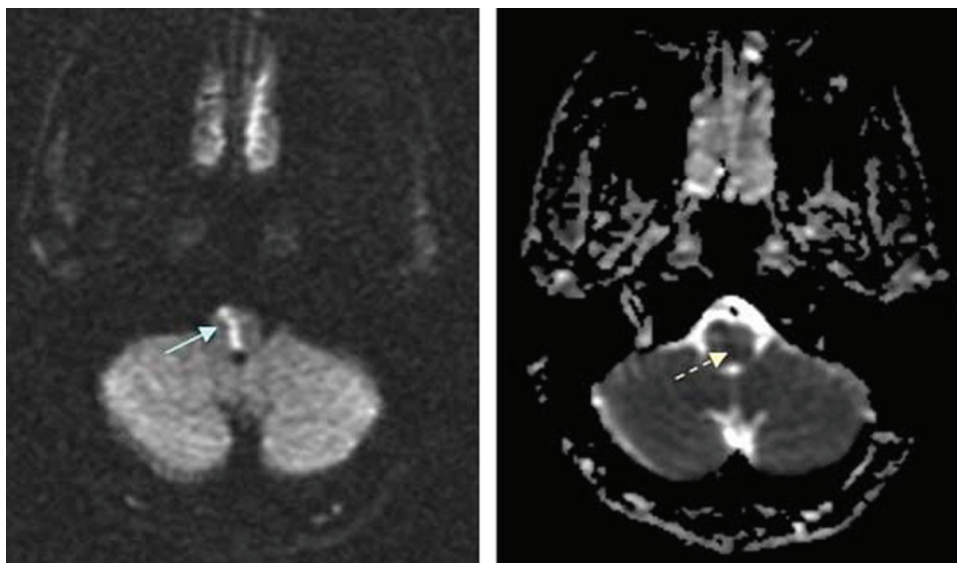


Figure 2 MRI – DWI and ADC images; solid arrow – acute brainstem infarct; dashed arrow – confirming acute infarct.

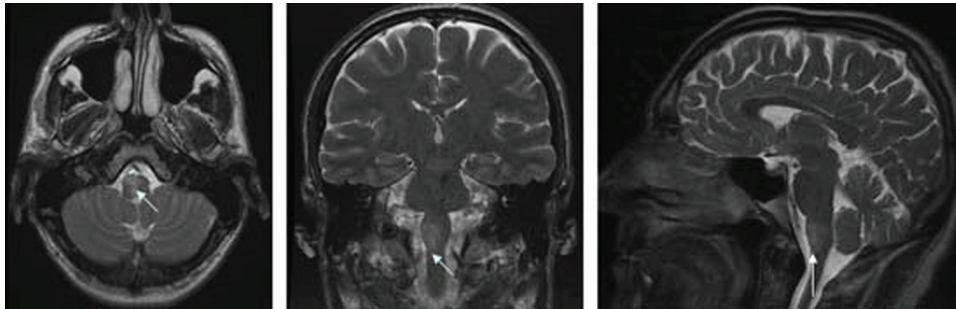


Figure 3 MRI – T2 axial, coronal and sagittal views; arrows – demonstrate the extent of the brain stem infarction.

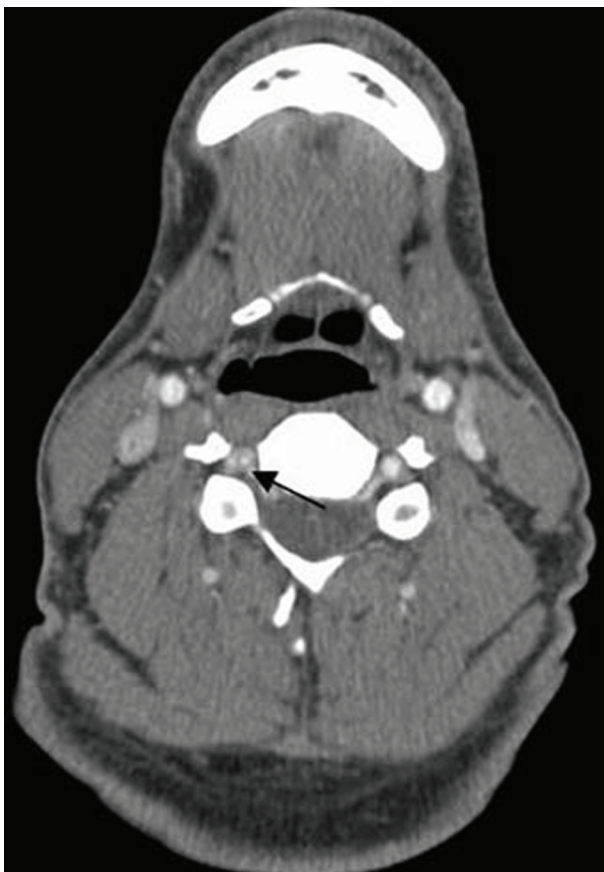

Figure 4 MRA; arrow – right vertebral artery dissection.

neurosurgery. This means that other methods of treating BAO such as delivery of intrarterial thrombolysis, arterial stenting and mechanical clot retrieval are rarely available to us. We have shown that it is possible to avoid potentially catastrophic consequences with a combination of anticipation, a highly responsive stroke unit and intravenous thrombolysis.

Our case is in line with previous studies that have demonstrated good outcomes in patients with arterial dissection who are treated with intravenous thrombolysis. One study demonstrated that >75% of thrombolysed patients had a favourable outcomes (defined as full independence or return to pre-morbid condition) at 3 months.¹² In another study of patients with vertebral artery dissection, recanalisation was demonstrated in 71%, mortality was 12% and 50% had good outcome where recanalisation occurred.¹³

sation was demonstrated in 71%, mortality was 12% and 50% had good outcome where recanalisation occurred.¹³

Learning points

- ▶ BAO is associated with high mortality.
- ▶ The main complication is locked in syndrome, a devastating condition.
- ▶ Early clinical suspicion and prompt diagnosis using MRI/MR angiography can drastically change prognosis.
- ▶ Use of intravenous thrombolysis in arterial dissection is associated with a favourable outcome.

Competing interests None.

Patient consent Obtained.

REFERENCES

1. **Idicula TT**, Joseph LN. Neurological complications and aspects of basilar artery occlusive disease. *Neurologist* 2007;**13**:363–8.
2. National Institute of Health Stroke Scale (NIHSS). <http://www.nihstrokescale.org> (accessed 26 April 2011).
3. **Bonita R**, Beaglehole R. Recovery of motor function after stroke. *Stroke* 1988;**19**:1497–500.
4. **Redekop GJ**. Extracranial carotid and vertebral artery dissection: a review. *Can J Neurol Sci* 2008;**35**:146–52.
5. **Piechowski-Józwiak B**, Bogousslavsky J. Basilar occlusive disease: the descent of the feared foe? *Arch Neurol* 2004;**61**:471–2.
6. **Sandercock P**, Mielke O, Liu M, *et al*. Anticoagulants for preventing recurrence following presumed non-cardioembolic ischaemic stroke or transient ischaemic attack. *Cochrane Database Syst Rev* 2003;**1**:CD000248.
7. **Linfaite I**, Llinas RH, Schlaug G, *et al*. Diffusion-weighted imaging and National Institutes of Health Stroke Scale in the acute phase of posterior-circulation stroke. *Arch Neurol* 2001;**58**:621–8.
8. **Kubik CS**, Adams RD. Occlusion of the basilar artery; a clinical and pathological study. *Brain* 1946;**69**:73–121.
9. **Devuyst G**, Bogousslavsky J, Meuli R, *et al*. Stroke or transient ischemic attacks with basilar artery stenosis or occlusion: clinical patterns and outcome. *Arch Neurol* 2002;**59**:567–73.
10. **Yu W**, Binder D, Foster-Barber A, *et al*. Endovascular embolectomy of acute basilar artery occlusion. *Neurology* 2003;**61**:1421–3.
11. **Schoneville WJ**, Wijman CA, Michel P, *et al*. Treatment and outcomes of acute basilar artery occlusion in the Basilar Artery International Cooperation Study (BASICS): a prospective registry study. *Lancet Neurol* 2009;**8**:724–30.
12. **Grund M**, Stenzel C, Schmülling S, *et al*. Early intravenous thrombolysis for acute ischemic stroke in a community-based approach. *Stroke* 1998;**29**:1544–9.
13. **Lindsberg PJ**, Mattle HP. Therapy of basilar artery occlusion: a systematic analysis comparing intra-arterial and intravenous thrombolysis. *Stroke* 2006;**37**:922–8.

This pdf has been created automatically from the final edited text and images.

Copyright 2011 BMJ Publishing Group. All rights reserved. For permission to reuse any of this content visit <http://group.bmj.com/group/rights-licensing/permissions>.
BMJ Case Report Fellows may re-use this article for personal use and teaching without any further permission.

Please cite this article as follows (you will need to access the article online to obtain the date of publication).

Al-Raweshidy YH, Sinha DM, Coward LJ, Guylar PC, O'Brien A. Locked in and out: a case of emerging basilar artery obstruction secondary to vertebral artery dissection thrombolysed with intravenous rt-PA. *BMJ Case Reports* 2011;10.1136/bcr.12.2010.3584, date of publication

Become a Fellow of BMJ Case Reports today and you can:

- ▶ Submit as many cases as you like
- ▶ Enjoy fast sympathetic peer review and rapid publication of accepted articles
- ▶ Access all the published articles
- ▶ Re-use any of the published material for personal use and teaching without further permission

For information on Institutional Fellowships contact consortiasales@bmjgroup.com

Visit casereports.bmj.com for more articles like this and to become a Fellow