



Case report

Prolonged atrial fibrillation following generalized tonic–clonic seizures

Rainer Surges^{a,*}, Susanna Moskau^a, Bettina Viebahn^a, Jan-Christoph Schoene-Bake^a,
Joerg O. Schwab^b, Christian E. Elger^a

^a Department of Epileptology, University of Bonn Medical Center, Sigmund-Freud-Str. 25, 53105 Bonn, Germany

^b Department of Medicine - Cardiology, University of Bonn Medical Center, Sigmund-Freud-Str. 25, 53105 Bonn, Germany

ARTICLE INFO

Article history:

Received 29 March 2012

Received in revised form 18 May 2012

Accepted 23 May 2012

Keywords:

Sudden unexpected death in epilepsy

Cardiac arrhythmia

Atrial fibrillation

Chronic epilepsy

ABSTRACT

We describe two male patients with focal epilepsy in whom transitory episodes of atrial fibrillation (AF) lasting for up to 25 h were detected in the context of generalized tonic–clonic seizures (GTCSs). In five of seven previously published cases of transitory AF associated with epileptic seizures, AF was also associated with GTCS, suggesting a pathophysiological link via GTCS-related increase in sympathetic tone and release of catecholamines. Importantly, AF increases the risk of thromboembolic cerebral ischemia, prompting the question of whether antithrombotic preventive treatment should be initiated in people with pharmacoresistant epilepsy and prolonged peri-ictal AF. Furthermore, AF can considerably impair cardiac output and may, via this mechanism, contribute to the risk of sudden unexpected death in epilepsy following GTCS.

© 2012 British Epilepsy Association. Published by Elsevier Ltd. All rights reserved.

1. Introduction

Generalized tonic–clonic seizures (GTCSs) are commonly associated with central apnea and sustained sinus tachycardia. Potentially serious cardiac arrhythmias are very rare and include sinus bradycardia, asystole and ventricular tachyarrhythmia.¹ Here, we describe two patients with prolonged atrial fibrillation (AF) detected in the context of GTCSs. We review the previously reported cases and discuss possible pathophysiological mechanisms and treatment considerations.

2. Case reports

2.1. Case 1

This is a 23-year-old left-handed man with pharmacoresistant focal epilepsy since the age of 17 manifesting with infrequent variable auras (feeling “unwell”, somewhat “dizzy” or being aware of tingling in the right or left hand) developing into secondarily GTCS (about 3 per year). Seizures had occurred from the sleeping and waking state and lasted between 2 and 3 min. Repeated routine scalp-EEG recordings were unremarkable. Cerebral MRI

(3 T) and CT scan revealed multiple micro-calcifications at the junction of grey and white matter with an emphasis in the left parietal lobe. Although these findings together with presence of oligoclonal bands in the CSF were suggestive of neurocysticercosis or a chronic inflammatory process, subsequent extensive screening for specific antibodies (including HIV) in blood and CSF were normal and have not supported this hypothesis. Typical risk factors for epilepsy were absent (no febrile seizures, no head/brain injury, no known CNS inflammation, negative family history for epilepsy) and interictal neurological and general examinations were normal.

This patient was admitted to our hospital 45 min after a GTCS. Clinical examination was normal apart from an irregular heart rhythm with a rate of around 60 beats per minute (bpm). A 12-lead electrocardiogram (ECG) confirmed the presence of AF. Video-EEG telemetry was started 24 h after the GTCS and revealed no EEG-abnormality during a 48-h recording period. During the recording period the patient was medicated with lamotrigine (LTG, 300 mg per day) and levetiracetam (LEV, 2000 mg per day). On the continuous one-lead ECG during video-EEG telemetry, AF was still present on the day after admission and spontaneously resolved about 25 h after the GTCS (Fig. 1). Blood pressure was normal (110–120/60–80 mm Hg, heart rate 60–70 bpm) during AF and did not change after the spontaneous remission of the AF. Cardiological evaluation with a transthoracic echocardiogram was normal (normal dimension of cardiac cavities without signs of atrial enlargement). The patient was given 100 mg aspirin per day and 47.5 mg metoprolol per day for some weeks. Repeated ambulatory Holter-recordings were recommended (but had not been done at last follow-up 5 months later). The LEV dose was increased to

* Corresponding author at: Department of Epileptology, University Hospital Bonn, Sigmund Freud Str. 25, 53127 Bonn, Germany. Tel.: +49 228 28714778; fax: +49 228 28719351.

E-mail addresses: rainer.surges@googlemail.com,
rainer.surges@ukb.uni-bonn.de (R. Surges).

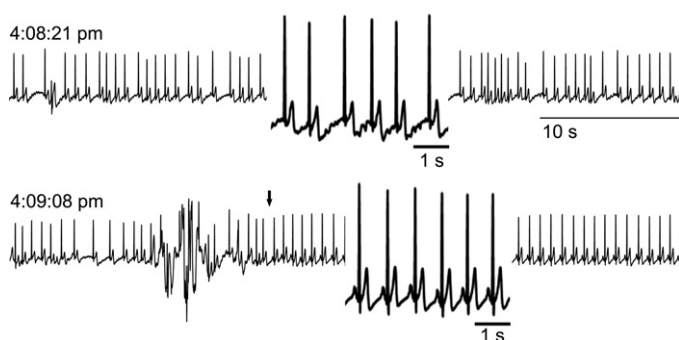


Fig. 1. Continuous one-lead ECG during video-EEG-telemetry displayed AF (upper trace and first part of the lower trace) which spontaneously remitted about 25 h after GTCS (indicated by an arrow in the lower trace). Insets: A short portion of the ECG trace during AF and after remission was magnified for easier analysis.

3000 mg per day to improve seizure control. Interestingly, three years prior to the current admission, cardiological examinations were already performed because of transitory AF with rapid heart rate in the context of a GTCS (while taking 250 mg LTG per day). All subsequent examinations including transthoracic echocardiogram, 24 h Holter-recording and exercise testing carried out at that time were normal.

2.2. Case 2

This is a 25-year-old right-handed man with pharmacoresistant focal epilepsy since the age of 7 manifesting with complex-partial seizures (staring, impaired consciousness and complex automatisms or acoustic auras and sensory aphasia). On LTG (400 mg per day), LEV (4000 mg per day) and valproate (1000 mg per day) seizures occurred in clusters with a frequency of about 3 per week and a duration of 1–2 min. In addition, the patient reported 6–12 secondarily GTCSs a year. Cerebral MRI (3 T) revealed a mesio-temporal dysembryoplastic tumor of the left hemisphere. In view of concordant electro-clinical and MRI findings, the patient underwent epilepsy surgery (resection of the anterior temporal lobe including mesio-temporal structures). At the time of his last follow-up 6 months after epilepsy surgery he was seizure-free on LTG (500 mg per day) and LEV (3000 mg per day).

Prior to epilepsy surgery, this patient had suffered from a GTCS causing a minor head injury and laceration of the scalp, prompting referral to an adjacent hospital. On admission into the intensive care unit, he presented with rapid AF which spontaneously resolved after several hours. Based on the time of seizure-onset and

arrival in the hospital, the estimated duration of AF amounted to a minimum of 3 h. Blood pressure was normal or transiently elevated (up to 170/60 mm Hg) during and after the AF episode. Additional cardiological examinations, apart from a 12-lead ECG, have not been performed. At the time of this episode, the patient was on LEV (3000 mg per day), LTG (300 mg per day) and lacosamide (LCM, 100 mg per day).

3. Discussion

Sinus tachycardia is frequently observed during or after seizures, whereas peri-ictal bradyarrhythmias including sinus bradycardia and asystole, atrioventricular conduction block and marked sinus arrhythmia are less common.^{1,2} Seizure-related AF appears to be very rare and is usually of short duration. To date, only a few episodes of AF lasting up to 2 h have been reported in people with epilepsy (Table 1). Here, we describe two patients with chronic epilepsy in whom prolonged episodes of AF lasting up to 25 h were detected in the context of GTCSs.

3.1. Study limitations

The major weakness of our cases is the fact that the onset of AF has not been recorded during continuous video-EEG telemetry, but that AF was only recognized on admission in the hospital after a GTCS at home. It is important to note that AF is clinically silent without any symptoms in about one third of people with AF.³ Thus, we cannot rule out that in our two patients AF has occurred independently of the generalized seizures. Known triggering or facilitating factors of AF such as thyroid dysfunction, excessive alcohol-consumption or other medical conditions associated with AF were not present in our patients.^{4,5} Anticonvulsant drugs may also facilitate the onset of AF. For instance LCM has recently been reported to be associated with AF in a patient with epilepsy on 600 mg LCM per day.⁶ In this patient, AF remitted on discontinuation of LCM. In our case 2, AF was detected following a GTCS while the patient was on three anticonvulsant drugs including LCM. Although LCM was used at a low dose, a causal or permissive relationship between LCM administration and onset of AF cannot be ruled out.

3.2. Pathophysiological mechanism of seizure-related AF

Seven cases of seizure-related AF have previously been reported (Table 1).^{7–11} In five of these patients, AF was detected in the

Table 1
Review of reported seizure-related episodes with AF.

Case	Sex/age	Epilepsy/origin	Seizure ^a	Anticonvulsants ^b	AF duration	Clinical signs ^c	Reference
1	F/74	JME	GTCS	n.r.	2 h ^e	n.r.	[8]
2	M/47	"Symptomatic epilepsy"	GTCS	n.r.	n.r. ^f	n.r.	[8]
3	n.r./n.r.	n.r./n.r.	GTCS	n.r.	~10 s ^e	n.r.	[9]
4	n.r./22 ^d	IGE	GTCS	n.r.	>110 s ^e	n.r.	[10]
5	n.r./34 ^d	Focal/n.r.	CPS	n.r.	55 s ^e	n.r.	[10]
6	n.r./n.r.	n.r./n.r.	n.r.	n.r.	n.r.	n.r.	[11]
7	M/45	IGE?	GTCS	None	60 ^g and 90 ^e min	n.r.	[7]
8	M/23	Focal/unknown origin	GTCS	LEV, LTG	~25 h ^e	None	Our case 1
9	M/25	Focal/DNT	GTCS	LCM, LEV, LTG	>3 h ^e	None	Our case 2

n.r., not reported.

CPS, complex-partial seizure; DNT, dysembryoplastic neuroepithelial tumor; GTCS, generalized tonic-clonic seizure; IGE, idiopathic generalized epilepsy; JME, juvenile myoclonic epilepsy; LCM, lacosamide; LEV, levetiracetam; LTG, lamotrigine.

^a Seizure type preceding detection of AF.

^b Anticonvulsant drugs at the time of AF.

^c Clinical signs related to AF.

^d Died of SUDEP.

^e Spontaneous remission.

^f Remitted upon intravenous administration of digoxin and verapamil.

^g Remitted upon intravenous administration of propafenone.

context of GTCS (one seizure type was not reported). Thus, 7 of 9 cases of seizure-related AF were recognized following GTCSs, strongly suggesting a pathophysiological link between the onset of AF and GTCS. This apparent association, however, could also be due to a selection bias for GTCS, as these patients are often immediately referred to a hospital where ECG recordings are routinely performed on admission. Nevertheless, several arguments are in favor of the hypothesis that AF was induced by GTCSs in our two patients: (i) Both patients have denied interictal symptoms suggestive of cardiac arrhythmia such as palpitations or syncope (although this is a weak point, since up to one third of people with AF have no clinical symptoms)³; (ii) both patients had no apparent cardiological disease, and interictal cardiac diagnostic work-up including cardiac Holter-monitoring in the absence of GTCS was normal; (iii) in our patient 1, AF was detected twice following GTCSs. Repeated AF after GTCS was also recently described by Vedovello et al.⁷; (iv) GTCSs are associated with a massive release of catecholamines¹²; (v) adrenergic/sympathetic stimulation is implicated in the generation of AF,^{13,14} potentially linking GTCS and occurrence of AF.

3.3. Clinical implications and treatment considerations

Paroxysmal or permanent AF is an important risk factor for thromboembolic ischemic stroke.¹⁵ Furthermore, irregular heart activity with slow or fast heart rate may impair cardiac output with consecutive clinical symptoms. Thus, increased mortality, an increased risk for stroke and potential impairment of cardiac function prompt the questions if and how transient seizure-related AF has to be treated. Medical treatment of AF basically involves antithrombotic treatment on the one hand and the control of heart rate and rhythm on the other hand.⁴ In view of the young age of our two patients and the absence of other risk factors, the stroke risk was low, so that permanent antithrombotic medication was not thought to be indicated.¹⁵ In this context, it is important to stress that antithrombotic treatment in people with frequent GTCSs and consecutive falls should be considered with caution and, in view of the increased risk of head injury and intracranial hemorrhage, may better be avoided. The management of heart rate and rhythm includes the question of whether conversion of AF into sinus rhythm is necessary and whether potential alterations of heart rate lead to symptoms. Cardiologic conversion therapy and long-term administration of drugs for rate control were not considered in our two cases, as AF reconverted spontaneously. In view of the probable pathophysiological link between GTCS, adrenergic/sympathetic hyperactivity and onset of AF, however, long-term administration of beta-blockers (which are commonly used for rate and rhythm control in people with AF) may be considered in people with pharmacoresistant epilepsy and seizure-related AF.

Our findings may also be of some importance in the context of sudden unexpected death in epilepsy (SUDEP). AF is associated with increased mortality predominantly due to complications of ischemic stroke.¹⁶ AF, however, can also cause considerable impairment of ventricular output (especially with tachycardia) even in the absence of structural heart disease.³ Therefore, peri-ictal AF may also contribute to an increased risk of SUDEP; GTCS

being a major risk factor for SUDEP.¹ Interestingly, peri-ictal AF has been observed in two patients who died of SUDEP later on (Table 1), supporting the hypothesis of a potential contribution of AF to SUDEP.¹⁰

In conclusion, transitory AF is a rare complication of GTCSs. It is unclear whether seizure-related AF requires specific treatment. The best prevention appears to be full seizure-control. Interdisciplinary care may be considered in people with chronic epilepsy, repeated episodes of prolonged peri-ictal AF and co-factors which are associated with an increased risk of thromboembolic stroke or disturbances of heart rate with consecutive complications.¹⁵

Acknowledgments

RS has received support for congress participation and speaker fees from EISAI; has a consultancy agreement with UCB; is part of PRISM – the Prevention and Risk Identification of SUDEP Mortality Consortium which is funded by the NIH (NBIH/NINDS – 1P20NS076965-01). The funding sources had no role in the design of this report, interpretation, or in the writing of the manuscript.

References

1. Surges R, Sander JW. Sudden unexpected death in epilepsy: mechanisms, prevalence, and prevention. *Current Opinion in Neurology* 2012;**25**:201–7.
2. Surges R, Scott CA, Walker MC. Peri-ictal atrioventricular conduction block in a patient with a lesion in the left insula: case report and review of the literature. *Epilepsy & Behavior* 2009;**16**:347–9.
3. Savellieva I, Camm AJ. Clinical relevance of silent atrial fibrillation: prevalence, prognosis, quality of life, and management. *Journal of Interventional Cardiac Electrophysiology* 2000;**4**:369–82.
4. European Heart Rhythm Association. European Association for Cardio-Thoracic Surgery. Camm AJ, Kirchhof P, Lip GY, Schotten U, et al. Guidelines for the management of atrial fibrillation: the Task Force for the Management of Atrial Fibrillation of the European Society of Cardiology (ESC). *European Heart Journal* 2010;**31**:2369–429.
5. Patton KK, Zacks ES, Chang JY, Shea MA, Ruskin JN, Macrae CA, et al. Clinical subtypes of lone atrial fibrillation. *Pacing and Clinical Electrophysiology* 2005;**28**:630–8.
6. DeGiorgio CM. Atrial flutter/atrial fibrillation associated with lacosamide for partial seizures. *Epilepsy & Behavior* 2010;**18**:322–4.
7. Vedovello M, Baldacci F, Nuti A, Cipriani G, Ulivi M, Vergallo A, et al. Peri-ictal prolonged atrial fibrillation after generalized seizures: description of a case and etiopathological considerations. *Epilepsy & Behavior* 2012;**23**:377–8.
8. Tigar S, Dam M. Atrial fibrillation: an overlooked complication of epileptic seizures? *Epilepsia* 1998;**39**(Suppl. 6):118.
9. Nei M, Ho RT, Sperling MR. EKG abnormalities during partial seizures in refractory epilepsy. *Epilepsia* 2000;**41**:542–8.
10. Nei M, Ho RT, Abou-Khalil BW, Drislane FW, Liporace J, Romeo A, et al. EEG and ECG in sudden unexplained death in epilepsy. *Epilepsia* 2004;**45**:338–45.
11. Britton JW, Ghearing GR, Benarroch EE, Cascino GD. The ictal bradycardia syndrome: localization and lateralization. *Epilepsia* 2006;**47**:737–44.
12. Simon RP, Aminoff MJ, Benowitz NL. Changes in plasma catecholamines after tonic-clonic seizures. *Neurology* 1984;**34**:255–7.
13. Volders PG. Novel insights into the role of the sympathetic nervous system in cardiac arrhythmogenesis. *Heart Rhythm* 2010;**7**:1900–6.
14. Workman AJ. Cardiac adrenergic control atrial fibrillation. *Naunyn-Schmiedeberg's Archives of Pharmacology* 2010;**381**:235–49.
15. Comparison of 12 risk stratification schemes to predict stroke in patients with nonvalvular atrial fibrillation. Stroke Risk in Atrial Fibrillation Working Group. *Stroke* 2008;**39**:1901–10.
16. Benjamin EJ, Wolf PA, D'Agostino RB, Silbershatz H, Kannel WB, Levy D. Impact of atrial fibrillation on the risk of death: the Framingham Heart Study. *Circulation* 1998;**98**:946–52.