

Unusual association of diseases/symptoms

A virulent vasculopathy

A Molloy,¹ D Forde,¹ C De Gascun,² N Fanning,¹ G Wyse,¹ O O'Toole¹

¹Department of Neurology, Cork University Hospital, Cork, Ireland;
²NVRL, University College Dublin, Dublin, Ireland

Correspondence to Dr Anna Molloy, annamolusa@gmail.com

Summary

Arteriopathy is an uncommon complication of primary varicella zoster virus (VZV) infection in the immunocompetent adult. We report a case of a 39-year-old woman known to be VZV negative prior to the event. She presented to the emergency department having experienced an episode of expressive aphasia and right upper limb paraesthesia lasting 15 min. The symptoms followed a 3-day period of general malaise, arthralgia and a generalised maculopapular itchy rash involving face and limbs. No immunocompromise was detected but an infectious contact was identified in the home. Imaging findings were consistent with a focal cerebritis/vasculopathy and VZV infection was confirmed with cerebrospinal fluid PCR analysis. Resolution of radiological signs occurred following prompt treatment with appropriate antivirals.

BACKGROUND

Varicella zoster is known to cause an acute productive viral infection of cerebral arteries in children resulting in ischaemic infarction, transient ischaemic attack (TIA), subarachnoid haemorrhage, vessel dissection or cerebral haemorrhage. Adult onset varicella vasculopathy is a much rarer occurrence but is also recognised particularly in the setting of immunocompromise and reactivation of the virus. Primary adult varicella infection is rare in the healthy adult population but is important to recognise and treat appropriately thereby avoiding unnecessary long-term medication. The presenting symptoms in this case were similar to those of a TIA. Imaging findings can appear similar to a primary central nervous system (CNS) neoplasm, as in this case, but the diagnosis of CNS varicella infection was confirmed by cerebrospinal fluid (CSF) analysis and serial MRI evaluation avoiding long-term aspirin treatment.

CASE PRESENTATION

A 39-year-old right-handed woman presented complaining of an acute onset of an expressive speech disturbance associated with right upper limb paraesthesia. The symptoms lasted 15 min and then resolved. In addition, the patient described a mild left-sided headache.

Three days beforehand she had developed a widespread maculopapular itchy rash affecting her face, trunk and limbs. This was associated with general malaise and arthralgia. Her child had contracted acute varicella from another child in the crèche 1 week prior to onset of her symptoms. The patient herself did not recall ever having had varicella. She had no known vascular or stroke risk factors.

Her past medical history was notable for a diagnosis of coeliac disease. There was no family history of early stroke. She was active, a non-smoker and did not consume alcohol. She lived at home with her husband and child and was a housewife by profession.

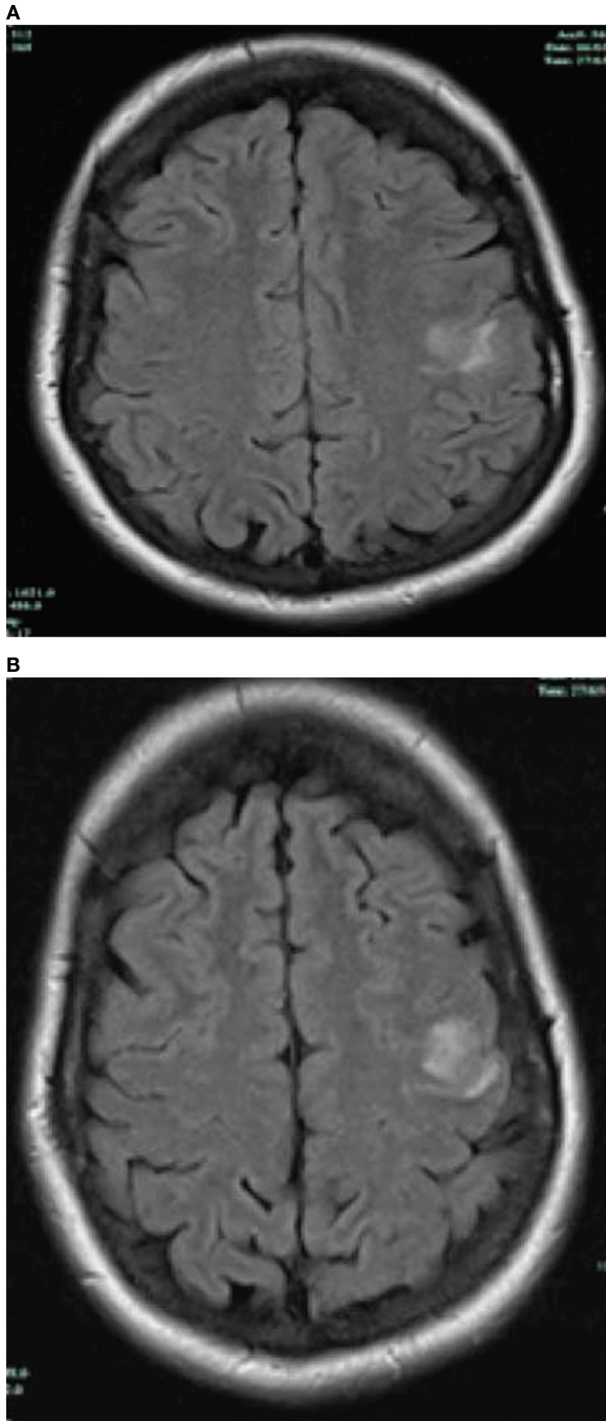
On examination she was alert and orientated with a diffuse maculopapular and pustular rash consistent with varicella zoster. Cranial nerve examination revealed no deficits. Speech was normal, there was no residual evidence of dysarthria or aphasia. She had normal tone and power throughout all four limbs. Pinprick sensation was reduced in a C5 distribution on the right upper limb but sensation was otherwise intact. Coordination was normal in all four limbs. She had an absent right triceps reflex; other reflexes were symmetrically present and plantars were down going. Gait was normal.

INVESTIGATIONS

Full blood count was normal. C reactive protein was elevated at 96. Urea, electrolytes and liver function tests were all within normal limits. ECG and echocardiogram were normal. Chest x-ray was clear. Her MR angiography (MRA) scan of intracerebral and carotid circulation revealed no angiographic features suggestive of stenosis, dissection, aneurysm or vasculitis; however, her MRI scan revealed a well-circumscribed lesion involving left pre and post central gyri (figure 1A). It was hyperintense on T2W sequences, including fluid attenuated inversion recovery (FLAIR) (figure 1B), hypointense on T1W sequences, diffusion weighted examination was normal but gadolinium enhancement was evident (figure 2). MRI C-spine was normal. CSF analysis showed 6 white cells, 100 red cells and protein of 434 (200–400 mg/l). Glucose was 3.6 mmol/l. Culture revealed no growth. CSF varicella PCR was positive. Prior antenatal bloods confirmed that the patients' serum was varicella-zoster virus (VZV) IgG negative 4 years previously.

DIFFERENTIAL DIAGNOSIS

Initial differential diagnosis included transient ischaemic attack/stroke, seizure, a CNS autoimmune or infectious vasculopathy/systemic vasculitis with CNS involve-



Figures 1 (A, B) MRI fluid attenuated inversion recovery (FLAIR) images at diagnosis showing well-circumscribed ovoid lesion left pre- and post-central gyri. Lesion present at grey/white matter junction.

ment and primary CNS neoplasm (based on the imaging appearances).

TREATMENT

The patient received a 14-day course of intravenous acyclovir 10 mg/kg three times a day. Because she presented at over 5 days post-symptom, onset steroids were not given.

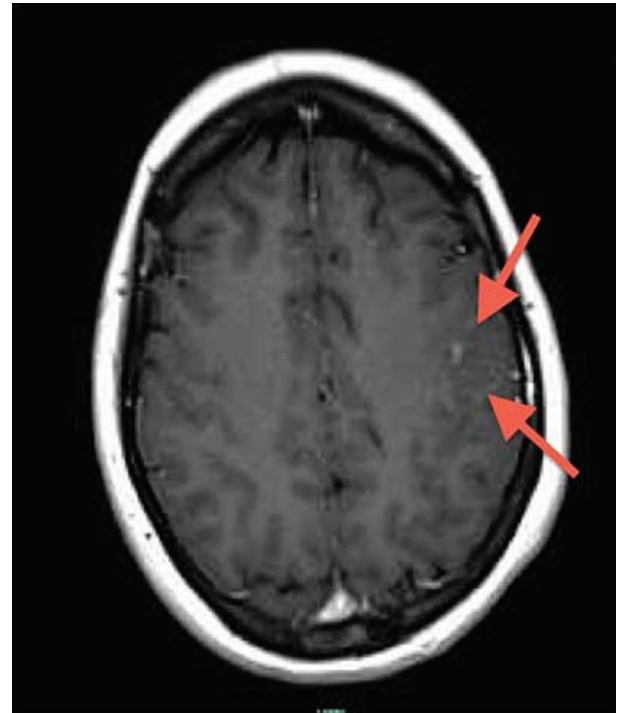


Figure 2 T1W+gadolinium image showing enhancement with contrast.

Her rash, malaise and arthralgia resolved with no recurrence of her symptoms.

OUTCOME AND FOLLOW-UP

Repeat MRI scans were performed at 2 weeks and again at 2 months following her initial admission. The abnormality described above had almost completely resolved by the 2 month scan.

DISCUSSION

This case describes a TIA-like presentation of primary varicella angiopathy in an immunocompetent adult with no relevant past medical history of note.

Varicella vasculopathy was first described over 50 years ago by Cravioto and Feigin.¹ It is known to occur in immunocompetent individuals as well as the immunocompromised, particularly in children. It may occur as a complication of either primary varicella or reactivation of the virus (shingles). The majority of adults suffer complications related to reactivation.

The exact incidence of zoster vasculopathy is not known though it is more common in the immunocompromised (transplant recipients, AIDS patients, patients on immunosuppressant medications, cancer patients, the elderly).

Primary varicella generally occurs in children and years later may reactivate as zoster more frequently in the high risk groups mentioned above. Vasculopathy secondary to VZV is a common cause of stroke in children. When stroke occurred in children it was found that VZV had preceded the event in 44% of those with transient arteriopathy of the cerebral circulation.²

In this case, we describe an acute adult varicella infection with a rash preceding CNS symptoms by a number of days. Rash may be absent in up to 37% of cases.³

Although the early case reports described cases presenting with stroke, many patients have TIAs but symptoms and signs can be prolonged. Features associated with the diagnosis include confusion, headache, aphasia, hemiplegia, sensory loss, headache and visual loss (monocular, hemianopia). In children there may be an interval of up to a number of months between infection and symptom onset.⁴ Rarer associations include cranial neuropathies, vascular dissection, aneurysm, haemorrhage (subarachnoid or intracerebral). VZV vasculopathy frequently co-exists with meningitis, myelitis or radiculitis.⁵ The question of the existence of primary VZV encephalitis has been raised.⁸ It has been deemed to be a great deal less common than vasculopathy. In our patient an encephalitis related to varicella infection was unlikely given the absence of pleocytosis on CSF sampling and lack of alteration in mental status.

We describe a case with MRI findings suggestive of unifocal involvement, the location of which was cortical, at the grey/white matter junction. In almost all cases documented to date, MRI has shown an abnormality. Lesions at the grey-white matter junction are typical but abnormalities can be deep cortical in location, involving white/grey matter.⁶ Some lesions may enhance with contrast. MRA in this case was unrevealing, which is common because the disease often favours smaller vessels though any size may be affected. Cerebral angiography is the gold standard investigation but was not performed in our case because the patient had improved. Angiographic features may show segmental constriction with post-stenotic dilatation. Seventy per cent of cases who were investigated had an abnormal angiogram in the largest case series to date.³ Disease in small arteries is not so readily detectable.

In over two-thirds of cases, a modest pleocytosis is evident³ though our patient had only a six white cell count present. An elevated red cell count is common in VZV vasculopathy as was seen in our patient. Our CSF protein was mildly elevated, as is common, and the glucose was normal. Oligoclonal bands were not done in this case but are commonly present in CSF in these cases.

VZV PCR was positive in both serum and CSF in this case, which is highly indicative of an acute infection. Based on the literature to date, greater numbers of patients tend to be VZV IgG positive in CSF than positive for VZV DNA on PCR in CSF specimens.⁷ Therefore, a negative VZV PCR does not preclude the diagnosis; only negative antibody and PCR together are reliable for exclusion of this differential.

From a treatment perspective, the largest study to date involves only 30 patients. The authors recommend a 14-day

course of intravenous acyclovir +/- steroid if the disease is diagnosed within 5 days of onset of varicella symptoms. This is not evidence based; in order to adequately determine optimal duration of antiviral treatment and benefit of concurrent steroid treatment prospective studies are required.³ It is accepted that a minimum of aciclovir 10 mg/kg three times a day intravenously is appropriate.⁸ It is not yet clear how new antivirals such as valaciclovir will fit into the treatment regime. Aspirin is not recommended because there is a potential risk of mycotic aneurysm and haemorrhage.

Learning points

- ▶ In a transient ischaemic attack/stroke associated with recent VZV infection, VZV vasculopathy should be considered.
- ▶ A prior history of VZV does not preclude the diagnosis neither does the absence of a typical rash.
- ▶ Both small and large blood vessels may be involved producing unifocal or multifocal disease with lesions at grey/white matter junction on MRI. Lesions on MRI may enhance with gadolinium. MR angiography can be normal.
- ▶ Cerebrospinal fluid VZV PCR or positive cerebrospinal fluid VZV IgG is required to make the diagnosis.
- ▶ Treatment is antivirals +/- steroids. Aspirin is not required.

Competing interests None.

Patient consent Obtained.

REFERENCES

1. **Cravioto H**, Feigin I. Noninfectious granulomatous angitis with a predilection for the nervous system. *Neurology* 1959;**9**:599–609.
2. **Braun KPJ**, Bulder MMM, Chabrier S, *et al*. The course and outcome of unilateral intracranial arteriopathy in 79 children with ischaemic stroke. *Brain* 2009;**132**:544–57.
3. **Nagel MA**, Cohrs RJ, Mahalingam R, *et al*. The varicella zoster virus vasculopathies: clinical, CSF, imaging, and virologic features. *Neurology* 2008;**70**:853–60.
4. **Gilden DH**, Lipton HL, Wolf JS, *et al*. Two patients with unusual forms of varicella-zoster virus vasculopathy. *N Engl J Med* 2002;**347**:1500–3.
5. **Miyazaki Y**, Riku Y, Goto Y, *et al*. VZV vasculopathy associated with myelo-radiculoganglio-meningo-encephalitis: an autopsy case of an immunocompetent 66-year-old male. *J Neurol Sci* 2008;**275**:42–5.
6. **Gilden DH**, Mahalingam R, Cohrs RJ, *et al*. The protean manifestations of varicella-zoster virus vasculopathy. *J Neuroviral* 2002;**8**(Suppl 2):75–9.
7. **Nagel MA**, Forghani B, Mahalingam R, *et al*. The value of detecting anti-VZV IgG antibody in CSF to diagnose VZV vasculopathy. *Neurology* 2007;**68**:1069–73.
8. **Gilden D**, Cohrs RJ, Mahalingam R, *et al*. Varicella zoster virus vasculopathies: diverse clinical manifestations, laboratory features, pathogenesis, and treatment. *Lancet Neurol* 2009;**8**:731–40.

This pdf has been created automatically from the final edited text and images.

Copyright 2011 BMJ Publishing Group. All rights reserved. For permission to reuse any of this content visit <http://group.bmj.com/group/rights-licensing/permissions>.
BMJ Case Report Fellows may re-use this article for personal use and teaching without any further permission.

Please cite this article as follows (you will need to access the article online to obtain the date of publication).

Molloy A, Forde D, De Gascun C, Fanning N, Wyse G, O'Toole O. A virulent vasculopathy. *BMJ Case Reports* 2011;10.1136/bcr.11.2010.3481, date of publication

Become a Fellow of BMJ Case Reports today and you can:

- ▶ Submit as many cases as you like
- ▶ Enjoy fast sympathetic peer review and rapid publication of accepted articles
- ▶ Access all the published articles
- ▶ Re-use any of the published material for personal use and teaching without further permission

For information on Institutional Fellowships contact consortiasales@bmjgroup.com

Visit casereports.bmj.com for more articles like this and to become a Fellow