

Other full case

Cerebral venous sinus thrombosis associated with bulimia nervosa

Christopher McAloon,¹ Saad A M Saeed²¹Department of Respiratory Medicine, Wasall Hospitals NHS Trust, Walsall, UK;²Department of Acute Medicine, Wasall Hospitals NHS Trust, Walsall, UK**Correspondence to** Saad A M Saeed, saadsaeed@btinternet.com**Summary**

Central venous sinus thrombosis (CVST) is a rare cause of headache and stroke but has a wide clinical spectrum of presentations, including headache, seizures, focal neurological signs and alteration in consciousness, which can present in isolation or in various combinations. CVST is a difficult diagnosis to make in clinical practice but advances in neuroimaging allows for faster and more precise diagnosis, but it can still prove elusive. Non-infectious CVST are now more common than post-infectious, for which there are a variety of causes and risk factors in the clinical history that can suggest the diagnosis. The authors present a case that highlights the difficulty in diagnosis and identifies an association with a common eating disorder. A literature review discusses the complexities of presentation, aetiology, imaging and the current evidence on management.

BACKGROUND

This case highlights how difficult and complex cerebral venous sinus thrombosis (CVST) can be to diagnose. There is a wide range of potential presentations that are not specific to CVST. Understanding the broad range of risk and causative factors can suggest the diagnosis. Ultimately, correct neurological imaging will be required. The management decisions remain controversial, and pose the clinician difficulty. CVST is an elusive condition to diagnose, investigate and manage. This unique case offers our prospective and the specific lessons we learnt from managing it.

CASE PRESENTATION

A 36-year-old woman was admitted to our Acute Medical Unit with a 3-day history of headache and vomiting. The patient had a background of bulimia nervosa (BN) and previous sterilisation.

On the day of admission, the patient described a severe frontal headache that was not eased by simple analgesia. She described the headaches as being worse first thing in the morning. Four days prior to admission she developed loose stools but no symptoms to suggest viral illness.

There was no previous history of headaches and no family history of migraines. The patient had no prior history of thrombosis and no known thrombophilic predisposition. The only feature in the family history was the father had a pulmonary embolism at the age of 50 years.

On physical examination the patient was observed to be cachectic. She was haemodynamically stable with a normal neurological and funduscopy examination. The patient was dehydrated clinically.

INVESTIGATIONS

Preliminary bloods were normal, except for a potassium of 2.7 mmol/l and a mean cell volume of 126.2 fl. An urgent

CT scan of the head with contrast was carried out prior to a planned lumbar puncture (figures 1 and 2).

The CT venogram revealed a large superior anterior and right transverse sinus thrombosis.

A diagnosis of CVST secondary to dehydration and BN was made. Thrombophilic screen prior to anticoagulation was negative.

DIFFERENTIAL DIAGNOSIS

Severe migraine, tension headache, benign intracranial hypertension, meningitis, especially viral, and ischaemic stroke.

TREATMENT

The patient was treated with low molecular heparin (enoxaparin) and started on warfarin. Additionally, the patient was rehydrated with intravenous fluids and given potassium supplements. The patient continued to have intense headaches and was started on acetazolamide 250 mg twice a day on the advice of the neurologists.

OUTCOME AND FOLLOW-UP

The patient was discharged a week later to complete 6 months of warfarin treatment. The headache improved remarkably. The patient continued to improve and was followed up in the stroke clinic.

DISCUSSION

CVST is defined as any thrombosis in the veins or sinuses of the brain.¹ CVST was first described in 1825.² It is a rare condition affecting approximately 3–4 cases per million,³ accounting for 0.5% of all stroke cases.⁴ However, not all CVSTs present with strokes.

There are over a 100 independent risk and causative factors associated with the development of CVST (table 1). These factors can be broadly classified as acquired and

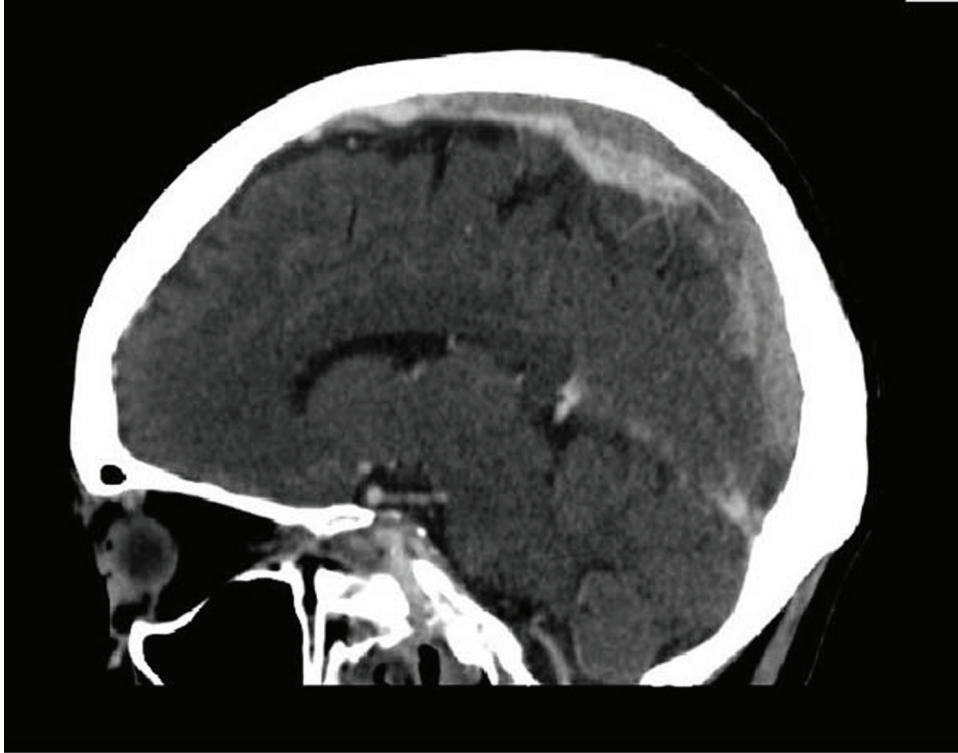


Figure 1 Sagittal segment CT venogram.

genetic. When looking for potential causes in a case history a systematic approach must be adopted applying the principle of Virchow's triad (blood stasis, vascular endothelial wall damage and alterations in the constitution of blood).⁵ Many causative factors are presented in the literature in anecdotal evidence and case series providing a weak body of evidence. The recently published International Study on Cerebral Vein and Dural Sinus Thrombosis (ISCVT) is a large multicentre clinical series that provides good evidence and understanding of CVST.¹ The ISCVT identified several causes together are associated in 44% of cases; moreover, 15% had no identifiable cause.¹ The most frequently occurring identifiable predisposing factors are certain pro-thrombotic states like pregnancy (third trimester), third generation oral contraceptive exposure, puerperium and infections.⁶ Dehydration is known risk factor for CVST; however, BN is not described in the literature as being an associated factor.

CVST can present with a wide variety of symptomatology adding to the difficulty of making a diagnosis. The ISCVT identified this difficulty with the average time from onset of symptoms to diagnosis being 7 days.¹ The symptoms the patient suffers and the overall outcome are affected by age, comorbidities, the anatomical location of the involved sinus, the extent and degree of thrombosis and the involvement of the cerebral parenchyma.⁵ Headache is the commonest presenting symptom in 89% of patients with CVST.¹ However, this is a very non-specific symptom offering no real clue to diagnosis. CVST headaches are typically dull, poorly localised and can be reproduced or aggravated by manoeuvres that raise intracranial pressure (ICP).⁷ Half the patients with CVST present with a focal syndrome with focal neurology and/or epileptic episodes.⁵

These deficits can vary dependent on the sinus involved; the superior sagittal sinus with bilateral symptoms and the left transverse sinus with aphasia.⁵ The commonest presentation with CVST is a hemiparesis or monoparesis.¹ Forty per cent of CVSTs present with seizures.¹

Fewer CVST patients present with a clinical syndrome of encephalopathy with multifocal signs leading to coma.⁵ These patients have extensive thrombosis involving deep cerebral venous occlusion. They often involve the cerebral parenchyma.⁵ The rarest presentation is cavernous sinus syndrome (CCS). CCS often involves oculomotor nerve palsies, facial pain, proptosis, chemosis or sensory loss in the distribution of the trigeminal nerve.⁸ Infection is often the cause of CCS and is associated with a poor prognosis.⁸

Making the CVST diagnosis is difficult; the history and symptomatology can direct the clinician. Correct use of investigations can make the diagnosis. Neuroimaging is the most important aspect of the investigation cascade for CVST. However, given the wide range of presentations, a non-invasive, easy to perform, test would be ideal for ruling out certain presentations without the need of radiation exposure and costly imaging. The D-dimer has been theorised to be a potential candidate given its high negative predictive value in deep vein thrombosis.⁹ In CVST, D-dimer only carries a high negative predictive value in patients with encephalic signs, who would undergo an MRI anyway;⁹ therefore, it is a poor screening test for CVST.

CVST patients need neuroimaging to establish the diagnosis, which will inevitably mean a CT head scan with contrast. The classical findings on CT are the empty triangle sign (delta sign), the cord sign and the dense triangle sign.¹ These pathognomonic signs are only seen in one-

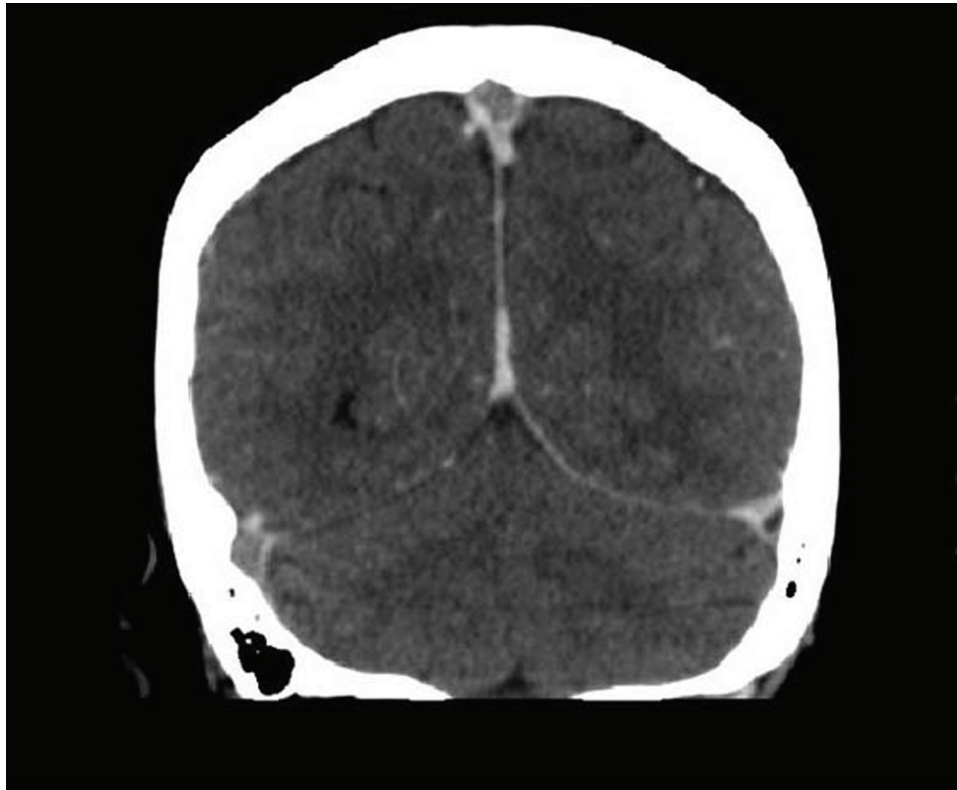


Figure 2 Coronal segment CT venogram.

Table 1 Risk and causative risk factors for CVST

Genetic prothrombotic states	Acquired prothrombotic states	Infection	Mechanical causes
Factor V Leiden mutation	Pregnancy	Meningitis	Head trauma
Prothrombin mutation	Puerperium	Otitis	Intravenous drug abuse
Antithrombin deficiency	Antiphospholipid syndrome	Mastoiditis	Neurosurgery
Resistance activated protein C	Nephrotic syndrome	Sinusitis	Lumbar puncture
Protein C and S deficiency		Systemic infection	
		AIDS	
Drugs	Inflammatory	Malignancy	Haematology
Lithium	Wegener's granulomatosis	Central nervous system tumours	Polycythaemia
Oral contraceptives	Inflammatory bowel disease	Systemic malignancies	Thrombocythaemia
Steroids	Sarcoidosis		Autoimmune haemolytic anaemia
Hormone replacement	Systemic lupus erythematosus		Thrombotic thrombocytopenic purpura
Sumatriptan			
Ecstasy			
Other causes			
Post radiation			
Congenital heart disease			
Dehydration			
Thyrotoxicosis			
Dual fistulae			

third of cases.¹⁰ MRI, MR angiography and venography provide the most sensitive neuroimaging for detecting CVST. These imaging modalities combined offer the gold standard in achieving the diagnosis. The signal intensity on MRI from CVST varies dependent on the time course; therefore, the images must be viewed with this knowledge.⁵ Thrombosed sinuses appear as iso-intense on T1 weighted images and hypo-intense on T2 weighted images in the first 3–5 days.⁵ Following 5 days it appears as hyper-intense on both weighted images.⁵ Despite the sensitivity

of the combination of imaging modalities, caution must be taken due to flow artefacts causing false negatives and the images must be interpreted by someone with a good awareness of the neuroanatomy.

The mainstay of treatment of CVST is with anticoagulants, although this is controversial. A Cochrane review identified that anticoagulants are beneficial in the treatment of CVST.¹¹ The period after the index event required for anticoagulation is dependent on the cause and this must be thoroughly investigated. Thrombolytic treatment

Learning points

- ▶ Making the diagnosis between arterial stroke and CVST can be difficult, but raised ICP and seizures tend to predominate in CVST.
- ▶ A structured analysis of the patient's medical history may provide a clue to the diagnosis on the basis of the broad causative and risk factors.
- ▶ The combination of MRI, MR angiography and venography offer the gold standard in making the diagnosis of CVST.
- ▶ Anti-coagulants are the mainstay of treatment. Thrombolytic have no proven benefit in the treatment of CVST.

is proposed in patients with a deteriorating clinical course despite anticoagulation treatment.¹² The anticipated outcome is the re-canalisation of the occluded sinus. Ciccone *et al* performed a Cochrane review that did not demonstrate any reliable evidence in the use of thrombolytic agents for treatment of CVST.¹²

This case offered some difficulty in management, because of the continued intense headaches. There is little evidence to show the direct benefit of acetazolamide for CVST, but it helped the patient by lowering the ICP. In some cases, surgical intervention may be warranted such as placement of a shunt.

There is a wide range of potential presentations that are not specific to CVST. Understanding the broad range of causative and risk factors will suggest the diagnosis. Ultimately, neuroimaging will be required. The management remains controversial, but as a larger body of evidence is created this is becoming more refined with first-line

treatment being anti-coagulation. The key to management of CVST is making the diagnosis, for which the clinician must always keep an open mind for.

Acknowledgements The authors would like to thank Dr David Francis, consultant neurologist, who contributed in managing the case.

Competing interests None.

Patient consent Obtained.

REFERENCES

1. **Ferro JM**, Canhão P, Stam J, *et al*. Prognosis of cerebral vein and dural sinus thrombosis: results of the International Study on Cerebral Vein and Dural Sinus Thrombosis (ISCVT). *Stroke* 2004;**35**:664–70.
2. **Buccino G**, Scoditti U, Pini M, *et al*. Loco-regional thrombolysis in the treatment of cerebral venous and sinus thrombosis: report of two cases. *Acta Neurol Scand* 2001;**103**:59–63.
3. **Agnelli G**, Verso M. Epidemiology of cerebral vein and sinus thrombosis. *Front Neurol Neurosci* 2008;**23**:16–22.
4. **Boussier MG**, Ferro JM. Cerebral venous thrombosis: an update. *Lancet Neurol* 2007;**6**:162–70.
5. **Filippidis A**, Kapsalaki E, Patramani G, *et al*. Cerebral venous sinus thrombosis: review of the demographics, pathophysiology, current diagnosis, and treatment. *Neurosurg Focus* 2009;**27**:E3.
6. **Canhão P**, Ferro JM, Lindgren AG, *et al*. Causes and predictors of death in cerebral venous thrombosis. *Stroke* 2005;**36**:1720–5.
7. **de Bruijn SF**, de Haan RJ, Stam J. Clinical features and prognostic factors of cerebral venous sinus thrombosis in a prospective series of 59 patients. For The Cerebral Venous Sinus Thrombosis Study Group. *J Neurol Neurosurg Psychiatr* 2001;**70**:105–8.
8. **Ebright JR**, Pace MT, Niazi AF. Septic thrombosis of the cavernous sinuses. *Arch Intern Med* 2001;**161**:2671–6.
9. **Talbot K**, Wright M, Keeling D. Normal d-dimer levels do not exclude the diagnosis of cerebral venous sinus thrombosis. *J Neurol* 2002;**249**:1603–4.
10. **Canhão P**, Falcão F, Ferro JM. Thrombolytics for cerebral sinus thrombosis: a systematic review. *Cerebrovasc Dis* 2003;**15**:159–66.
11. **Stam J**, De Bruijn SF, DeVeber G. Anticoagulation for cerebral sinus thrombosis. *Cochrane Database Syst Rev* 2002;**4**:CD002005.
12. **Ciccone A**, Canhão P, Falcão F, *et al*. Thrombolysis for cerebral vein and dural sinus thrombosis. *Cochrane Database Syst Rev* 2004;**1**:CD003693.

This pdf has been created automatically from the final edited text and images.

Copyright 2011 BMJ Publishing Group. All rights reserved. For permission to reuse any of this content visit <http://group.bmj.com/group/rights-licensing/permissions>.
BMJ Case Report Fellows may re-use this article for personal use and teaching without any further permission.

Please cite this article as follows (you will need to access the article online to obtain the date of publication).

McAloon C, Saeed SAM. Cerebral venous sinus thrombosis associated with bulimia nervosa. *BMJ Case Reports* 2011;10.1136/bcr.07.2010.3186, date of publication

Become a Fellow of BMJ Case Reports today and you can:

- ▶ Submit as many cases as you like
- ▶ Enjoy fast sympathetic peer review and rapid publication of accepted articles
- ▶ Access all the published articles
- ▶ Re-use any of the published material for personal use and teaching without further permission

For information on Institutional Fellowships contact consortiasales@bmjgroup.com

Visit casereports.bmj.com for more articles like this and to become a Fellow