

REVIEW ARTICLE

Update on PML and PML-IRIS Occurring in Multiple Sclerosis Patients Treated With Natalizumab

B.K. Kleinschmidt-DeMasters, MD, Augusto Miravalle, MD, Jeffrey Schowinsky, MD, John Corboy, MD, and Timothy Vollmer, MD

Abstract

The use of natalizumab to treat multiple sclerosis (MS) has been associated with the development of progressive multifocal leukoencephalopathy (PML), with 242 PML cases reported as of May 3, 2012. Fortunately, rapid withdrawal of the drug and administration of plasma exchange has allowed survival in many of these patients, but a new problem, immune reconstitution inflammatory syndrome (IRIS), has emerged after drug withdrawal. This report provides an update on PML in natalizumab-treated patients and reviews what is currently known about PML-IRIS in this setting; autopsy findings from a well-studied patient are illustrated. This patient with relapsing-remitting MS had been treated for 4 years with natalizumab, with discontinuation of drug after diagnosis of PML by cerebrospinal fluid polymerase chain reaction testing. Disease was manifested by severe paraparesis and expressive aphasia, which progressed before and after the diagnosis of PML. Immune reconstitution inflammatory syndrome was diagnosed, comfort care was instituted, but demise did not occur until 9 months later. Autopsy showed ongoing severe PML-IRIS, with massive cavitary brain lesions containing abundant perivascular and parenchymal CD8-positive T-cell infiltrates. Bone marrow and spleen, but not brain, contained monoclonal T-cell populations by polymerase chain reaction–based gene rearrangement studies, indicating overstimulation of peripheral T cells; T-cell lymphoma was not identified by morphological or immunohistochemical criteria.

Key Words: CSF PCR, Immune reconstitution inflammatory syndrome, Natalizumab withdrawal, Progressive multifocal leukoencephalopathy, Tysabri.

INTRODUCTION

This review will provide an update on the continuing occurrence of progressive multifocal leukoencephalopathy (PML) in multiple sclerosis (MS) patients treated with natalizumab (Tysabri, Biogen Idec, Weston, MA), including the emerging entity of asymptomatic PML discovered on neuroimaging studies used for monitoring patients while they are on this medication. We discuss immune reconstitution inflammatory syndrome (IRIS) in the setting of natalizumab

withdrawal and often plasma exchange (PLEX) treatment. We then present the clinical, laboratory, and neuropathological features of a fatal case of PML-IRIS with long-term survival to illustrate the salient features of this condition. In this case, clonal T-cell populations were found by polymerase chain reaction testing (PCR) in several peripheral organs, but not the brain; this finding is discussed in conjunction with several other reports of T-cell clonal abnormalities in natalizumab-treated patients. We review the literature on how natalizumab treatment might lead to overstimulation of peripheral T lymphocytes. Finally, we address the question of whether IRIS develops on withdrawal of natalizumab even in the absence of PML, the so-called “natalizumab withdrawal syndrome.”

Update on PML in the Setting of Natalizumab Treatment

Natalizumab is a monoclonal antibody directed against $\alpha 4\beta 1$ and $\alpha 4\beta 7$ integrins that prevents inflammatory cells from binding to brain endothelial cells and passing into the brain (1). The drug was shown to be highly clinically effective in initial trials of MS patients, with a reduction in clinical relapse rate, a reduction in new T2-weighted and T1 contrast-enhancing lesions, and slowing of disability progression (1–3). It was introduced in the US market in late 2004 for treatment of MS.

Unfortunately, soon after its introduction, 2 patients in natalizumab trials developed a rare viral infection of the brain, PML, an infection not previously reported in patients with MS (4, 5). That the PML was likely caused by the drug, and not by the underlying MS, was further reinforced by the occurrence of PML in a patient with Crohn disease who also had been treated with natalizumab (6).

The drug was withdrawn from the market in early 2005 and reintroduced in the United States in mid-2006 with a mandatory risk mitigation strategy, the Tysabri Outreach: Unified Commitment to Health program. Despite these precautions, 3 more cases of confirmed PML in MS patients had been identified by 2008, all of whom had been on natalizumab monotherapy for less than 17 months (1), unlike the first 2 who had received multiple immunotherapies for 2 years or more (1). As of May 3, 2012, approximately 99,600 patients have received natalizumab worldwide, with 242 PML cases reported. In data tabulated by Biogen Idec as of May 3, 2012 of the approximately 99,600 patients who had received Tysabri worldwide, 54,166 were from the United States, 37,870 were from the European Economic Area, and 7,529 from the rest of the world

From the Departments of Pathology (BKK-D, JS), Neurology (BKK-D, AM, JC, TV), and Neurosurgery (BKK-D), Anschutz Medical Campus, University of Colorado Anschutz Medical Campus, Aurora, Colorado.

Send correspondence and reprint requests to: Bette Kay Kleinschmidt-DeMasters, MD, Department of Pathology University of Colorado Anschutz Medical Campus, 12631 E. 17th Avenue Mail Stop C307, Aurora, CO 80045; E-mail: bk.demasters@ucdenver.edu

None of the authors have received any funding or support for this work.

(7). Despite the higher number of patients in the United States, more of the PML cases have originated from Europe (90 US, 141 EEA, 11 rest of the world); the explanation for this is unclear. Known risk factors for the development of PML in MS patients include prior exposure to the JC virus (JCV) and length of treatment duration, especially beyond 2 years, although patients with shorter durations of natalizumab monotherapy have also developed the disorder (1). Currently, there is limited experience in patients who have received more than 4 years of Tysabri treatment. Thus, risks related to longer periods of administration of drug cannot be currently estimated.

Past history of treatment with other immunosuppressive medications for MS before receiving Tysabri (often interferon β -1a; Avonex) is also a risk factor for developing PML. In one study, 42% out of the first 102 postmarketing PML cases had been treated with an immunosuppressant drug before receiving Tysabri. The TYSABRI Global Observational Program in Safety (TYGRIS) trial estimated that 20.3% of Tysabri-treated patients (13.9% in the United States and 23.6% in the European Union) had been treated with another immunosuppressive drug before receiving Tysabri (7).

In contrast to the high mortality rate of PML in the acquired immunodeficiency syndrome (AIDS) and pre-AIDS era, as of April 5, 2012, only 52 of 242 PML MS Tysabri patients (21%) had died (7). However, survivors have varying levels of disability, ranging from severe to mild. Based on preliminary data collected from the first 175 postmarketing PML cases reported as of October 21, 2011, the 58 patients who were alive with at least 6 months of follow-up time since PML diagnosis were skewed toward significant disability. Specifically, approximately 10% had mild disability (Karnofsky score of 80–100), one half had moderate disability (Karnofsky score 50–70), and 40% had severe disability (Karnofsky score 10–40) (7). Thus, although the survival rate is promising, the disability rate is significant for some patients once PML has fully developed. Mortality has been higher in older patients, those with more severe MS, and those in whom there has been a delay in PML diagnosis.

Of the 28 surviving patients tracked on the Biogen Idec Web site who were alive at least 9 months after the diagnosis of PML, the overwhelming majority had moderate to severe disability, and the average change in Karnofsky score was a decrease of 26 points in that time interval (7). Thus, early detection of disease remains paramount.

The conscientious use of magnetic resonance imaging (MRI) monitoring appears to detect extremely early cases of PML in this population. Since January 2012, 3 reports of natalizumab-treated patients with asymptomatic PML have been published (8–10). A similar unpublished example of early/near-asymptomatic PML seen recently at our institution is illustrated in Figure 1.

Clinical Report of Asymptomatic PML

A 32-year-old woman with MS took natalizumab uneventfully for 57 consecutive doses. She was JCV positive and without motor or sensory signs or symptoms. Her previous August 2011 MRI scan had shown minimal MS plaques (Fig. 1A); however, a routine surveillance scan in March 2012 surprisingly revealed abnormalities concerning for PML

(Fig. 1B). Natalizumab was discontinued, and JCV PCR was detected in the cerebrospinal fluid (CSF). She underwent PLEX and began oral steroids. On extensive further questioning, she noted (in retrospect) very modest difficulties with short-term memory, slurred speech, and word finding for the 7 to 8 months preceding the abnormal March 2012 brain MRI results.

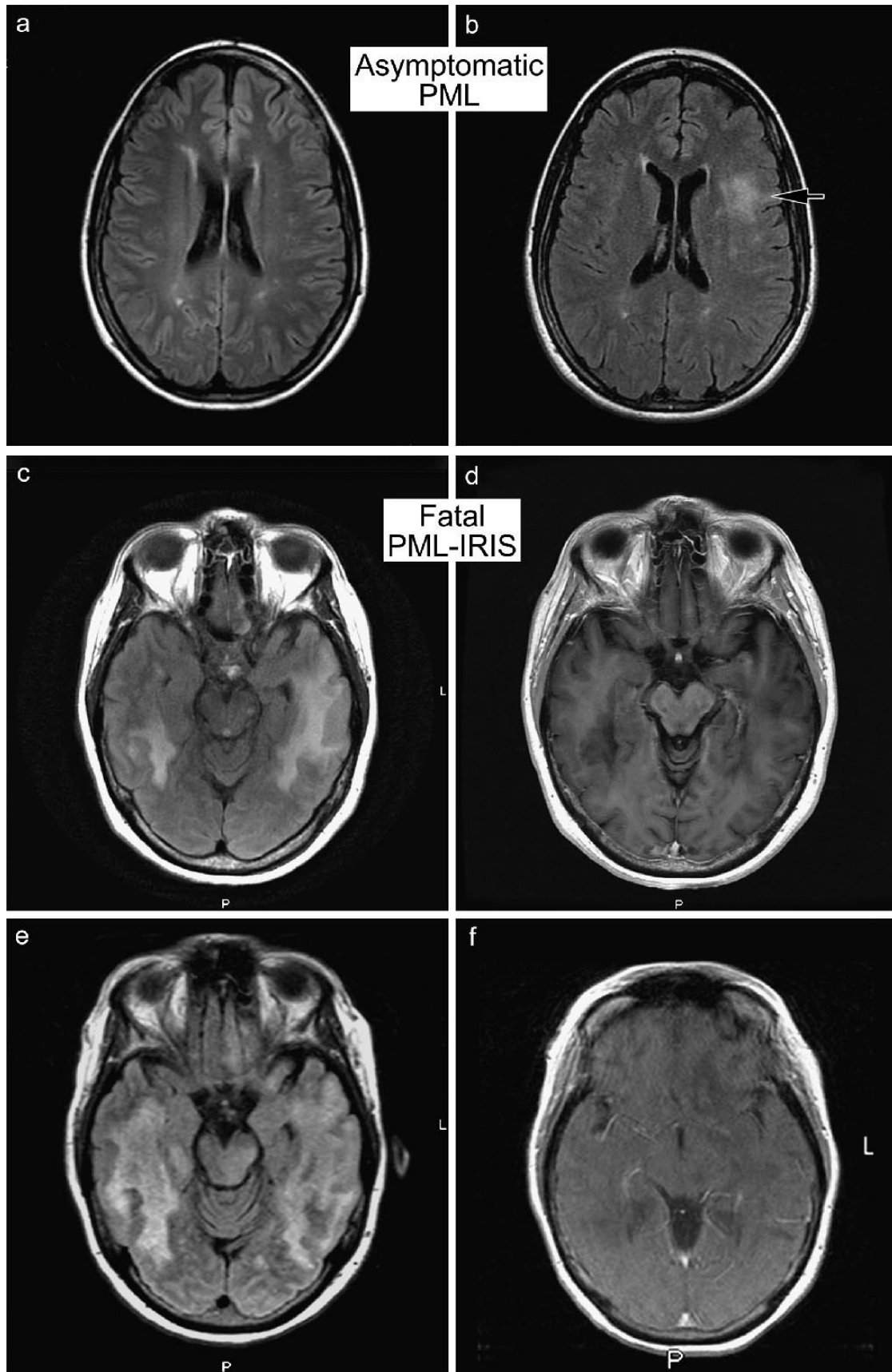
The unique relationship between PML and natalizumab has become increasingly apparent over time. Despite the more than 200 natalizumab-associated cases of PML reported to date (7), many of the other opportunistic infections or neoplastic conditions commonly seen in other immunosuppressed populations have been far less commonly reported (1, 11–18). Although rare overall, these case reports of non-PML immunosuppressive conditions in natalizumab-treated patients suggest that more ongoing vigilance for complications is necessary on the part of both clinicians and pathologists (19).

IRIS in the Setting of Natalizumab Withdrawal: Parallels With IRIS Caused by HAART in Patients With AIDS

Immune reconstitution inflammatory syndrome was originally described in patients with AIDS in whom highly active antiretroviral therapy (HAART) was instituted after diagnosis of an infectious disorder (20, 21). Most IRIS-HAART cases occurred in association with *Mycobacterium avium* complex, *Mycobacterium tuberculosis*, cytomegalovirus, or herpes zoster infections, although cases also occurred with *Cryptococcus neoformans* meningitis, Kaposi sarcoma, and PML (20). It was assumed that immune-restorative HAART allowed host recognition of antigens associated with an underlying infection and provided for a rapid exuberant rebound host inflammatory response to either replicating infectious agents or nonreplicating antigens from a previous infection (20, 22). However, it was apparent even in the AIDS population that some patients appeared to develop IRIS without a documentable antecedent infection (22).

Immune reconstitution inflammatory syndrome in patients with AIDS is defined clinically as a paradoxical deterioration soon after starting HAART, despite the fact that the patient has a reduction in human immunodeficiency virus (HIV) loads and improved CD4 T-cell counts (20, 21). Up to one third of patients with AIDS developed IRIS after HAART institution (21). Neuropathological features of IRIS caused by HAART in patients with AIDS were best detailed by Rushing et al (22). In that report, the “minimal histopathologic feature interpreted as consistent with IRIS was inflammation, with predominance of CD8-positive lymphocytes, often accompanied by macrophages and necrosis”; overwhelming numbers of CD8-positive T lymphocytes were accompanied by lesser numbers of CD4-positive T cells and CD20-positive B cells; and the search for opportunistic infectious agents by histochemical and immunohistochemical stains was sometimes negative, except for HIV p24 (22).

Similarly, IRIS also occurs in patients with natalizumab-associated PML after removal of the drug (23). In PML-IRIS, CNS infection by JCV can be documented, usually based on positive CSF PCR testing followed by a paradoxical inflammatory reaction that presumably is an overexuberant



response to the virus by the restored host immune system (24–26). Nearly all natalizumab-related PML patients develop IRIS as a consequence of cessation of receipt of medication and removal of the drug from the bloodstream by PLEX (27). Immune reconstitution inflammatory syndrome can also occur in patients who are not treated with PLEX (28). The PML-IRIS clinically presents within days to several weeks after initiation of PLEX and develops later than in those who do not receive PLEX, at approximately 90 days after the last natalizumab dose. A review of 28 confirmed natalizumab-associated PML cases between 2006 and 2009 described the features of PML-IRIS (29). Clinical presentation was characterized by rapid onset of worsening of previous neurological deficits, with MRI evidence of enlarging T2/FLAIR lesions, along with active contrast enhancement. Mortality occurred in close to one third of patients. There is no specific treatment for PML-IRIS, but high-dose intravenous methylprednisolone is usually instituted early in the disease process.

A few reports have emerged, detailing the neuropathological features of PML-IRIS in natalizumab-treated MS patients (25–27). We review those published findings in relationship to a case seen at our institution.

Clinical Report of Fatal PML-IRIS

A 56-year-old woman with relapsing-remitting MS had been taking natalizumab continuously for 4 years, rarely missing a dose. She was scheduled to receive her next dose in September 2010, but this was canceled because of insurance issues and loss of her job. During that same week, the patient started to have coldlike symptoms, including dry cough, malaise, fatigue, runny nose, followed by word-finding difficulties, inability to read letters, sentences, or understand the alphabet, and difficulty with writing. Her symptoms prompted a visit to her primary neurologist who advised an MRI scan, but this was declined because of her insurance problems. Soon thereafter, her husband's concerns led to hospital admission, with transfer 2 days later to the University of Colorado Hospital for further evaluation.

On admission, neurological examination revealed a primarily expressive aphasia with mild weakness of the legs and ataxia. The MRI scan on October 18, 2010, showed confluent bilateral white matter T2 hyperintensities with no enhancement, consistent with PML (Fig. 1C), with a suggestion of a dark signal in the same areas on T1-weighted postcontrast studies (Fig. 1D), indicating tissue destruction. A spinal fluid evaluation identified a low copy number of JCV by PCR, and other evaluations for a variety of alternative diagnoses were ruled out (Table).

After the diagnosis of PML was made, the patient was immediately started on mefloquine (250 mg orally everyday for 3 days followed by a weekly dose), mirtazapine (60 mg orally everyday), and empirical Solu-Medrol (1 g intravenously daily). Plasma exchange treatments were administered for 5 days. Solu-Medrol was continued for a total of 10 days. The JCV serological testing obtained between the first and second round of PLEX revealed no previous exposure to JCV. Further extensive workup was undertaken (Table). Repeat CSF examination on October 18, 2010, had a similar low white blood cell count and JCV viral load, at a time when the urine had more than 10^6 copies of JCV.

Despite multimodal treatment and a negative JCV viral load on November 18, 2010, she continued to deteriorate. By November 2010, the patient was only able to moan after vigorous tactile stimulation, had no vocalization, and was unable to follow commands. The brain MRI scan on November 17, 2010, demonstrated progression of the burden of white matter disease (Figs. 1E, F) compared with a study obtained 4 weeks earlier (Figs. 1C, D). Subtle enhancement suggested PML-IRIS. By late November 2010, the patient had become progressively less responsive and was transferred to hospice care. She died in August 2011, almost 9 months after discharge, during which no further therapy was given and no further laboratory or neuroimaging testing was performed. Permission for autopsy was obtained.

Autopsy Findings of Fatal PML-IRIS in the CNS

Autopsy was performed 20 hours after death. The left one-half brain and multiple segments of spinal cord were frozen and banked, per the Rocky Mountain Multiple Sclerosis Brain Bank protocol (National MS Society grant no. RG-2859-D-9/T). The 580-g right one-half hemisphere and remaining spinal cord were formalin fixed for examination. As specified in the protocol and per autopsy permission, limited tissue samples were also obtained from the liver, spleen, bone marrow, and kidney; portions were fixed in formalin for routine histology, and frozen samples were submitted for PCR testing for T- and B-cell gene rearrangement.

The midsagittal gross brain demonstrated no edema, herniations, leptomeningeal opacification, or hemorrhages (Fig. 2A). A large depressed, discolored, softened area of tissue was identified on the mesial aspect of brain, just anterior to the parieto-occipital sulcus (Fig. 2A, arrow). Genu was preserved (Fig. 2A); posterior portions of the body and splenium of corpus callosum were atrophic and focally cavitated (Fig. 2B).

FIGURE 1. Neuroimaging of asymptomatic progressive multifocal leukoencephalopathy (PML) and fatal PML-immune reconstitution inflammatory syndrome (IRIS). **(A, B)** Magnetic resonance imaging (MRI) brain axial T2/FLAIR sequences from a 32-year-old woman in August 2011 **(A)** and a new finding discovered on routine surveillance scan in March 2012 **(B)**. The lesion in **(B)** (arrow) was concerning for and was subsequently proven to be PML by positive cerebrospinal fluid–polymerase chain reaction for JC virus. Retrospectively, on questioning, she admitted mild cognitive problems, but neurological examination was entirely normal. **(C–F)** Fatal PML-IRIS in a 56-year-old woman. The MRI brain axial T2/FLAIR sequences **(C, E)** and post-gadolinium contrast T1 **(D, F)** show the rapid progression in tissue damage during 4 weeks from October 2011 **(C, D)** to November 2011 **(E, F)** during her initial hospitalization. The FLAIR highlights diffuse areas of nearly confluent bilateral white matter T2 hyperintensities; the T1 post-gadolinium contrast shows darkened areas of destructive demyelination with subtle contrast enhancement. These were highly suspicious for PML. The subtle areas of enhancement suggest an early active inflammatory process as seen in IRIS.

TABLE. Laboratory Testing Results

Cerebrospinal Fluid			
Date	October 15, 2010	October 18, 2010	November 18, 2010
WBC, 10 ⁶ /L	0	2	26
Lymphocytes, %	ND	38	91
Monocytes, %	ND	56	9
Neutrophils, %	ND	6	0
Protein, mg/dL	32	28	59
Glucose, mg/dL	53	83	96
JCV PCR	100–1,000 copies/mL (1,275 in analysis performed at NIH)	100–1,000	<100 (negative)
Varicella zoster virus PCR	Negative	ND	Negative
Herpes simplex virus PCR	Negative	ND	Negative
Epstein Barr virus PCR	Negative	ND	ND
Human herpes virus-6 PCR	Negative	ND	Negative
Cytomegalovirus PCR	Negative	ND	Negative
Enterovirus PCR	ND	ND	Negative
Cytology	Negative	ND	Negative
Flow Cytometry	Negative	ND	Negative
CD4:CD8 ratio	2.5	ND	ND
IgG Index	1.52	ND	ND
Oligoclonal bands	Positive (18 bands)	ND	ND
Urine: PCR for JCV			>1,000,000
Serum: angiotensin-converting enzyme	26 U/L*		

Serum HIV was negative, CD4 count was 1,560.

*Normal range: 9 to 67 U/L for patients older than 18 years.

JCV, JC virus; ND, not done; NIH, National Institutes of Health, Bethesda, MD; PCR, polymerase chain reaction; WBC, white blood cells.

Coronal sections of the right hemisphere revealed a well-demarcated, gray, glistening periventricular MS plaque surrounding the anterior horn of the lateral ventricle (Fig. 2C). Small, rare, cerebrocortical gray-white junction (Fig. 2C) and cerebellar plaques (Fig. 2D) were noted, but genu, centrum semiovale (Fig. 2E), posterior periventricular white matter, basal ganglia (Fig. 2E), thalamus, brainstem, and the several formalin-fixed spinal cord sections available per protocol showed no gross MS plaque involvement.

A massive 4 × 5-cm cystic lesion extended from the inferior temporal lobe (Fig. 2F) into the medial occipital lobe (Figs. 2G–I). Granular, yellow, moth eaten–appearing white matter was seen adjacent to the cavitation (Figs. 2F–I). Hydrocephalus ex vacuo was most evident at the level of the trigone (Figs. 2G). Cortical damage was identified in regions immediately overlying white matter lesions (Figs. 2F, H, I). The severity of tissue damage far exceeded that seen in severe MS or in the autopsy of our original published patient with natalizumab-associated PML (4).

Microscopically, MS plaques were predominantly chronic, inactive, well-demarcated plaques devoid of myelin (Fig. 3A). They lacked hypercellularity at the perimeter (as would be seen with chronic active MS plaque), macrophages, or myelin breakdown products, although perivascular mononuclear cells were noted (Figs. 3A, B). Near the edge of the periventricular MS plaque, there was an ill-defined, hypercellular, demyelinating inflammatory lesion consistent with PML-IRIS (Fig. 3C).

The PML-IRIS lesions were variably cavitory (Fig. 3D) and, in some areas, extended into the contiguous overlying cortex (Fig. 3E), resulting in marked neuronal loss. There was a sharp demarcation in between the severely affected overlying cortex (Figs. 3E and F, left) and the adjacent intact cortex (Fig. 3F, right). Occasional ferruginated neurons were identified in the damaged cortex (Fig. 3G); the adjacent cortex showed rare neuronophagia and microglial clusters (Fig. 3H) or diffuse microgliosis (Fig. 3I). There was no significant chronic hypoxic injury, laminar necrosis in a vascular/ischemic pattern, or infarct in the gray matter.

Cavitory PML-IRIS lesions were appreciable grossly (Figs. 2F–I), and whole-mount sections (Fig. 3D) showed rarefaction and reactive astrocytes, some with mild cytological atypia (Fig. 4A). In areas of myelin loss, macrophages contained predominantly periodic acid Schiff–positive chronic myelin breakdown products (Fig. 4B). Rare Luxol fast blue granules were identified within macrophages (Fig. 4B, insert), indicating a low level of myelin breakdown and the ongoing nature of the IRIS. Varying degrees of axonal loss paralleled the degree of cavitation (Fig. 4C), but no neuroaxonal swellings were identified. A careful search on numerous sections for intranuclear inclusions typical of PML was entirely negative; immunohistochemistry (IHC) on 3 different tissue sections for JCV (1:100 dilution; JC-SV40-T, catalog no. DP02; Calbiochem, St Louis, MO) was also negative.

The PML-IRIS lesions, unlike the MS plaques, manifested overwhelming lymphocytic infiltrates, arranged both

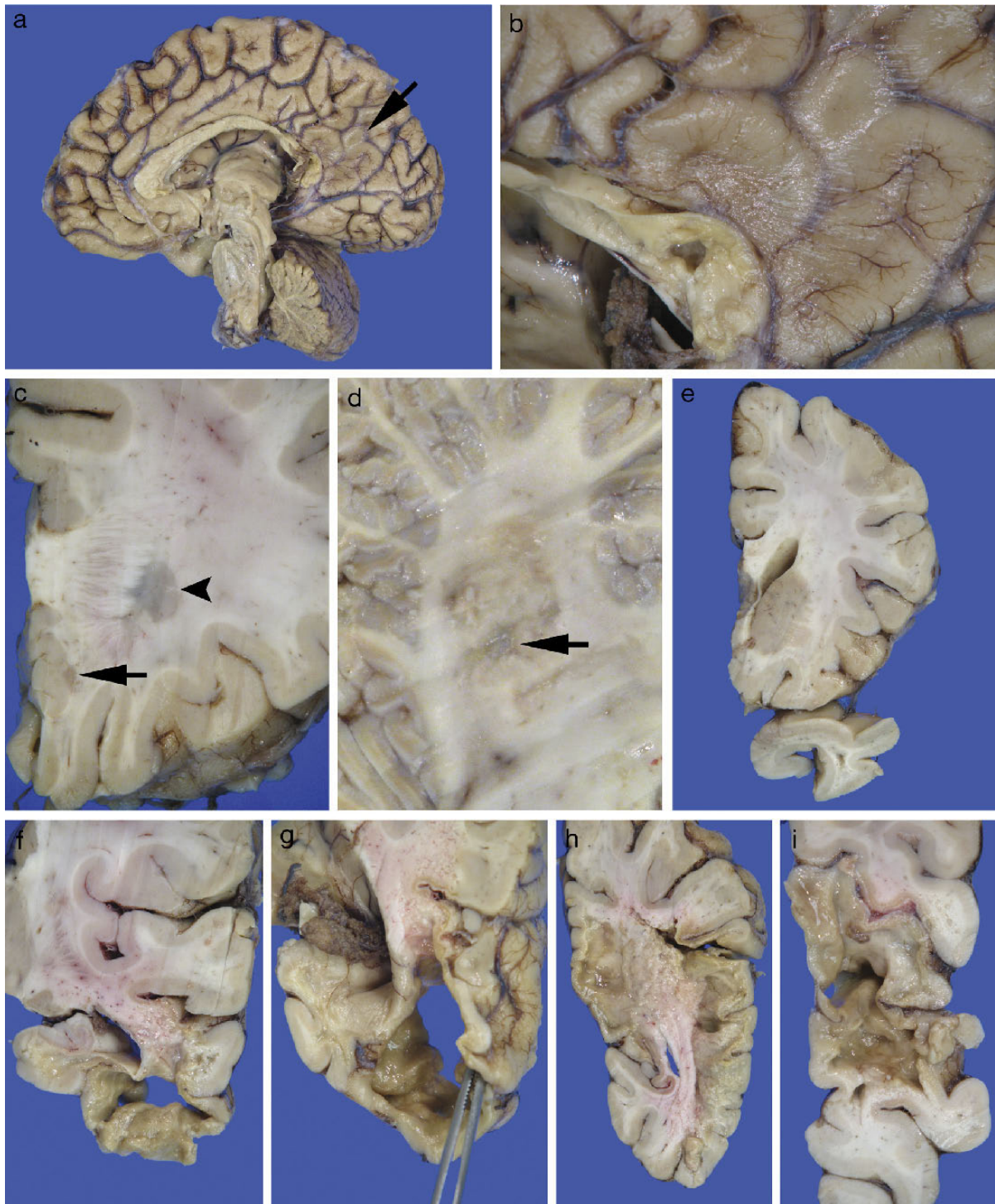


FIGURE 2. Fatal progressive multifocal leukoencephalopathy (PML)–immune reconstitution inflammatory syndrome (IRIS). (**A–I**) The patient whose images are shown in Figure 1C to F survived 9 months after hospital discharge without further neuroimaging or laboratory studies. At the time of death, the brain showed a large, depressed, discolored, softened area of tissue on the mesial aspect of brain just anterior to the parieto-occipital sulcus (**A**), with partial cavitation in the adjacent splenium (**B**). Multiple sclerosis plaques were present near the right frontal horn (**C**, arrowhead) and near the gray-white cortical junction (**[C]** arrow) and dentate nucleus (**D**); centrum semiovale and basal ganglia were largely unaffected (**E**). There was a massive cavitory lesion surrounded by granular, moth-eaten, yellow discoloration in the right hemisphere white matter that extended into the overlying cortex (**F–I**), but cortex remote from the cavitory PML-IRIS lesion was intact. Note that the PML-IRIS occurs in the same area as the previous PML seen in Figure 1C to F.

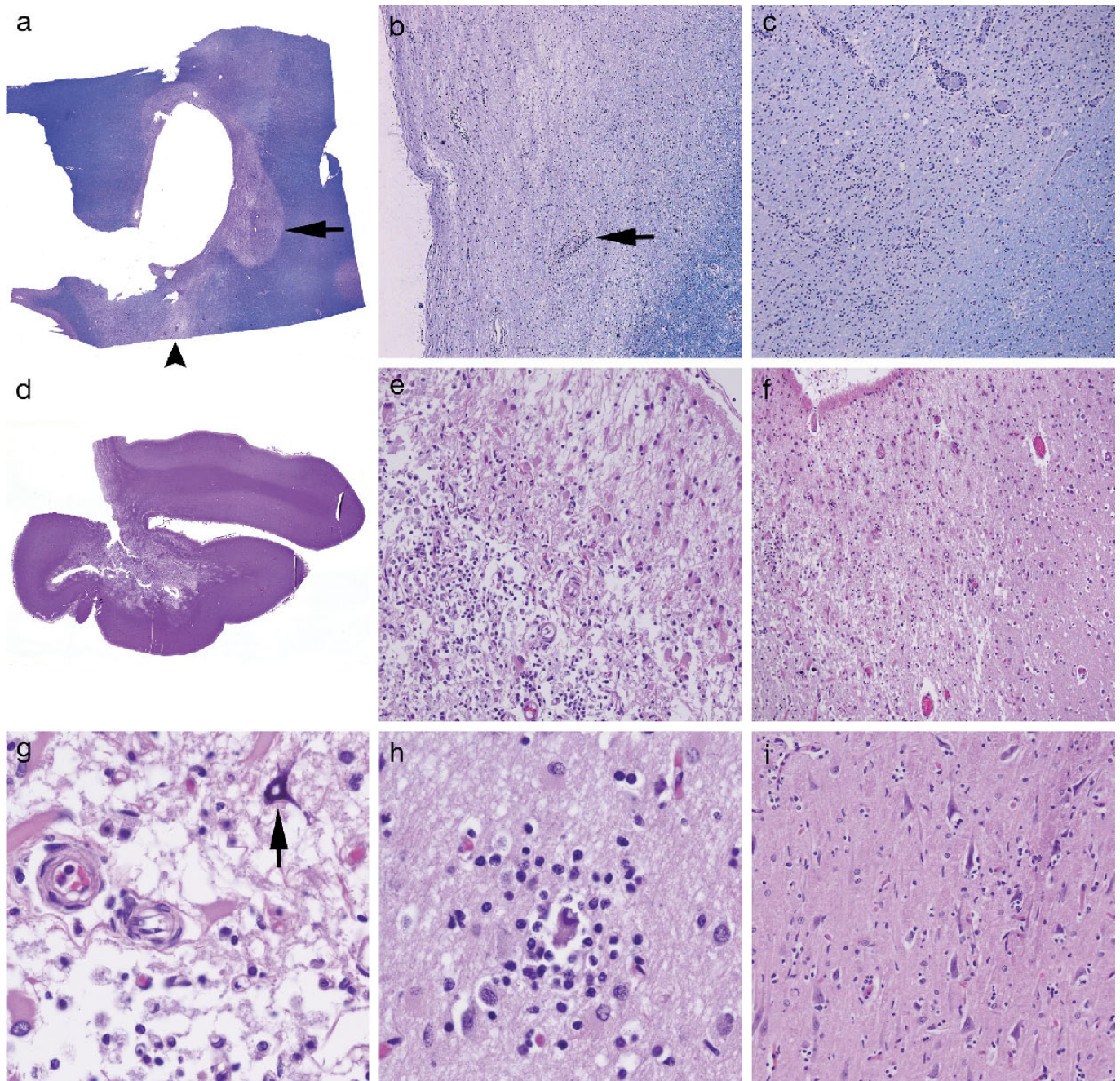


FIGURE 3. Fatal progressive multifocal leukoencephalopathy (PML)–immune reconstitution inflammatory syndrome (IRIS). (**A–I**) Whole-mount section of the lesion in the right frontal horn seen in Figure 2C shows a well-demarcated chronic inactive multiple sclerosis (MS) plaque almost encircling the ventricle (arrow); adjacent to this is a more ill-defined area of white matter pallor (arrowhead). The MS plaque (**[A]** arrow) is seen at higher magnification in (**B**), and like most of the MS plaques in the case, it was chronic inactive, that is, it did not contain myelin debris but there was perivascular inflammation (**[B]** arrow). By contrast, IRIS lesions showed ill-defined myelin pallor (**C**) (corresponding to arrowhead in **[A]**). The PML-IRIS lesions also showed intense hypercellularity within the parenchyma (**C**), contrasting with the hypocellular MS lesions. More severe PML-IRIS lesions showed cavitation (**D**), with a sharp demarcation between affected and unaffected tissues; note the preservation of the superior temporal gyrus. Areas of cavitory white matter PML-IRIS destruction extended into the overlying cortex (**E**), causing extensive neuronal loss. There was a sharp border between affected (**F**, left) and unaffected (**F**, right) cortices. Areas of cortical PML-IRIS contained ferruginated neurons (**[G]** arrow), rare neuronophagia and microglial clusters (**H**), and diffuse microgliosis (**F**). Luxol fast blue–periodic acid Schiff stain (**A–C**); hematoxylin and eosin (**D–I**). Magnifications: (**A**, **D**), whole mount; (**B**) 40 \times ; (**C**, **F**), 100 \times ; (**E**), 200 \times ; (**G**, **H**) 600 \times .

as loosely aggregated suffusions within the parenchyma (Figs. 4D, E) and as tight perivascular cuffs (Fig. 4F). The inflammation was composed predominantly of CD8-positive T lymphocytes in both parenchyma (Figs. 4G, H) and perivascular cuffs (Fig. 4I), with fewer CD4-positive T lymphocytes (Fig. 4J) and CD20-positive B lymphocytes (Fig. 4K) that were mostly confined to perivascular cuffs. CD138-positive plasma cells were less frequent but could be found especially in the smaller, less cavitated lesions; plasma cells were seen both in parenchyma (Fig. 4E, arrows) and as a small component of the perivascular cuffs. Mast cells and eosinophils were not identified.

Small ovoid areas of perivascular myelin damage were present in white matter near the edges of larger coalescent lesions (Fig. 5A). These showed varying degrees of hypercellularity, astrocytosis, and macrophage influx (Figs. 5B, C); intranuclear viral inclusions of PML were carefully sought in these areas, both by light microscopy and IHC, but none were found. These perivascular areas of myelin loss were anatomically reminiscent of small, early but arrested, PML lesions that had now been replaced by IRIS and highlighted by myelin basic protein (MBP) IHC (Fig. 4D). Occasional larger ovoid regions of myelin pallor suggestive of MS shadow plaque formation were also identified on MBP IHC in deep cerebral white matter (Fig. 5E), with thin myelin sheaths centrally (Fig. 5F) compared with intact myelin outside these areas (Fig. 5G). Similar shadow plaquelike areas could occasionally also be seen on Luxol fast blue–periodic acid Schiff (note superior periventricular area around frontal horn, Fig. 2A). The MBP IHC on 5 different cortical and cerebellar sites did not reveal intracortical MS plaques.

The challenge of distinguishing 3 different demyelinating disorders from each other is obvious. Although active PML was not identified, the PML-IRIS did appear to be occurring in anatomical areas originally thought to be PML based on MRI (Figs. 1C–F). The cortical gray-white junction location of the PML-IRIS lesions, as well as the small perivascular lesions, was compatible with sites for previous PML. The PML-IRIS lesions, even when small, were hypercellular and contained a suffusion of parenchymal mononuclear cells, allowing distinction from burnt-out PML or chronic inactive or chronic inactive smoldering MS. Multiple sclerosis was easily diagnosed in areas where demyelination was periventricular and well-demarcated; however, in a few very small isolated lesions in brainstem and spinal cord, in sites where gross MS plaques were not identified, we could not totally exclude the possibility that some of the small lesions might be tiny active MS lesions and not PML-IRIS.

Autopsy Findings of Fatal PML-IRIS in the Spleen, Bone Marrow, and Liver

The spleen showed agonal expansion of the red pulp. The white pulp was not expanded, and there was no histological evidence of involvement by lymphoma. Bone marrow demonstrated mild hypercellularity for age, at approximately 70% to 80% average cellularity. There was trilineage hematopoiesis, but no focal lesion or lymphoma. The IHC analysis of marrow and spleen showed a normal relative frequency and

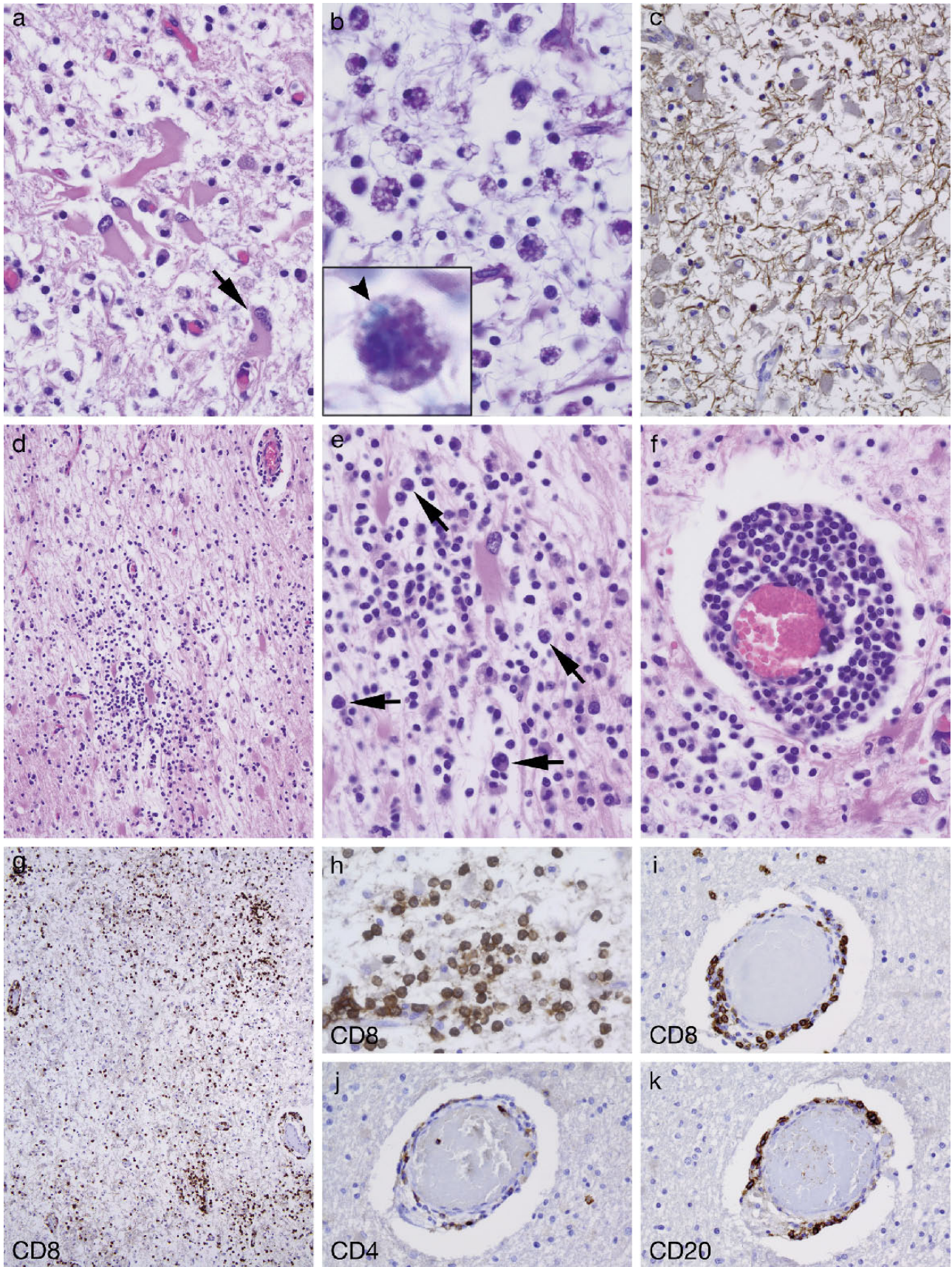
distribution of T cells and B cells in both tissues. In both, the T cells consisted of a normal mixture of CD4-positive and CD8-positive cells, with no significant loss of either CD5 or CD7. The liver was cirrhotic and featured a prominent infiltrate of lymphocytes within the fibrotic bands and portal tracts; typical histological features of viral hepatitis were absent. The infiltrating lymphocytes were predominantly T cells, with far fewer B cells that were limited to the portal tracts. Although it is common to have inflammation in the portal tracts (usually as an admixture of T cells and B cells with a predominance of T cells), in this case, an unusual feature was the presence of lymphocytes within the bands of bridging fibrosis: these were entirely T cells. The T cells consisted of a mixture of CD4-positive and CD8-positive cells, with a predominance of the CD4-positive cells.

Frozen splenic and bone marrow tissue samples underwent molecular analysis. Polymerase chain reaction assays of the T-cell receptor- γ gene were positive for a monoclonal T-cell population in both tissues (Fig. 6). The PCR assays of the immunoglobulin heavy chain gene identified polyclonal populations of B cells and were negative for a monoclonal B-cell population in both tissues. Because of the varying numbers of inflammatory cells in CNS lesions, paraffin-embedded tissues from brain with maximal inflammatory infiltrates were selected for similar T- and B-cell gene rearrangement studies, rather than the frozen banked brain tissues. The PCR showed polyclonal T- and B-cell populations in the brain (Fig. 6).

Interpretation of CNS Autopsy Findings, With Review of Literature of PML-IRIS in Natalizumab-Treated MS Patients

Our findings of PML-IRIS in a natalizumab-treated patient who survived almost 9 months after hospital discharge and 12 months after receipt of her last drug dose, qualitatively, but not quantitatively, parallel the findings of HAART-related IRIS in the AIDS population reported by Rushing et al (22). We also found overwhelming numbers of CD8-positive T lymphocytes in both parenchyma and perivascular sites (see Fig. 3H in [22]), limited numbers of CD4-positive and CD20-positive lymphocytes, and no mast cells. The profuse inflammation in our fatal case of MS natalizumab-related PML-IRIS parallels observations of overwhelming inflammation in fatal cases of HAART-related IRIS compared with lesser degrees of inflammation in survivors (22, 30).

Limited studies have been published on the histological features of PML-IRIS in natalizumab-treated MS patients, all of which derive from stereotactic biopsies performed in survivors at shorter intervals after drug withdrawal. Schwab et al (31) described a stereotactic biopsy performed approximately 3 months after initial PML diagnosis and after PLEX and steroid treatments. The patient had been clinically stable, but a massively progressive occipital lesion prompted biopsy. The JCV copy number was 6/mL, CSF cell count was less than 1 cell/ μ L, and histological examination showed actively demyelinating lesions and surrounding periplaque white matter both heavily infiltrated by CD8-positive T cells. Diffuse inflammation was noted within normal-appearing white matter.



The JCV immunoreactivity was not detected. Both B lymphocytes and plasma cells were also seen. Lenhard et al (32) reported a patient with an actively demyelinating lesion, pronounced axonal damage, no oligodendroglial intranuclear inclusions, negative IHC for JCV antigen, and negative JCV PCR on tissue. The largest report has been that of Metz et al (33) of 4 patients, all of whom underwent stereotactic biopsies 3 to 4 months, or less, after diagnosis of natalizumab-related PML-IRIS. They described similar features to previous authors, although high numbers of plasma cells were also found.

Comparing the current autopsy case with those cited above from the literature, several similarities and differences emerge. The autopsy specimen, as opposed to stereotactic biopsy, allowed for more recognition of gray matter damage overlying the white matter lesions. There was also a suggestion of overlap in anatomical location between the antecedent PML and the PML-IRIS. The long duration of PML-IRIS in our patient (9 months), nearly triple that in previously biopsied patients, likely accounts for the more cavitory appearance compared with that reported by Metz et al (33).

As in the reported literature examples, we found an absence of oligodendroglial viral inclusions, no cells that were IHC positive for JCV, scattered bizarre astrocytes similar to those seen in PML during viral replication phases, varying degrees of myelin loss, numerous CD8-positive T-cell lymphocytes, and both parenchymal and perivascular inflammatory infiltrates. Similar to the situation with HAART-related IRIS in patients with AIDS (22), the fatal nature of our autopsy case compared with the previously reported surviving patients may explain the more overwhelming numbers of CD8-positive lymphocytes in the autopsy case. Indeed, the unique and unfortunately fatal features of this case were the impetus for the extensive clinical, laboratory, and neuropathological details presented in this report.

Although caution needs to be exercised with a single case, our case suggests that PML-IRIS continued to be ongoing and had failed to become quiescent even after 9 months' duration. This was based on the intense inflammation and rare LFB-positive debris in macrophages. The absence of viral inclusions or IHC evidence of ongoing productive lytic JC viral infection at the autopsy suggests that the PML had indeed been controlled but at the price of extremely severe IRIS.

The intriguing finding of cortical neuronophagia, microglial clusters, and microglial activation raises issues about exposure to innate antigens within the brain as continual stimuli for the IRIS. Indeed, we noted the histological similarities to Rasmussen encephalitis. Additional examples

of longstanding fatal PML-IRIS will have to be studied to place the findings in the autopsy case in full perspective.

Interpretation of Non-CNS Autopsy Findings, Including Positive T-Cell Gene Rearrangement Studies in Peripheral Organ Sites

An additional interesting aspect of this case was the presence of a single monoclonal T-cell population within the spleen and bone marrow, although no monoclonal population was identified in the brain. Extensive histological and immunohistochemical evaluation of splenic tissue and marrow showed no evidence of overt T-cell lymphoma. Of note, however, we have recently published the first case of a peripheral T-cell lymphoma, not otherwise specified (34), in a natalizumab-treated MS patient (35). Clonal expansions of apparently reactive T cells may be found in many different reactive conditions and in normal persons (36). The threshold for defining when such conditions have become a true T-cell lymphoma is not well-defined, but a diagnosis of lymphoma would generally require a more diffuse mass-like infiltrate and/or a definite phenotypic abnormality of the T cells (34); neither of these was present in this case.

Why Might Natalizumab Treatment Lead to Overstimulation of Peripheral T Lymphocytes?

The mechanism of action of natalizumab is not fully understood. Clearly, a major component of its method of action relates to its blockade of CD49d (VLA4), which inhibits extravasation of lymphocytes and possibly monocytes in the CNS (37). Why the CNS is particularly dependent on CD49d-mediated transmigration for lymphocytes is unclear. It does not appear that the mechanism of action of natalizumab includes a major effect through MAdCAM-1 ($\alpha 4\beta 7$ integrin); thus, lymphocyte priming and expansion are relatively unaffected in natalizumab-treated patients (37). However, a number of effects on peripheral lymphocyte populations have been described in chronically treated patients that, in some cases, mimic changes seen during acute exacerbations, which may explain the postnatalizumab rebound in MS disease activity that has been reported (24–26, 38). These findings include increased production of the cytokines interferon- γ , interleukin 12p70 (IL-12p70), IL-4, IL-10, IL-5, and IL-13 in peripheral blood mononuclear cells (39). With chronic treatment, IL-17, IL-2, and IL-1 β production increases in stimulated peripheral

FIGURE 4. Fatal progressive multifocal leukoencephalopathy (PML)–immune reconstitution inflammatory syndrome (IRIS). **(A–G)** Rarefaction, macrophage accumulation, astrogliosis, and occasional astrocytes with mild nuclear atypia (**[A]** arrow), characterized cavitory white matter lesions of PML-IRIS. No intranuclear viral inclusions were found, and immunostaining for JCV on 3 different sections was negative. Macrophages predominantly contained periodic acid Schiff (PAS)–positive myelin debris, paralleling the chronicity of the process **(B)**, although rare Luxol fast blue (LFB)–positive material also could be identified, suggesting the ongoing nature of the PML-IRIS (**[B]** insert, arrowhead). Neurofilament immunohistochemistry (IHC) demonstrates axonal loss **(C)**, but there were no axonal swellings. The hypercellularity of the PML-IRIS lesions was largely caused by accumulations of mononuclear inflammatory cells both within parenchyma **(D, E)** and as thick perivascular cuffs **(F)**. These were predominantly lymphocytes, although scattered plasma cells were identified (**[E]** arrows), particularly in smaller lesions. No lymphoma or vasculitis was present **(F)**. Lymphocytes in parenchyma **(G, H)** and in perivascular cuffs **(I)** were overwhelmingly CD8-positive T cells, with fewer CD4-positive T cells **(J)** and CD20-positive B cells **(K)**; the latter were mostly confined to cuffs. Hematoxylin and eosin **(A), (D–F)**; LFB-PAS **(B)**; neurofilament IHC, **(C)**; CD8 IHC **(G–I)**; CD4 IHC **(J)**; CD20 IHC **(K)**. Magnifications: **(A, B, E, F, H)** 600 \times ; **(C, I–K)**, 400 \times ; **(D)** 200 \times ; **(G)** 100 \times .

blood mononuclear cells (39). Similarly, in chronic natalizumab therapy, CD4-positive, PSTAT1-positive, CD4-positive, PSTAT3-positive, CD8-positive, PSTAT1-positive, CD4-positive, T-Bet-positive, and CD8-positive, T-Bet-positive cells increase in the peripheral blood in a pattern reminiscent of patterns seen during acute MS relapses (38). CD4-positive, CD25-positive T-regulatory cells (Treg) also express VLA-4 but at lower levels than that in CD4-positive T lymphocytes. With chronic treatment, CD4-positive, CD25-positive, FoxP3-positive Treg populations decrease in the peripheral blood, although Treg function is relatively unaffected (40, 41). B-lymphocyte populations actually demonstrate larger effects of natalizumab treatment. B lymphocytes express higher levels of CD49d than T cells, and there is a larger increase in circulating populations of B cells than T cells, particularly in the immature B cell (CD19-positive, CD10-positive) phenotype (42, 43). Finally, binucleated lymphocytes are common in the peripheral blood of natalizumab-treated patients (44), numbers of CD34-positive hematopoietic stem cell in peripheral blood are increased 6-fold (45), and gene expression profiles are changed related to lymphocyte, neutrophil and erythrocyte function (28). The implications of any of these findings for the risk of developing lymphoma in natalizumab-treated MS patients are unknown.

Does IRIS Develop On Withdrawal of Natalizumab Alone, Even in the Absence of PML?

Even without serology-documented PML, some MS patients develop a paradoxical worsening of clinical symptoms after cessation of natalizumab, suggesting that IRIS can occur even if there is no productive lytic viral infection or viral antigen to drive the process. This “CNS IRIS sans PML infection” is sometimes referred to as the “natalizumab withdrawal syndrome.” Central nervous system-IRIS has been reported among natalizumab-treated patients who undergo voluntary discontinuation of therapy. Miravalle et al (25) prospectively evaluated 32 patients with MS who had received at least 12 consecutive natalizumab infusions and underwent voluntary drug suspension. Almost 40% of those patients experienced acute worsening of neurological functions, with MRI evidence of active inflammation, usually 3 to 4 months after the last dose of the drug. Of interest, the degree of MS-related disease activity in these patients was significantly worse than expected based on prenatalizumab levels. Patients experiencing a relapse of their MS disease activity during this interval tended to be younger, with a shorter duration of natalizumab therapy before therapy interruption, although this was a modest finding ($p = 0.05$). In all cases, high-dose i.v. methylprednisolone was instituted, with various degrees of clinical recovery. A single case reported recently described the appearance of new-onset tetraparesis in a young patient 9 weeks after discontinuation of natalizumab therapy because of her wishes to become pregnant (32). The brain MRI scan demonstrated multiple new T1-enhancing lesions. She remained symptomatic, with significant worsening of neurological functions despite aggressive treatment with i.v. methylprednisolone and PLEX. Even 3 months after natalizumab cessation, the MRI

scan continued to demonstrate newly evolving, gadolinium-enhancing lesions with further clinical worsening. JCV PCR in CSF was negative, suggesting that no viral antigenic presentation was involved in the pathogenesis of this inflammatory response. In addition, the CD4/CD8 ratio was decreased in CSF, supporting the diagnosis of IRIS.

A more recent series of natalizumab-treated patients who underwent voluntary drug discontinuation has also been reported (46). Of the 68 patients who underwent dosage interruption, 19 experienced a relapse within 6 months of the suspension. Of those, 7 patients had an “unusually” severe deficit, with large number of gadolinium-enhancing lesions on MRI (mean, 16 lesions). Again, in these cases, JCV was not found in either serum or CSF samples. The median time to development of CNS-IRIS sans PML/“natalizumab rebound effect” in these 7 patients was 3 months.

In contrast to these findings, O'Connor et al (47) retrospectively analyzed disease activity after natalizumab discontinuation as part of AFFIRM, SENTINEL, and GLANCE clinical trials. This was a post hoc analysis of patients who received natalizumab therapy during clinical trials, and the comparison was made of the amount of disease activity developed during treatment interruption to levels of disease activity observed in patients receiving placebo. After reviewing more than 1,800 patients, the authors concluded that the amount of MS disease activity seen after natalizumab discontinuation was similar to pretreatment levels, suggesting that return of MS disease activity rather than IRIS/rebound effect occurs in patients who discontinue natalizumab therapy and do not receive alternative MS treatments. Thus, debate continues among neurologists as to whether some of the clinical worsening in patients after natalizumab withdrawal is caused by CNS-IRIS or worsening of their MS if the patient is not placed on other MS-ameliorating medications to cover his or her underlying disease.

CONCLUSIONS

The number of reported cases of PML related to natalizumab therapy in MS patients has not abated since the condition was first described in 2005. Survival of PML in natalizumab-treated patients is significantly better than for PML in patients with AIDS at the height of the AIDS epidemic but is still the cause of significant morbidity and mortality. The very recent reports of asymptomatic PML in patients with natalizumab-treated MS discovered as a result of close monitoring of patients using the medication offers promise that the diagnosis of PML can be made earlier. Thus, morbidity and mortality may improve. Even if earlier diagnosis of PML becomes the norm, however, clinical problems remain for the MS natalizumab-treated population.

The PML-related IRIS has emerged as a clinically significant condition on withdrawal of natalizumab, usually after receipt of PLEX to eliminate drug from the circulation. The PML-IRIS itself causes significant morbidity and mortality. Intravenous methylprednisolone is the usual treatment for PML-IRIS. Whether T-cell abnormalities are a rarity (35), or will over time also prove to be a problem in PML-IRIS patients, is unknown. The development of neurological deterioration after cessation of drug, even in cases without PML,

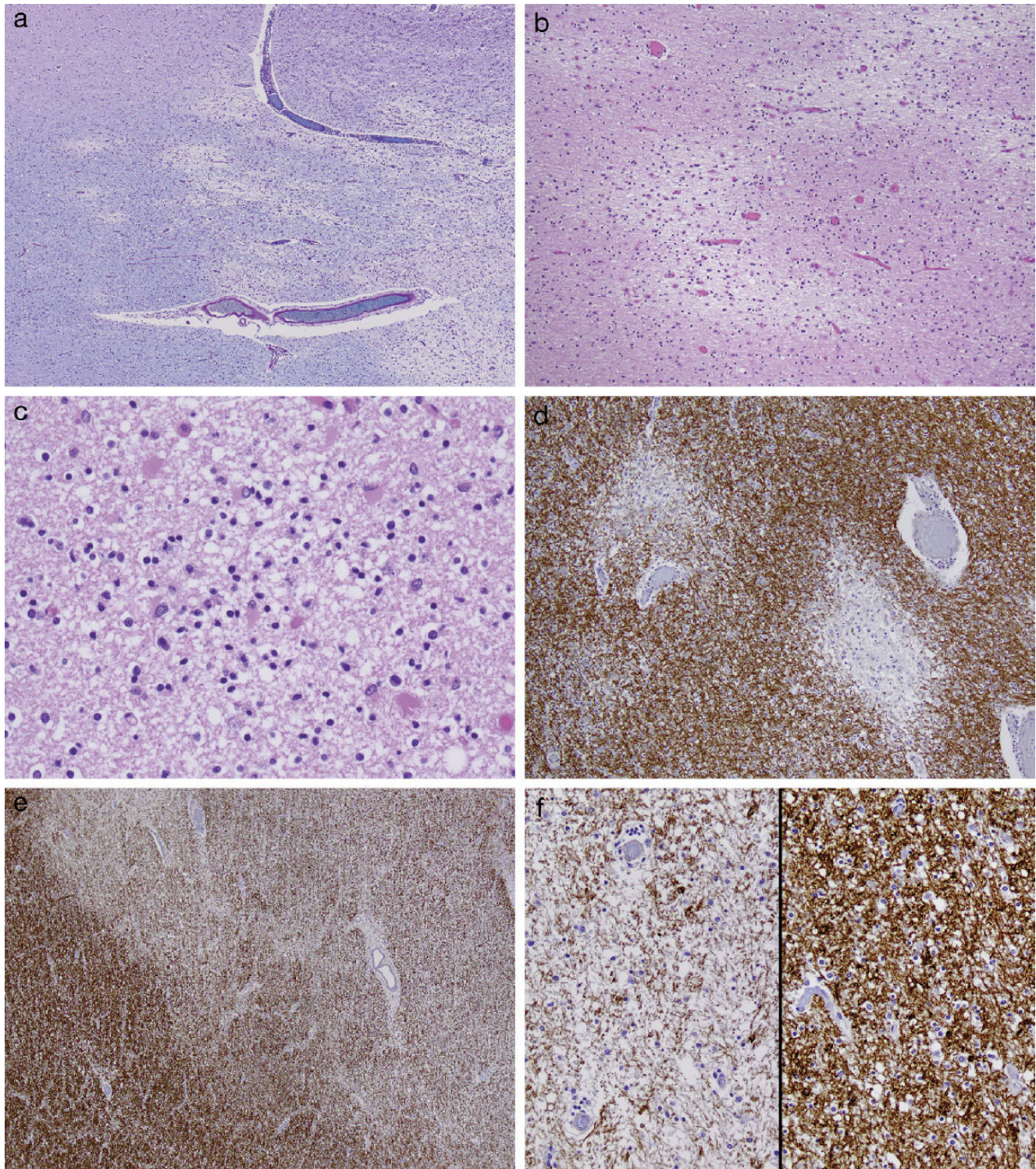


FIGURE 5. Fatal progressive multifocal leukoencephalopathy (PML)–immune reconstitution inflammatory syndrome (IRIS). **(A)** Small ovoid perivascular areas of myelin loss on Luxol fast blue (LFB)–periodic acid Schiff (PAS) at the edges of a larger PML-IRIS lesion (extreme lower right), consistent with PML-IRIS. **(B, C)** The small lesions are hypercellular but do not have viral inclusions. **(D)** The smallest lesions were best identified with immunostaining for myelin basic protein (MBP). **(E)** Larger ill-defined areas of myelin pallor were also confirmed by MBP immunostaining. **(F, G)** Based on the thinly myelinated sheaths seen centrally, they probably represent multiple sclerosis shadow plaques **(F)** compared with intact myelin at their periphery **(G)**. LFB-PAS **(A)**; hematoxylin and eosin **(B, C)**; MBP immunohistochemistry **(D–G)**. Magnifications: **(A, E)** 40×; **(B, D)** 100×; **(C)** 400×; **(F, G)** 200×.

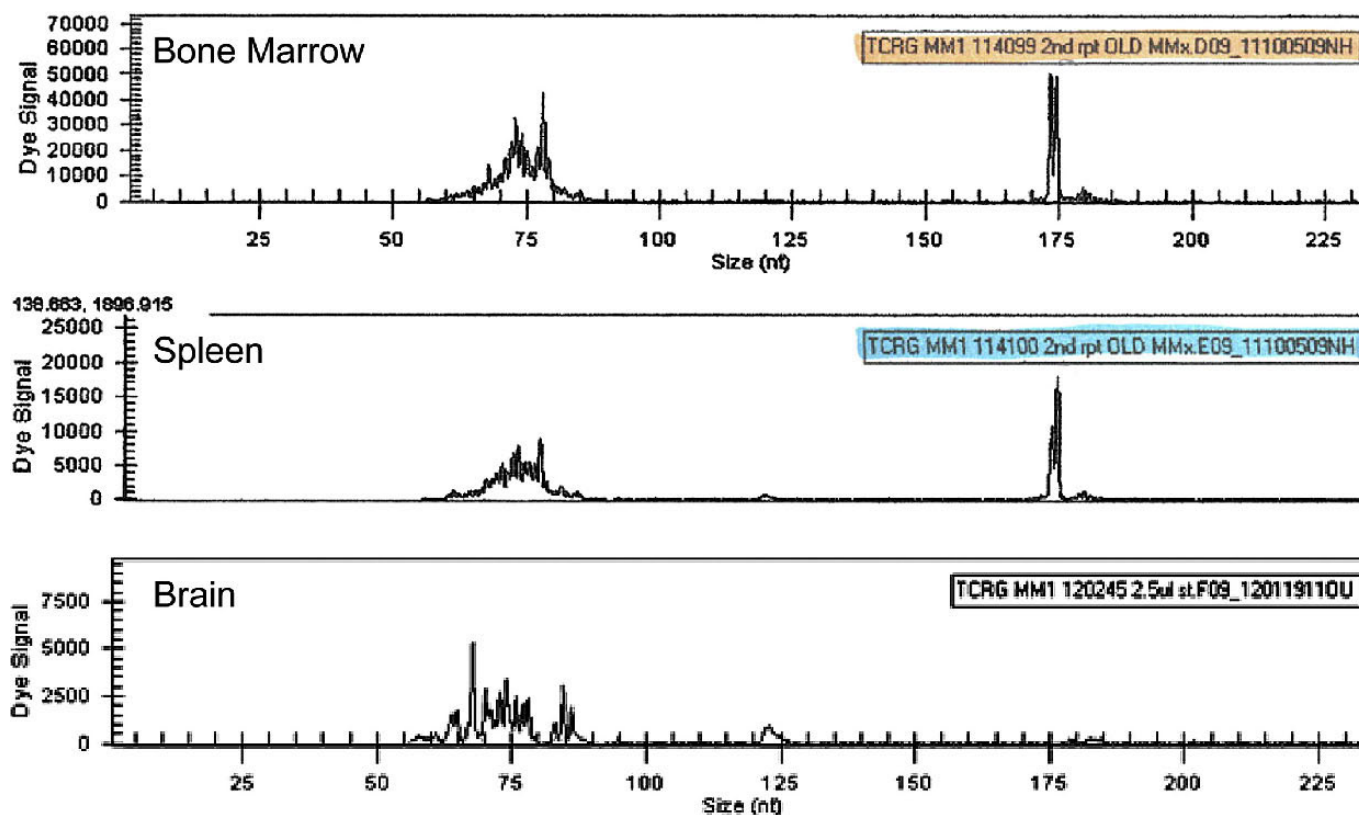


FIGURE 6. (A–C) Polymerase chain reaction for T-cell gene rearrangement shows clonal T-cell populations in the autopsy bone marrow **(A)** and spleen **(B)**, but not in the brain **(C)**. T-cell lymphoma could not be identified in organ sites.

has led to a debate as to whether CNS-IRIS can occur without previous viral infection, the so-called natalizumab rebound effect. Alternatively, patients may develop neurological deterioration after drug withdrawal simply because of worsening of their underlying MS now that this highly clinically effective medication has been withdrawn.

ACKNOWLEDGMENTS

The authors thank Ms Marcia Sabo for manuscript preparation and Ms Lisa Litzenberger for photographic expertise.

REFERENCES

- Berger JR, Houff S. Opportunistic infections and other risks with newer multiple sclerosis therapies. *Ann Neurol* 2009;65:367–77
- Polman CH, Reingold SC, Banwell B, et al. Diagnostic criteria for multiple sclerosis: 2010 revisions to the McDonald criteria. *Ann Neurol* 2011; 69:292–302
- Rudick RA, Stuart WH, Calabresi PA, et al. Natalizumab plus interferon beta-1a for relapsing multiple sclerosis. *N Engl J Med* 2006;354:911–23
- Kleinschmidt-DeMasters BK, Tyler KL. Progressive multifocal leukoencephalopathy complicating treatment with natalizumab and interferon beta-1a for multiple sclerosis. *N Engl J Med* 2005;353:369–74
- Langer-Gould A, Atlas SW, Green AJ, et al. Progressive multifocal leukoencephalopathy in a patient treated with natalizumab. *N Engl J Med* 2005; 353:375–81
- Van Assche G, Van Ranst M, Sciort R, et al. Progressive multifocal leukoencephalopathy after natalizumab therapy for Crohn's disease. *N Engl J Med* 2005;353:362–8
- BiogenIdec: <https://medinfo.biogenidec.com>. 2012. Accessed May 30, 2012.
- Phan-Ba R, Lommers E, Tshibanda L, et al. MRI preclinical detection and asymptomatic course of a progressive multifocal leukoencephalopathy (PML) under natalizumab therapy. *J Neurol Neurosurg Psychiatry* 2012;83:224–6
- Blair NF, Brew BJ, Halpern JP. Natalizumab-associated PML identified in the presymptomatic phase using MRI surveillance. *Neurology* 2012; 78:507–8
- Ayzenberg I, Lukas C, Trampe N, et al. Value of MRI as a surrogate marker for PML in natalizumab long-term therapy. *J Neurol* 2012; [Epub ahead of print]
- Bergamaschi R, Montomoli C. Melanoma in multiple sclerosis treated with natalizumab: Causal association or coincidence? *Mult Scler* 2009; 15:1532–3
- Ismail A, Kemp J, Sharrack B. Melanoma complicating treatment with natalizumab (Tysabri) for multiple sclerosis. *J Neurol* 2009;256: 1771–2
- Laroni A, Bedognetti M, Uccelli A, et al. Association of melanoma and natalizumab therapy in the Italian MS population: A second case report. *Neurol Sci* 2011;32:181–2
- Mullen JT, Vartanian TK, Atkins MB. Melanoma complicating treatment with natalizumab for multiple sclerosis. *N Engl J Med* 2008;358: 647–8
- Panzara MA, Bozic C, Sandrock AW. More on melanoma with trans-differentiation. *N Engl J Med* 2008;359:99; [author reply -100]
- Schweikert A, Kremer M, Ringel F, et al. Primary central nervous system lymphoma in a patient treated with natalizumab. *Ann Neurol* 2009;66:403–6
- Vavricka BM, Baumberger P, Russmann S, et al. Diagnosis of melanoma under concomitant natalizumab therapy. *Mult Scler* 2011;17:255–6
- Zecca C, Nessi F, Bernasconi E, et al. Ocular toxoplasmosis during natalizumab treatment. *Neurology* 2009;73:1418–9
- Stuve O, Wiendl H. Iatrogenic immunosuppression with biologics in MS: Expecting the unexpected? *Neurology* 2009;73:1346–7

20. Shelburne SA 3rd, Hamill RJ, Rodriguez-Barradas MC, et al. Immune reconstitution inflammatory syndrome: Emergence of a unique syndrome during highly active antiretroviral therapy. *Medicine (Baltimore)* 2002; 81:213–27
21. Shelburne SA, Visnegarwala F, Darcourt J, et al. Incidence and risk factors for immune reconstitution inflammatory syndrome during highly active antiretroviral therapy. *AIDS* 2005;19:399–406
22. Rushing EJ, Liappis A, Smirniotopoulos JD, et al. Immune reconstitution inflammatory syndrome of the brain: Case illustrations of a challenging entity. *J Neuropathol Exp Neurol* 2008;67:819–27
23. Tan IL, McArthur JC, Clifford DB, et al. Immune reconstitution inflammatory syndrome in natalizumab-associated PML. *Neurology* 2011; 77:1061–7
24. Perumal J, Hreha S, Bao F, et al. Post-natalizumab associated rebound or CNS immune reconstitution syndrome: Clinical and MRI findings. *Mult Scler* 2009;15:S119
25. Miravalle A, Jensen R, Kinkel RP. Immune reconstitution inflammatory syndrome in patients with multiple sclerosis following cessation of natalizumab therapy. *Arch Neurol* 2011;68:186–91
26. Vellinga MM, Castelijns JA, Barkhof F, et al. Postwithdrawal rebound increase in T2 lesional activity in natalizumab-treated MS patients. *Neurology* 2008;70:1150–1
27. Johnson T, Nath A. Immune reconstitution inflammatory syndrome and the central nervous system. *Curr Opin Neurol* 2011;24:284–90
28. Lindberg RL, Achtnichts L, Hoffmann F, et al. Natalizumab alters transcriptional expression profiles of blood cell subpopulations of multiple sclerosis patients. *J Neuroimmunol* 2008;194:153–64
29. Clifford DB, De Luca A, Simpson DM, et al. Natalizumab-associated progressive multifocal leukoencephalopathy in patients with multiple sclerosis: Lessons from 28 cases. *Lancet Neurol* 2010;9:438–46
30. Langford TD, Letendre SL, Marcotte TD, et al. Severe, demyelinating leukoencephalopathy in AIDS patients on antiretroviral therapy. *AIDS* 2002;16:1019–29
31. Schwab N, Hohn KG, Schneider-Hohendorf T, et al. Immunological and clinical consequences of treating a patient with natalizumab. *Mult Scler* 2012;18:335–44
32. Lenhard T, Biller A, Mueller W, et al. Immune reconstitution inflammatory syndrome after withdrawal of natalizumab? *Neurology* 2010;75:831–3
33. Metz I, Radue EW, Oterino A, et al. Pathology of immune reconstitution inflammatory syndrome in multiple sclerosis with natalizumab-associated progressive multifocal leukoencephalopathy. *Acta Neuropathol* 2012;123: 235–45
34. Swerdlow SH, Campo E, Harris NL, et al, ed. WHO Classification of Tumours of Haematopoietic and Lymphoid tissues, Fourth Edition. Lyon: IARC, 2008;417
35. Schowinsky J, Corboy J, Vollmer T, et al. Natalizumab-associated complication? First case of peripheral T-cell lymphoma. *Acta Neuropathol* 2012;123:751–2
36. Posnett DN, Sinha R, Kabak S, et al. Clonal populations of T cells in normal elderly humans: The T-cell equivalent to “benign monoclonal gammopathy”. *J Exp Med* 1994;179:609–18
37. Bauer M, Brakebusch C, Coisne C, et al. Beta1 integrins differentially control extravasation of inflammatory cell subsets into the CNS during autoimmunity. *Proc Natl Acad Sci USA* 2009;106:1920–5
38. Frisullo G, Iorio R, Plantone D, et al. CD4⁺T-bet⁺, CD4⁺pSTAT3⁺ and CD8⁺T-bet⁺ T cells accumulate in peripheral blood during NZB treatment. *Mult Scler* 2011;17:556–66
39. Ramos-Cejudo J, Oreja-Guevara C, Stark Aroeira L, et al. Treatment with natalizumab in relapsing-remitting multiple sclerosis patients induces changes in inflammatory mechanism. *J Clin Immunol* 2011;31:623–31
40. Putzki N, Baranwal MK, Tettenborn B, et al. Effects of natalizumab on circulating B cells, T regulatory cells and natural killer cells. *Eur Neurol* 2010;63:311–7
41. Stenner MP, Waschbisch A, Buck D, et al. Effects of natalizumab treatment on Foxp3⁺ T regulatory cells. *PLoS One* 2008;3:e3319
42. Krumbholz M, Meinel I, Kumpfel T, et al. Natalizumab disproportionately increases circulating pre-B and B cells in multiple sclerosis. *Neurology* 2008;71:1350–4
43. Lesesve JF, Debouverie M, Decarvalho Bittencourt M, et al. CD49d blockade by natalizumab therapy in patients with multiple sclerosis increases immature B-lymphocytes. *Bone Marrow Transplant* 2011;46: 1489–91
44. Leclerc M, Lesesve JF, Gaillard B, et al. Binucleated lymphocytes in patients with multiple sclerosis treated with natalizumab. *Leuk Lymphoma* 2011;52:910–2
45. Bonig H, Wundes A, Chang KH, et al. Increased numbers of circulating hematopoietic stem/progenitor cells are chronically maintained in patients treated with the CD49d blocking antibody natalizumab. *Blood* 2008;111:3439–41
46. West TW, Cree BA. Natalizumab dosage suspension: Are we helping or hurting? *Ann Neurol* 2008;68:395–9
47. O’Connor PW, Goodman A, Kappos L, et al. Disease activity return during natalizumab treatment interruption in patients with multiple sclerosis. *Neurology* 2011;76:1858–65

Downloaded from https://academic.oup.com/jnen/article/71/7/604/2950731 by guest on 12 April 2024