

Ruptured Aneurysm With Delayed Distal Coil Migration Requiring Surgical Treatment

—Case Report—

Hajime WADA,¹ Naoki TOKUMITSU,² Wakako SHIRAI,²
Kazuhiro SAKO,² and Kyousuke KAMADA¹

¹Department of Neurosurgery, Asahikawa Medical University, Asahikawa, Hokkaido;

²Department of Neurosurgery, Nayoro City General Hospital, Asahikawa, Hokkaido

Abstract

A 64-year-old woman with subarachnoid hemorrhage manifesting as sudden onset of severe headache visited our hospital on post-onset day 8. Diagnostic cerebral digital subtraction angiography revealed an aneurysm located at the left internal carotid-anterior choroidal artery with diffuse cerebral arterial spasm. Coil embolization was selected because of diffuse spasm in spite of parent artery elongation at the extra-cranial portion. A small portion of the coil migrated to the parent artery, but coil embolization was successfully completed. The patient developed delayed spasm, which required arterial fasudil hydrochloride injection. After the acute phase of subarachnoid hemorrhage, the patient's symptoms disappeared. However, on day 24 after subarachnoid hemorrhage, the patient showed right hemiparesis and total aphasia, and skull radiography revealed that the migrated coil had moved into the M1 portion of the left middle cerebral artery. Craniotomy was performed to retrieve the coil and clip the aneurysm neck. However, the migrated coil could not be retrieved because of adhesion to the arterial wall. Delayed coil migration is very rare in the chronic phase.

Key words: subarachnoid hemorrhage, coil embolization, delayed coil migration, clipping, complication

Introduction

The International Subarachnoid Aneurysm Trial (ISAT) is the only multi-center prospective randomized clinical trial, considered the gold-standard in study design, comparing surgical clipping and endovascular coiling of ruptured aneurysm. The ISAT found that patients equally suited for both treatment options achieved substantially better outcomes after endovascular coiling treatment than after surgery in terms of survival-free disability at one year. However, the coiling technique is technically developing and continues to carry risks of unexpected complications. Coil migration is one of the rare complications, but might be related to poor functional outcome. Therefore, evaluation techniques such as volume embolization ratio (VER) and new embolization devices have been developed to improve aneurysm stability after endovascular treatment with platinum coils.

We describe a case of bizarre coil migration in a patient with a ruptured internal carotid-anterior choroidal artery aneurysm treated by surgical excision of the migrated part for rescue treatment.

Case Report

A 64-year-old woman visited the emergency service of Nayoro City Hospital because of severe headache persisting for a week. She had suffered sudden onset of headache and nausea for 8 days. Head computed tomography (CT) demonstrated residual clot in the subarachnoid space (Fig. 1A, B; Fisher group 3), and the diagnosis was subarachnoid hemorrhage (SAH) on the 8th day after occurrence (Hunt and Kosnik grade 2). Emergent angiography revealed an aneurysm at the left internal carotid-anterior choroidal artery (4.5 × 5.4 × 3.2 mm, neck: 3.9 mm) with severe intracranial arterial vasospasm (Fig. 1C). In addition, the internal carotid artery (ICA) in the cervical portion was tortuous and had a loop, which suggested difficulty in accessing the aneurysm by the endovascular approach (Fig. 1D). However, considering the vessel structure anomaly and vasospasm, we selected aneurysm embolization by endovascular coils.

Under general anesthesia, a Slimguide catheter (6 Fr; Medikit, Tokyo) with a 6-Fr sheath was inserted via the right femoral artery and positioned at the proximal portion of the cervical ICA. An Excelsior SL-10® 45 pre-shaped microcatheter (Stryker Neurovascular, Fremont, California, USA) was carefully navigated to the aneurysm using a Synchro² Soft 0.014 micro guidewire (Stryker Neu-

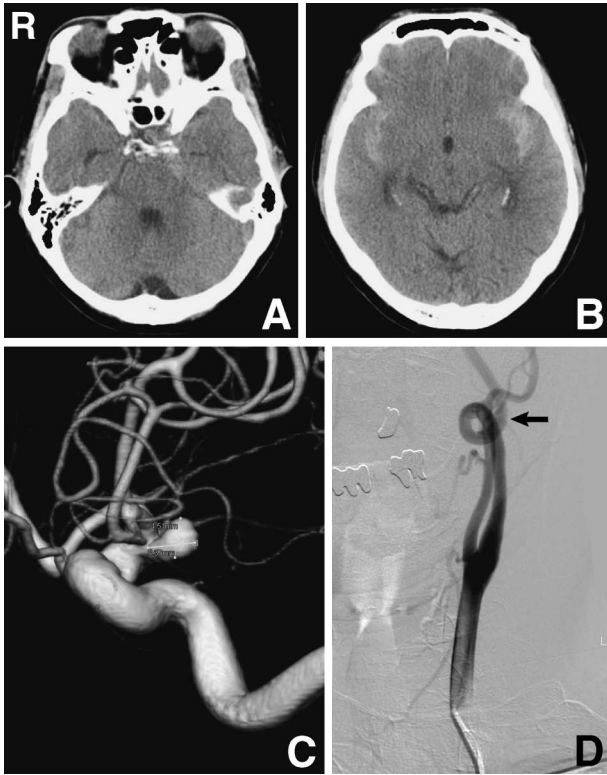


Fig. 1 A, B: Computed tomography scans on admission showing subarachnoid hemorrhage. C: Three-dimensional digital subtraction angiogram revealing an anterior choroidal artery aneurysm. D: Left common carotid angiogram showing coiling of the extracranial internal carotid artery (arrow).

rovascular). For the first coiling, a cage formation was created inside the aneurysm using DCS complex fill 5×5 (Cordis Corporation, Bridgewater, New Jersey, USA) (Fig. 2). After successful cage formation, flexible platinum coils were introduced such as DCS mini-complex fill 3×4 coils to fill the inner cavity of the aneurysm, and moderate aneurysm packing was confirmed. After intravenous administration of 3,000 units of heparin, GDC UltraSoft 3×4 coils (Stryker Neurovascular) were inserted for complete embolization. The last coil was too soft and redundant, resulting in a loop which protruded into the parent artery and pushed the microcatheter away from the aneurysm. Although we tried to achieve complete packing using a shorter coil (GDC UltraSoft 2×2), the aneurysm neck was too wide to hold the looped coil, and coil manipulation was severely disturbed by the cervical ICA anomaly. We abandoned further procedures because blocking of the blood flow into the aneurysm had been completed, and we planned to observe the remaining coil loop. The total coil length was 9 cm, and the VER was 17.4%.

After the endovascular treatment, the patient had no neurological deficit. Cerebrospinal fluid was continuously drained with intrathecal administration of urokinase (6,000 units/day) and aspirin (100 mg/day) was orally administered to prevent deterioration of vasospasm. Two days later (10th day after onset), she suffered right hemipa-

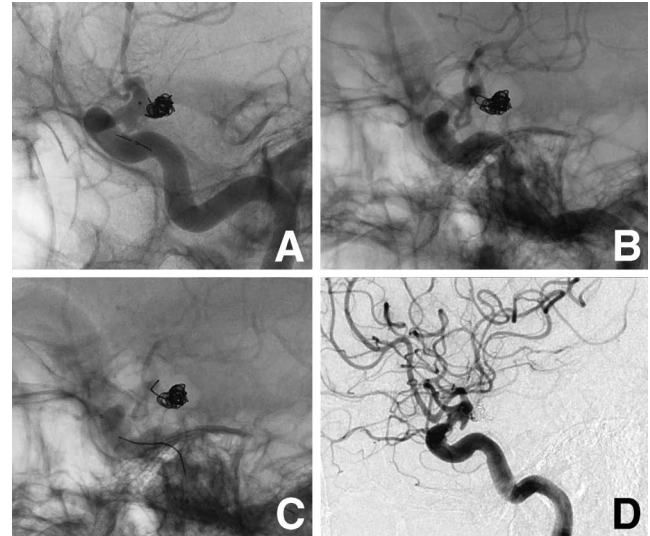


Fig. 2 A-C: Left internal carotid angiograms, lateral view, showing placing the 3rd coil into the aneurysm (A), but a loop protruded into the left internal carotid artery (B). The loop was unraveled and moved into the left internal carotid artery (C). Then, we abandoned detaching the fourth coil. D: Post-coil embolization subtraction image showing only a small neck remnant, so we decided that this operation should be abandoned.

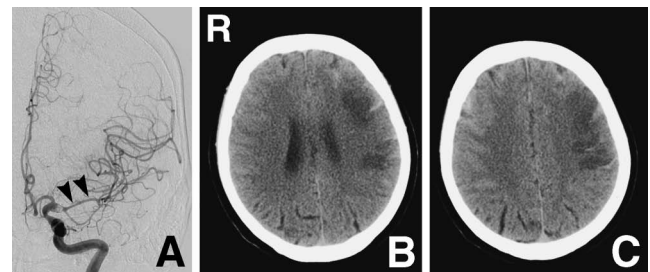


Fig. 3 A: Left carotid angiogram, anteroposterior view, before arterial injection of 30 mg of fasudil hydrochloride on day 10 revealing delayed arterial spasm (arrowheads). B, C: Computed tomography scans on day 10 showing low density areas in the left frontal lobe.

resis and aphasia, and emergent cerebral angiography disclosed narrowing of the bilateral anterior cerebral arteries and middle cerebral arteries (MCAs) (Fig. 3A). Severe vasospasm was considered to be the cause of the symptoms and 30 mg of fasudil hydrochloride was administered via the 4-Fr angiographic catheter. No displacement or migration of the coils in the aneurysm and improvement of vasospasm were confirmed. The symptoms persisted until the 12th day and head CT revealed a low density area in the left frontal region (Fig. 3B, C). Cerebral angiography was repeated and 30 mg of fasudil hydrochloride injected into the left ICA for symptomatic vasospasm. The coil shape including the protrusion maintained stable. After the 3rd angiography, she gradually

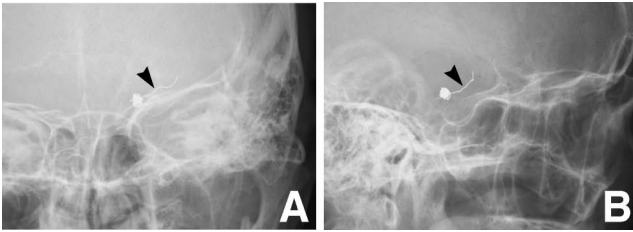


Fig. 4 Skull radiographs, Town's (A) and lateral views (B), on day 24 showing the migrated coil portion (arrowhead).

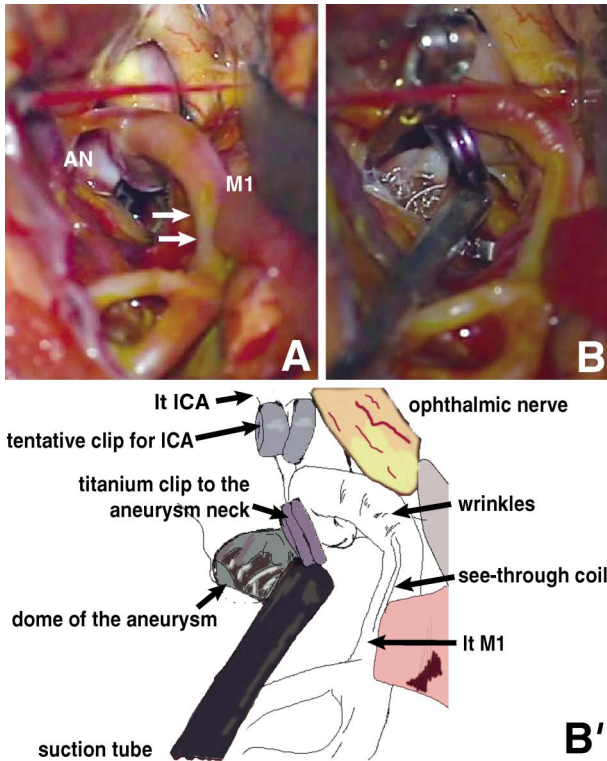


Fig. 5 Intraoperative photographs. **A:** After opening the left sylvian fissure, the migrated coil was seen through the middle cerebral arterial wall (arrows). AN: aneurysm dome, M1: M1 portion of left middle cerebral artery. **B:** A clip was applied to the neck of the aneurysm, and the cut anterior aneurysm wall and coils were seen. The clip head was opened slightly, to try to retrieve the migrated coil. However, the coil was adhered to the arterial wall. When the coil was pulled, a wrinkle was caused on the wall of the M1 artery. The coil could not be removed. **B':** Illustration of B. ICA: internal carotid artery.

recovered from the symptoms. In the early morning of the 24th day after onset, severe right hemiparesis and total aphasia suddenly appeared. Emergent magnetic resonance (MR) imaging demonstrated no new lesion on diffusion-weighted images except for old ischemic changes due to the vasospasm. MR angiography showed uncertain signal loss between the peripheral portion of the left ICA and the proximal site of the MCA. Radiography depicted part of the embolization coils was stretched and

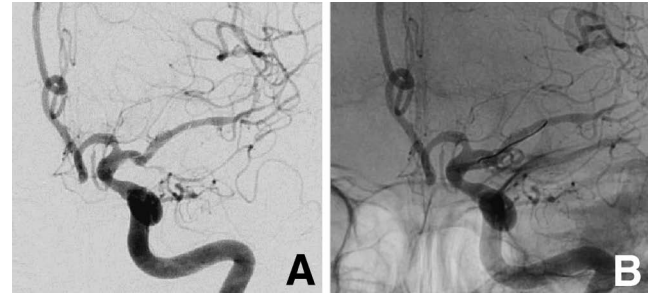


Fig. 6 Left internal carotid angiograms, anteroposterior view, showing no aneurysm in the digital subtraction image (A), and the remaining coil and clips (B).

had migrated from the aneurysm neck to the MCA (Fig. 4). Although the symptoms diminished within 6 hours without special treatment, we decided to retrieve the migrated part of the coils by open surgery, to avoid embolic events or arterial wall injury and aneurysm re-rupture.

The left ICA and the aneurysm were exposed by left fronto-temporal craniotomy and part of the migrated coil was observed between the ICA top and proximal MCA (Fig. 5). After temporary clips were placed at the proximal and distal sites of the aneurysm on the ICA, the translucent aneurysm sac was opened for complete removal of the coils. However, the entire coil was impossible to withdraw because of severe adhesion between the migrated part and the MCA arterial wall. As the coil was pulled, a wrinkle was caused on the wall of the M1 artery. Therefore, we removed only the coils in the aneurysm, preventing further coil migration, since aggressive manipulation might worsen arterial wall injury. Aneurysm clipping was achieved with 2 titanium clips (Yasargil 720T; Aesculap AG, Tuttlingen, Germany) and the coil remnant was cut at the aneurysm neck inlet, leaving the migrated part in the M1. Postoperative angiography demonstrated 8 mm of the remnant coil remained between the ICA top and proximal MCA with complete aneurysm clipping (Fig. 6). Six months after the open surgery, she had suffered no new neurological deficit, and the remnant coil had not migrated or caused any new ischemic event.

Discussion

The present case of SAH caused by a ruptured aneurysm and associated with severe vasospasm initially treated with endovascular embolization. Although serial angiography showed no deformity or dislocation of the coils during the acute period, coil migration was found more than 3 weeks after the embolization. The superiority of coil embolization over clipping for ruptured aneurysms within 2 years after onset has been proposed. In particular, the endovascular procedure causes fewer ischemic complications during the vasospasm phase in patients with SAH.^{1,7)} In this case, coil embolization was appropriate to avoid re-bleeding in the acute period.

In general, migration of the coil outside the aneurysm is caused by stopping packing while the coil partially pro-

trudes. Other causes are wide aneurysm neck or loose packing of coils. We could not help ending in such a situation in the acute stage. If a little more coil can be packed into the aneurysm tightly regardless of the coil type, this complication would not occur. Assisting techniques with balloon or stent are effective and used worldwide to reduce migration of the coil. On the other hand, delayed coil migration after embolization has been recently reported. There are two main reasons for the migration. One reason is the stent technique used with the embolization.^{2,4)} Although stent devices are expected to stably support embolizing coils, fine coils might escape from the stent struts with loose mesh design. The other reason is the combination of the ultrasoft coil, which was recently developed for better embolization, and the balloon remodeling technique.^{3,5,8)} This technique may simply compress the ultrasoft coils in the coil complex by the balloon. In our case, no stent, balloon, or ultrasoft coil was used. Therefore, our endovascular strategy had less risk of coil migration than previous methods. Coil migration usually occurs during or within a day after the embolization procedure (acute phase). Since vessel endothelium cells might proliferate within a week after treatment, the coils might become stable in the subacute phase. Delayed coil migration, as experienced in the present case, is relatively rare. Surgical removal failed to retrieve the migrated coils because of severe adhesion related to endothelial proliferation and inflammation on the arterial wall. On the basis of our experience, we have to carefully check for coil migration, even some weeks after completing treatment with no negative occurrences.

Our patient had two associated pathological conditions, vasospasm and tortuous cervical ICA. In particular, the tortuous cervical ICA hindered balloon remodeling and fine control of the microcatheter. As a result, the coil packing ratio did not reach adequate values. Such multiple factors might still make endovascular treatment complex. Catheterization to treat peripheral severe tortuous arteries is difficult. Treatment must be planned on the assumption of difficulty in using a balloon in the acute phase, and the possibility of clipping. To employ catheterization to complete treatment without a balloon, we should use a triple coaxial system, such as the Cerulean catheter (Medikit), or the head position should be rotated beforehand to release coiling of the cervical ICA.

The coil placed in the aneurysm was displaced and embolization became incomplete, so we performed craniotomy and clipping to prevent re-rupture. Coil embolectomy, vessel repair, and clipping of the aneurysm are necessary for surgical treatment after such distal coil migration. Coil embolectomy and neck clipping is the optimum treatment strategy. However, removal of intravascular coils is not always possible due to adhesion to the arterial wall. Symptomatic arterial stenosis has been caused by a coil which migrated into the peripheral artery during an operation.⁶⁾ Therefore, surgical management that considers even revascularization procedures such as superficial temporal artery-MCA bypass is necessary. Coil manipulation should be carefully performed because the

dynamics of coils inserted into the human body are difficult to predict.^{9,10)}

The present patient with SAH was treated with coil embolization in the spasm phase, but part of a protruding coil migrated distally in the chronic phase. Although endovascular treatment is useful for SAH in the spasm phase, application may be difficult in some cases and should be carefully performed. If a protruding coil is detected at the finish of endovascular treatment, we should consider additional endovascular treatment in the chronic stage. Surgical treatment of a migrating coil may be difficult due to adhesion to the vascular wall.

References

- 1) Brisman JL, Roonprapunt C, Song JK, Niimi Y, Setton A, Berenstein A, Flamm ES: Intentional partial coil occlusion followed by delayed clip application to wide-necked middle cerebral artery aneurysms in patients presenting with severe vasospasm. Report of two cases. *J Neurosurg* 101: 154-158, 2004
- 2) Cho CS: Coil migration under stent-assisted embolization. A case report. *Interv Neuroradiol* 12: 65-68, 2006
- 3) Fiorella D, Kelly ME, Moskowitz S, Masaryk TJ: Delayed symptomatic coil migration after initially successful balloon-assisted aneurysm coiling: technical case report. *Neurosurgery* 64: E391-E392, 2009
- 4) Gao BL, Li MH, Wang YL, Fang C: Delayed coil migration from a small wide-necked aneurysm after stent-assisted embolization: case report and literature review. *Neuroradiology* 48: 333-337, 2006
- 5) Haraguchi K, Houkin K, Nonaka T, Baba T: Delayed thromboembolic infarction associated with reconfiguration of Guglielmi detachable coils—case report. *Neurol Med Chir (Tokyo)* 47: 79-82, 2007
- 6) Meguro T, Sasaki T, Haruma J, Tanabe T, Muraoka K, Teraoka K, Hirotsune N, Nishino S: [Arterial stenosis after coil migration in embolization of an aneurysm]. *No Shinkei Geka* 38: 41-45, 2010 (Japanese)
- 7) Morizane A, Nakahara I, Sakai N, Yanamoto H, Akiyama Y, Sakai H, Higashi T, Namura S, Takahashi J, Nishizaki J, Kokuzawa J, Manaka H, Hayashi N, Nagata I, Kikuchi H: [Endovascular surgery for untreated ruptured aneurysm with symptomatic vasospasm]. *No Shinkei Geka* 27: 941-946, 1999 (Japanese)
- 8) Motegi H, Isobe M, Isu T, Kamiyama H: A surgical case of delayed coil migration after balloon-assisted embolization of an intracranial broad-neck aneurysm: Case report. *Neurosurgery* 67(2 Suppl Operative): 516-521, 2010
- 9) Phatouros CC, McConachie Ns, Jaspán T: Post-procedure migration of Guglielmi detachable coils and mechanical detachable spirals. *Neuroradiology* 41: 324-327, 1999
- 10) Thornton J, Dovey Z, Alazzaz A, Misra M, Aletich VA, Debrun GM, Ausman JI, Charbel FT: Surgery following endovascular coiling of intracranial aneurysms. *Surg Neurol* 54: 352-360, 2000

Address reprint requests to: Hajime Wada, MD, Department of Neurosurgery, Asahikawa Medical University, 2-1, 1-1, Midorigaoka-Higashi, Asahikawa, Hokkaido 078-8510, Japan.
e-mail: hjwada@asahikawa-med.ac.jp