

## Reminder of important clinical lesson

## Bilateral common carotid artery dissection

Ryota Inokuchi,<sup>1</sup> Hajime Sato,<sup>2</sup> Yuta Aoki,<sup>1</sup> Naoki Yahagi<sup>1</sup><sup>1</sup>Department of Emergency and Critical Care Medicine, The University of Tokyo Hospital, Bunkyo-ku, Tokyo, Japan<sup>2</sup>Department of Health Policy and Technology Assessment, National Institute of Public Health, Wako, Saitama, Japan

Correspondence to Dr Ryota Inokuchi, inokuchir-icu@h.u-tokyo.ac.jp

## Summary

A 63-year-old Japanese man with no significant medical or family history was admitted for sudden consciousness disturbance, left hemiparesis and shock. Physical examination showed internal carotid artery asymmetry on palpation and significant differential blood pressure in both upper arms. A thoracic CT scan showed classic aortic dissection from the ascending aorta through the common iliac artery, classic dissection of the left common carotid artery and an intramural haematoma in the right common carotid artery. The patient's consciousness level gradually improved, and he underwent emergency surgery involving aortic rebuilding with a synthetic graft. Subsequently, he had a good clinical course.

## BACKGROUND

Dissection of the common carotid artery is frequently associated with aortic dissection. Bilateral carotid artery dissections are rare and have unknown prevalence; in addition, they may cause hemiplegia and altered mental status, thereby hindering their early diagnosis.

## CASE PRESENTATION

A 63-year-old man with no significant medical and family history was admitted to the emergency room for sudden consciousness disturbance and left hemiparesis. On admission to the emergency department, his body temperature was 36.4°C; pulse rate, 82 beats/min; blood pressure, 110/60 and 65/31 mm Hg for the right and left arms, respectively; and the Glasgow Coma Scale score was 4/15 (eyes, 1; verbal, 1; and motor, 2). On examination, internal carotid artery asymmetry was evident on palpation. Further clinical examination showed isolated twitching of the right arm and incontinence. Heart murmur, chest rales and tongue biting were absent.

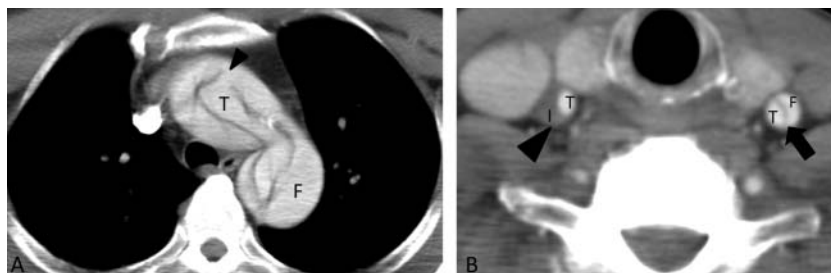
## INVESTIGATIONS

Thoracoabdominal contrast CT showed classic aortic dissection from the ascending aorta through the common

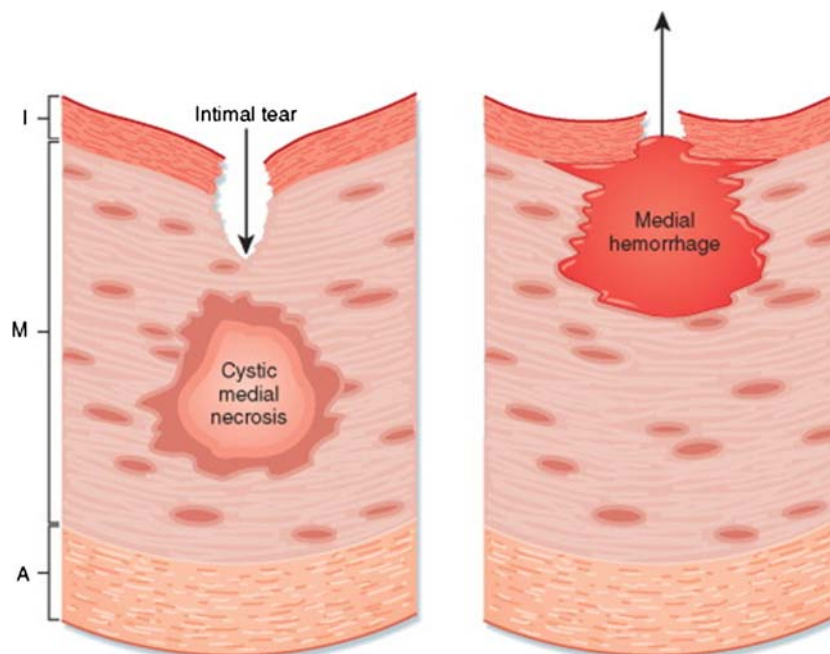
iliac artery (figure 1A), classic dissection of the left common carotid artery (figure 1B). The patient's consciousness level gradually improved over 30 min; he experienced anterior chest and back pain but not paralysis. He underwent emergency surgery involving aortic rebuilding with a synthetic graft and had a good clinical course. On day 21, the patient was discharged without complications.

## DISCUSSION

Aortic dissection can occur by two possible mechanisms<sup>1</sup> (figure 2). The classic mechanism is an intimal tear, which is usually transverse and extends through the very thin tunica intima into the tunica media. Blood enters a layer of the media under pulsatile pressure, resulting in longitudinal dissection, usually in a distal direction. The other major mechanism is rupture of the vasa vasorum, usually of a penetrating branch within the tunica media, with consequent bleeding into the media. Progression then occurs in the same fashion, either with or without secondary tearing through the intima into the aortic lumen. The aorta usually tears near tethering points, where the vessel undergoes the greatest flexion stress



**Figure 1** (A) Axial image through the thorax shows the initial dissection flap in the aortic arch (arrowhead). (B) Classic dissection of the left common carotid artery (arrow) was seen together with an intramural haematoma in the right common carotid artery (arrowhead). T, true lumen; F, false lumen; I, intramural haematoma.



**Figure 2** Two mechanisms for aortic dissection. A, adventitia; I, intima; M, media.

during cardiac contractions. Thus, the most common location of dissection initiation is the first few centimetres of the ascending aorta, with the next most common being the origin of the descending aorta, just distal to the left subclavian artery.<sup>2</sup>

Dissection of the common carotid artery is frequently associated with aortic dissection,<sup>3</sup> but bilateral carotid artery dissections are rare and have unknown prevalence.<sup>4</sup> Syncope occurs early in aortic dissection in approximately 9% of cases and may be the sole presentation in some patients.<sup>5–6</sup> It most often heralds dissection into the pericardium, causing pericardial tamponade, but may occur because of transient interruption of blood flow to the cerebral vasculature, as in our case. Neurological symptoms such as focal weakness or mental status changes occur in up to 17% of cases.<sup>5–7</sup> Overlooking aortic dissection during thrombolytic therapy for patients with acute stroke leads to poor outcomes.

Routine laboratory tests are of little value in diagnosing aortic dissection; recently, however, there has been increasing interest in the biochemical diagnosis of acute aortic dissection.<sup>8</sup> Myosin heavy-chain concentrations, D-dimer levels<sup>9</sup> and soluble elastin fragment concentrations are some of the newer tools that may help diagnose aortic dissection. Prospective clinical trials to evaluate their usefulness are pending. A recent meta-analysis found that D-dimer level assessment exhibited 97% sensitivity for aortic dissection.<sup>10</sup> However, that assessment requires careful attention, because D-dimer levels also increase in cases of disseminated intravascular coagulation, deep vein thrombosis, pulmonary emboli, cancer, myocardial infarction, pregnancy and sepsis.<sup>11–12</sup>

In conclusion, early identification and management of dissection as a cause of ischaemic stroke is important while treating patients in shock.

### Learning points

- ▶ The aggressiveness of screening for aortic dissection in patients who are in shock and exhibit neurological abnormalities should be further evaluated.
- ▶ D-dimer-level assessment has 97% sensitivity for aortic dissection.
- ▶ Dissection of the common carotid artery is frequently associated with aortic dissection, but bilateral carotid artery dissections are rare.

**Competing interests** None.

**Patient consent** Obtained.

### REFERENCES

1. Zipes DP, Libby P, Bonow RO, et al. eds. *Braunwald's heart disease: a textbook of cardiovascular medicine*. 7th edn. Philadelphia: Elsevier, 2005.
2. McMahon MA, Squirrell CA. Multidetector CT of aortic dissection: a pictorial review. *Radiographics* 2010;**30**:445–60.
3. Hirst AE Jr, Johns VJ Jr, Kime SW Jr. Dissecting aneurysm of the aorta: a review of 505 cases. *Medicine (Baltimore)* 1958;**37**:217–79.
4. Noordally SO, Nazeri A, Sohawon S, et al. Bilateral common carotid artery dissection following aortic dissection type A repair. *ANZ J Surg* 2011; **81**:487.
5. Hagan PG, Nienaber CA, Isselbacher EM, et al. The International Registry of Acute Aortic Dissection (IRAD): new insights into an old disease. *JAMA* 2000;**283**:897–903.
6. Klompas M. Does this patient have an acute thoracic aortic dissection? *JAMA* 2002;**287**:2262–72.
7. Spittell PC, Spittell JA, Joyce JW, et al. Clinical features and differential diagnosis of aortic dissection: experience with 236 cases (1980 through 1990). *Mayo Clin Proc* 1993;**68**:642–51.
8. Apostolakis E, Akinosoglou K. What's new in the biochemical diagnosis of acute aortic dissection: problems and perspectives. *Med Sci Monit* 2007;**13**: RA154–8.

9. **Eggebrecht H**, Naber CK, Bruch C, *et al*. Value of plasma fibrin D-dimers for detection of acute aortic dissection. *J Am Coll Cardiol* 2004;**44**:804–9.
10. **Shimony A**, Filion KB, Mottillo S, *et al*. Meta-analysis of usefulness of d-dimer to diagnose acute aortic dissection. *Am J Cardiol* 2011;**107**:1227–34.
11. **Adam SS**, Key NS, Greenberg CS. D-dimer antigen: current concepts and future prospects. *Blood* 2009;**113**:2878–7.
12. **Koracevic GP**. Pragmatic classification of the causes of high D-dimer. *Am J Emerg Med* 2009;**27**:1016.e5–7.

This pdf has been created automatically from the final edited text and images.

Copyright 2012 BMJ Publishing Group. All rights reserved. For permission to reuse any of this content visit <http://group.bmj.com/group/rights-licensing/permissions>.

BMJ Case Report Fellows may re-use this article for personal use and teaching without any further permission.

Please cite this article as follows (you will need to access the article online to obtain the date of publication).

Inokuchi R, Sato H, Aoki Y, Yahagi N. Bilateral common carotid artery dissection. *BMJ Case Reports* 2012;10.1136/bcr-2012-006207, Published XXX

Become a Fellow of BMJ Case Reports today and you can:

- Submit as many cases as you like
- Enjoy fast sympathetic peer review and rapid publication of accepted articles
- Access all the published articles
- Re-use any of the published material for personal use and teaching without further permission

For information on Institutional Fellowships contact [consortiasales@bmjgroup.com](mailto:consortiasales@bmjgroup.com)

Visit [casereports.bmj.com](http://casereports.bmj.com) for more articles like this and to become a Fellow