

Delayed traumatic intracerebral hematomas: "Spät-Apoplexie"

Report of two cases

HENRY ELSNER, M.D., DANIELE RIGAMONTI, M.D., GREGORY CORRADINO, M.D.,
ROBERT SCHLEGEL, JR., M.D., AND JOHN JOSLYN, M.D.

*Divisions of Neurological Surgery and Neuroradiology, University of Maryland Medical System,
Baltimore, Maryland*

✓ Two patients who suffered a head trauma experienced sudden clinical deterioration more than 1 week after their injury. The initial computerized tomography (CT) scan demonstrated a small hematoma underlying a depressed skull fracture in one patient and a small interhemispheric subdural hematoma in the other. Both patients had made a complete recovery and follow-up CT scans were normal when clinical deterioration suddenly occurred. Both patients developed a large intracerebral hematoma and underwent emergency evacuation of the mass. The first patient recovered with the exception of a moderate hemiparesis and dysphasia, but the second patient died.

Delayed traumatic intracerebral hematomas have been described in the literature. Since the advent of CT scanning, the incidence of this phenomenon has been estimated as between 1.7% and 7.4% of closed head injuries. In 1891, Otto Bollinger described four patients who suffered head injury, followed days to weeks later by death from an apoplectic event. His criteria for diagnosis of "traumatische Spät-Apoplexie" included the absence of preexisting vascular disease, a definite history of trauma, an asymptomatic interval of at least several days, and an apoplectic episode. These two cases reemphasize the existence of Spät-Apoplexie as a rare clinical condition. In the presence of CT findings of even small traumatic intracerebral or extracerebral hematomas, the possibility of this late complication should be kept in mind.

KEY WORDS • Spät-Apoplexie • delayed traumatic hematoma • hematoma

SINCE the development of computerized tomography (CT), the occurrence of delayed traumatic intracerebral hematoma has been well documented. Many of these hematomas occur in a subacute fashion 24 to 48 hours after the initial trauma. "Spät-Apoplexie" was described in 1891 by Otto Bollinger.² He reported four cases of delayed traumatic intracerebral and intraventricular hematomas which occurred 2 to 4 weeks after mild head injury and resulted in death. In each case, the patients were recovering well and experienced a sudden apoplectic episode followed by death, hence the term "spät" (or late) apoplexy.

At the University of Maryland Hospital and the Maryland Institute for Emergency Medical Services System (MIEMSS) approximately 800 patients are evaluated by the Neurosurgery Service for closed head injury each year. Approximately 150 of these patients have a CT finding of intracranial pathology. In the past

year, two patients experienced apoplectic events while recovering from head injury, a phenomenon consistent with Bollinger's initial description of "Spät-Apoplexie."² A review of the clinical course of these two patients as well as an appraisal of the pertinent literature on this entity form the subject of this report.

Case Reports

Case 1

This 29-year-old man suffered a left frontal depressed skull fracture with underlying cerebral contusion after being struck in the head with a blunt object. On admission he was awake and alert but aphasic. He had no motor deficit. He underwent operative elevation of the fracture and closure of the dural laceration. Follow-up CT scans confirmed the presence of the small contusion underlying the craniectomy area. Ten days after the

event he was found in his room unresponsive. An emergency CT scan demonstrated a large intracerebral hematoma in the area of the previously noted contusion. Preoperative studies ruled out the presence of coagulopathy and he underwent emergency evacuation of the hematoma via a left frontotemporal craniotomy. At discharge, a fair recovery characterized by the return of some motor power had already begun. The aphasia remained dense.

Case 2

This 15-year-old girl had been involved in a motor-vehicle accident. At the time of admission, she was combative but did not show any evidence of focal deficit; CT scanning (Fig. 1 *left*) demonstrated an interhemispheric subdural hematoma. Angiography several days later demonstrated no vascular lesion. She was treated conservatively and made a complete recovery. On the 14th day after injury, the day of her planned discharge from the hospital, she experienced a seizure and rapidly lapsed into a coma with extensor posturing and a unilateral fixed and dilated pupil; CT scanning (Fig. 1 *right*) demonstrated the presence of bilateral intracerebral and intraventricular hemorrhage. Coagulation studies were within normal limits. The patient underwent craniotomy and evacuation of the hematoma but developed severe diffuse brain edema. She never regained neurological function and died 2 days later.

Discussion

The four cases of death after a delayed apoplectiform episode following head trauma described by Bollinger² met the following criteria: 1) a definite history of trauma; 2) an asymptomatic interval; 3) an apoplectic event; and 4) absence of vascular disease. Based on experimental data previously gathered by Duret,⁶ Bollinger suggested that cranial trauma caused softening of the brain involving the wall of an artery with eventual rupture of the vessel, necrosis, and hemorrhage.

Scheinker¹⁵ suggested the role of posttraumatic vasoparalysis as an alternative initial factor in the genesis of the hematoma.⁸ Vasoparalysis accompanied by dilatation of the capillaries with accumulation of toxic metabolites would precipitate an increase in capillary permeability, perivascular edema, and hemorrhage. Coalescence of multiple areas of diapedetic hemorrhage would create large traumatic intracerebral hematomas.¹⁰ After the original description, many authors reported several cases meeting Bollinger's criteria.^{4,5,11,12}

This subject was reviewed in 1970 by Morin and Pitts.¹¹ They included a review of patients with an apoplectic episode occurring after an asymptomatic period of less than 120 days. In total, they collected 24 cases from the literature and added three of their own. This review pointed out the following facts: 1) severity of the injury was in most cases minor, usually without fracture and with only a brief period of unconsciousness; 2) the asymptomatic interval was usually less than 30 days; 3) "Spät-Apoplexie" seemed to affect predominantly younger people in whom arteriosclerotic disease did not appear to be a factor, although a few cases occurred after the fourth decade; 4) sudden hemiplegia (an uncommon presentation in the young age group) appeared to be the prominent presentation in these patients; and 5) pathologically, the posttraumatic intracerebral hematoma most commonly affected structures other than the basal ganglia, as was demonstrated by Courville and Blomquist.³ Morin and Pitts also stressed the need to differentiate delayed posttraumatic hematomas from those due to the unrecognized presence of a vascular malformation or tumor.

Challenging the previous authors, Baratham and Dennyson¹ maintained that Bollinger's original description² was unsatisfactory because apoplexy is a term of dubious validity, not denoting a specific pathological entity. They questioned the relevance of trauma when the lucid interval is prolonged, inferring that it may have been purely fortuitous. They also explained the relatively high incidence of "Spät-Apoplexie" in the young by

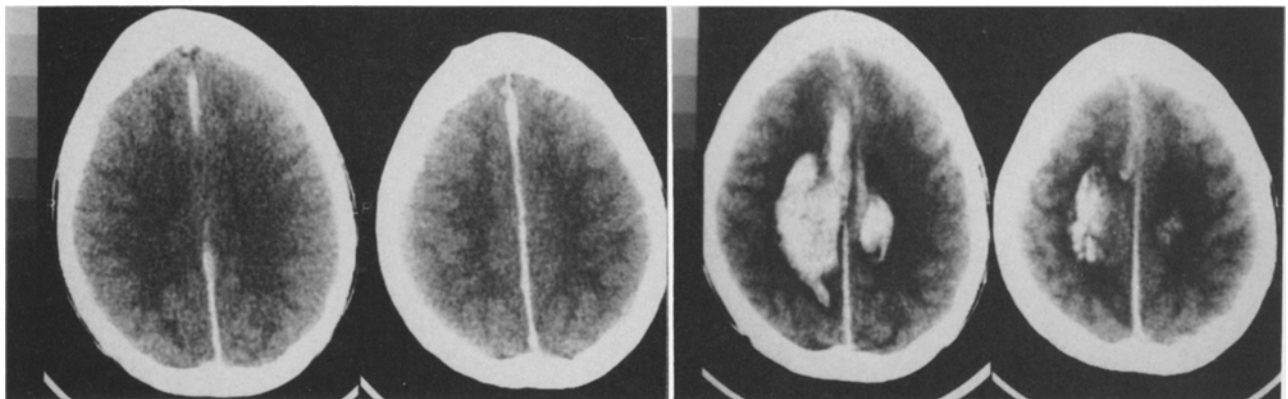


FIG. 1. Case 2. *Left Pair:* Nonenhanced computerized tomography (CT) scans obtained on admission showing an interhemispheric subdural hematoma. *Right Pair:* Nonenhanced CT scans obtained on the 14th day after injury showing bilateral intracerebral hemorrhage.

Delayed traumatic intracerebral hematomas: "Spät-Apoplexie"

stating that this group is more prone to injury than elderly patients. However, 14 of their 21 patients in fact had an asymptomatic interval of less than 48 hours and the majority of patients were in the seventh decade, a group quite different from Bollinger's cases.

Since CT has been available, the management of head trauma patients and the understanding of the pathology of head injuries have been greatly improved by the recognition of different types of posttraumatic hematomas. From among 656 cases, Diaz, *et al.*,⁴ presented nine patients with delayed hematomas in whom the interval from cranial injury to the development of the hematoma varied from 8 hours to 13 days. However, all of their cases differed from Bollinger's classic description² in that the patients who had initial negative CT scans did not have an asymptomatic interval. The 25 cases described in 1984 by Ninchoji, *et al.*,¹³ differed from the classic traumatic "Spät-Apoplexie" syndrome because they lacked a symptom-free interval and an apoplectic episode. The patients who "talk and deteriorate" after severe closed head injury usually do so within the first 48 hours¹⁴ and should not be included in the category discussed here. Fukamachi, *et al.*,⁷ reviewed 84 cases and described four subtypes of post-traumatic intracerebral hematomas, none of which matched the entity originally described by Bollinger.

We report two cases that seem to fall into the group of true "Spät-Apoplexie" cases. Both patients were young and had a definite asymptomatic interval. The onset of their symptoms was precipitous, in fact apoplectic, and no coagulation abnormality was detected (as has been noted in some delayed hematomas reported in the literature⁹) or preexisting vascular abnormality found. Their clinical course was characterized by complete neurological recovery and by resolution of the initial lesion seen on CT prior to the development of the apoplectic event, which occurred in both cases more than a week after the original trauma.

Many years after its original description, we are still at odds in trying to explain the pathogenesis of this entity, but we believe that traumatic "Spät-Apoplexie" should remain a clinical entity. Although we cannot provide any clues to help neurosurgeons in detecting these patients in advance, we recommend that the existence of this condition be kept in mind, especially in view of its potential medicolegal implications.

References

1. Baratham G, Dennyson WG: Delayed traumatic intracerebral haemorrhage. *J Neurol Neurosurg Psychiatry* 35: 698-706, 1972
2. Bollinger O: Über traumatische Spät-Apoplexie; ein Beitrag zur lehre von der Hirnerschütterung, in: *Internationale Beiträge Zur Wissenschaftlichen Medizin. Festschrift, Rudolf Virchow*. Berlin: A Hirschwald, 1891, pp 457-470
3. Courville CB, Blomquist OA: Traumatic intracerebral hemorrhage with particular reference to its pathogenesis and its relation to "delayed traumatic apoplexy." *Arch Surg* 41:1-28, 1940
4. Diaz FG, Yock DH Jr, Larson D, et al: Early diagnosis of delayed posttraumatic intracerebral hematomas. *J Neurosurg* 50:217-223, 1979
5. Dohrman PJ, Siu KH, Pike J: Delayed traumatic intracerebral haematoma: case report. *Aust NZ J Surg* 53: 169-171, 1983
6. Duret H: Cited in Reference 2
7. Fukamachi A, Nagaseki Y, Kohno K, et al: The incidence and developmental process of delayed traumatic intracerebral haematomas. *Acta Neurochir* 74:35-39, 1985
8. Gudeman SK, Kishore PRS, Miller JD, et al: The genesis and significance of delayed traumatic intracerebral hematoma. *Neurosurgery* 5:309-313, 1979
9. Kaufman HH, Moake JL, Olson JD, et al: Delayed and recurrent intracranial hematomas related to disseminated intravascular clotting and fibrinolysis in head injury. *Neurosurgery* 7:445-449, 1980
10. Lofgren J: Traumatic intracranial hematomas: pathophysiological aspects of their course and treatment. *Acta Neurochir (Suppl 36)*:151-154, 1986
11. Morin MA, Pitts FW: Delayed apoplexy following head injury ("traumatische Spät-Apoplexie"). *J Neurosurg* 33: 542-547, 1970
12. Naffziger HC, Jones OW: Late traumatic apoplexy: report of three cases with operative recovery. *Calif West Med* 29:361-364, 1928
13. Ninchoji T, Uemura K, Shimoyama I, et al: Traumatic intracerebral haematomas of delayed onset. *Acta Neurochir* 7:69-90, 1984
14. Rockswold GL, Leonard PR, Nagib MG: Analysis of management in thirty-three closed head injury patients who "talked and deteriorated." *Neurosurgery* 21:51-55, 1987
15. Scheinker M: Cited in Reference 7

Manuscript received August 9, 1989.

Address reprint requests to: Daniele Rigamonti, M.D., Division of Neurosurgery, University of Maryland Hospital, 22 South Greene Street, Baltimore, Maryland 21201.