

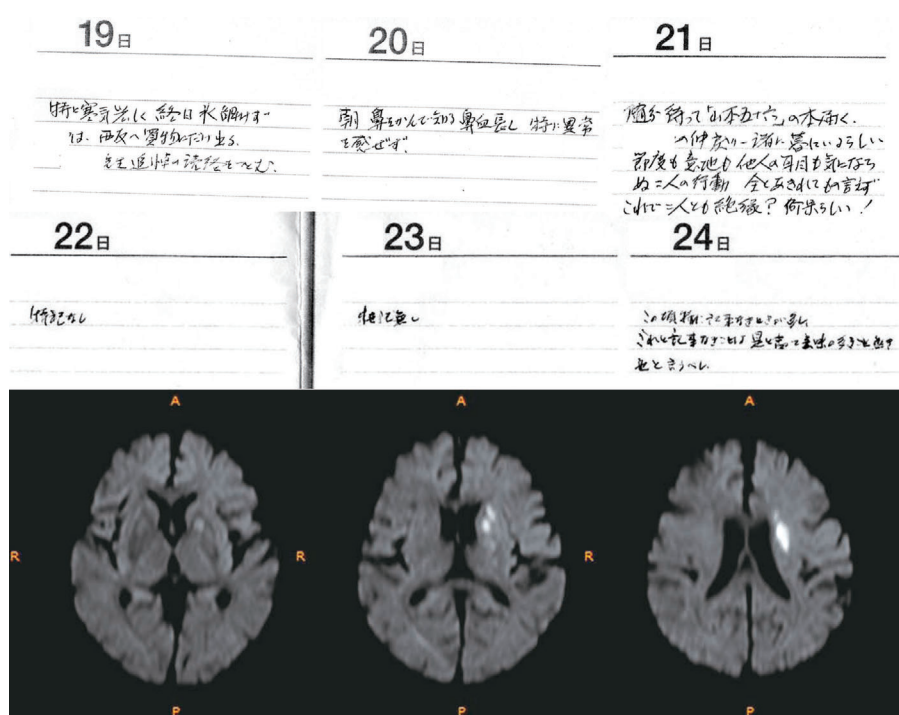
Micrographia and Abulia due to Frontal Subcortical Infarction

Kengo Maeda, Ryo Idehara and Tomoyuki Shiraishi

Key words: micrographia, abulia, infarction, frontal lobe function

(Intern Med 51: 1953-1954, 2012)

(DOI: 10.2169/internalmedicine.51.7721)



Picture

A right-handed 85-year-old man with diabetes and hypertension presented with abrupt onset micrographia and loss of interest in reading books. He was alert and there was no hemiparesis, extrapyramidal sign, sensory disturbance of fingers, or ataxia. There was no alexia or agraphia. His diary clearly showed micrographia after the onset day (Picture). Diffusion-weighted magnetic resonance imaging revealed a fresh infarction at the left frontal subcortex extending to the anterior limb of the internal capsule and the head of the caudate (Picture). His symptom was considered to be micrographia and abulia. Lesions affecting the frontal subcortex are known to cause micrographia (1). The frontal lobe

function could play a role in the pathogenesis of micrographia (1, 2). The fact that the presented case showed not only micrographia but also abulia might support the possible link of frontal lobe function and micrographia.

The authors state that they have no Conflict of Interest (COI).

References

1. Nakamura M, Hamamoto M, Uchida S, et al. A case of micrographia after subcortical infarction: possible involvement of frontal lobe function. *Eur J Neurol* 10: 593-596, 2003.

2. Troyer AK, Black SE, Armilio ML, Moscovitch M. Cognitive and motor functioning in a patient with selective infarction of the left basal ganglia: evidence for decreased non-routine response selection and performance. *Neuropsychologia* **42**: 902-911, 2004.

© 2012 The Japanese Society of Internal Medicine
<http://www.naika.or.jp/imindex.html>