

A successful treatment of arterial ischemic stroke with stent insertion in a child with congenital heart disease

Hee Joon Yu · I-Seok Kang · Munhyang Lee ·
Keon-Ha Kim · Jeehun Lee

Received: 17 June 2012 / Accepted: 17 July 2012
© Springer-Verlag 2012

Abstract

Introduction Diagnosis of arterial ischemic stroke in pediatric patients is often delayed due to the uncertainty and variability of clinical symptoms. Early diagnosis of arterial ischemic stroke can bring a favorable prognosis with prompt thrombolytic therapy or stent insertion, via transfemoral cerebral arteriogram. Acute thrombolytic therapy is rarely attempted in children because of the delayed diagnosis.

Patient and method We report a case of a 4-year-old girl with complex heart disease who was presented with arterial ischemic stroke at the right distal internal carotid artery and successfully treated by stent insertion in which repeated thrombolysis or ballooning had failed.

Result Left hemiparesis was nearly recovered 6 days after the stent insertion. The mean flow velocity of the right middle cerebral artery has slightly improved compared to that of the initial study. She has been followed-up for 6 months in the outpatient clinic without neurologic sequelae.

Conclusion This case suggests that intracranial stent insertion may be a safe and an effective modality in young children, when the thrombolytic therapy or ballooning is inapplicable. Additionally, transcranial Doppler ultrasonography is useful

to monitor the cerebral blood flow after stent insertion in children.

Keywords Arterial ischemic stroke · Transfemoral cerebral arteriogram · Stent insertion · Complex heart disease · Children

Introduction

An arterial ischemic stroke (AIS) occurs when arterial blood flow to the brain is blocked by the narrowing of the artery or when a blood clot in the artery blocks the supply of blood to a part of the brain. The incidence of AIS in pediatric patients is 2.6 in every 100,000 per year [1]. The common conditions prone to pediatric AIS are cerebral arteriopathies, congenital or acquired heart diseases, and sickle cell diseases [8]. Patients with AIS are usually accompanied with focal weakness, seizure, headache, hemiparesis, localized numbness or tingling, alerted mental status, vision change, and ataxia [8].

In adults, the recombinant tissue plasminogen activator has been proven to be a safe and an effective treatment for AIS when administered 4.5 hours from the onset of the symptoms [4]. Additionally, mechanical devices, such as arterial stent, have evolved to improve the recanalization rate. However, pediatric stroke is often under-recognized and delayed in the diagnosis because of nonspecific presenting symptoms, which imposes many differential diagnoses [5]. For those reasons, it is hard to use recombinant tissue plasminogen activator or to apply stent-assisted mechanical recanalization in pediatric AIS patients. Although excellent results on the use of mechanical devices have been reported in adult AIS, only one pediatric case with intracranial carotid artery dissection treated by stent insertion has been reported in 2010 [7]. We describe a case of AIS, associated with congenital heart disease, in a 4-year-old girl that was successfully treated with arterial stent insertion.

H. J. Yu · I.-S. Kang · M. Lee · J. Lee (✉)
Department of Pediatrics,
Samsung Medical Center,
Sungkyunkwan University School of Medicine,
81, Irwon-Ro, Gangnam-Gu,
Seoul 135-710, Korea
e-mail: jhlee0101@skku.edu

K.-H. Kim
Department of Radiology,
Samsung Medical Center,
Sungkyunkwan University School of Medicine,
81, Irwon-Ro, Gangnam-Gu,
Seoul 135-710, Korea
e-mail: somatom@skku.edu

Case report

A 4-year-old girl was admitted with complaint of worsening fatigue and dyspnea on exertion, which began 2 months ago. She was diagnosed with complete atrioventricular septal defect and coarctation of aorta. She had undergone four operations; coarctoplasty, pulmonary artery banding, total correction of complete atrioventricular septal defect, aortopexy, and mitral valve and tricuspid valve repair.

On admission, the echocardiography revealed aggravation of mitral valve regurgitation, along with hypoplasia and stenosis of the left pulmonary artery. For that reason, she underwent mitral valve replacement and left pulmonary artery angioplasty. On the 13th day after the operation, she had cardiectomy for constrictive pericarditis, which was diagnosed by the presence of echogenic materials in the pericardial space on a follow-up echocardiography.

Five days after the cardiectomy, persistent presence of echogenic materials in the pericardium was noted on echocardiography. On the evening of the same day, she was abruptly presented with left hemiparesis and left facial palsy.

She was alert, and the neurologic examination revealed central-type left facial palsy, left hemiparesis (motor grade 2), positive Babinski sign, and positive ankle clonus on the left side. The National Institutes of Health Stroke Scale was ten. Computed tomography (CT) showed a highly attenuated focal lesion at the bifurcated portion of the right internal carotid artery (ICA) on the precontrast image and discontinuity of the right ICA on the postcontrast image (Fig. 1). With that result, focal embolus in the right distal ICA was suspected. Emergency transfemoral cerebral angiography was tried in 90 min after the onset of the symptoms. A T-shaped total occlusion, at the right distal ICA, was observed on transfemoral cerebral angiography (Fig. 1). It was difficult to use a fibrinolytic agent, such as urokinase, because she has had a mitral valve replacement 18 days ago. We tried mechanical thrombolysis with ballooning. Despite repetitive trials, the occlusion persisted when the balloon deflated (Fig. 2). Thereafter, the stent (Enterprise 4.5 × 28 mm, Cordis Neurovascular, Inc., Miami, FL, USA) was inserted, and recanalization of the middle cerebral artery (MCA) was observed 4 hours after the onset of the symptoms (Fig. 3).

Fig. 1 Brain computed tomography shows a high attenuated focal lesion at the proximal portion of the right middle cerebral artery on pre-contrast image (a). Transfemoral cerebroarteriography reveals narrowing and total occlusion at the right internal carotid artery angiography (anterior-posterior view (b), lateral view (c)). Left internal carotid artery angiography shows normal lumen (d)

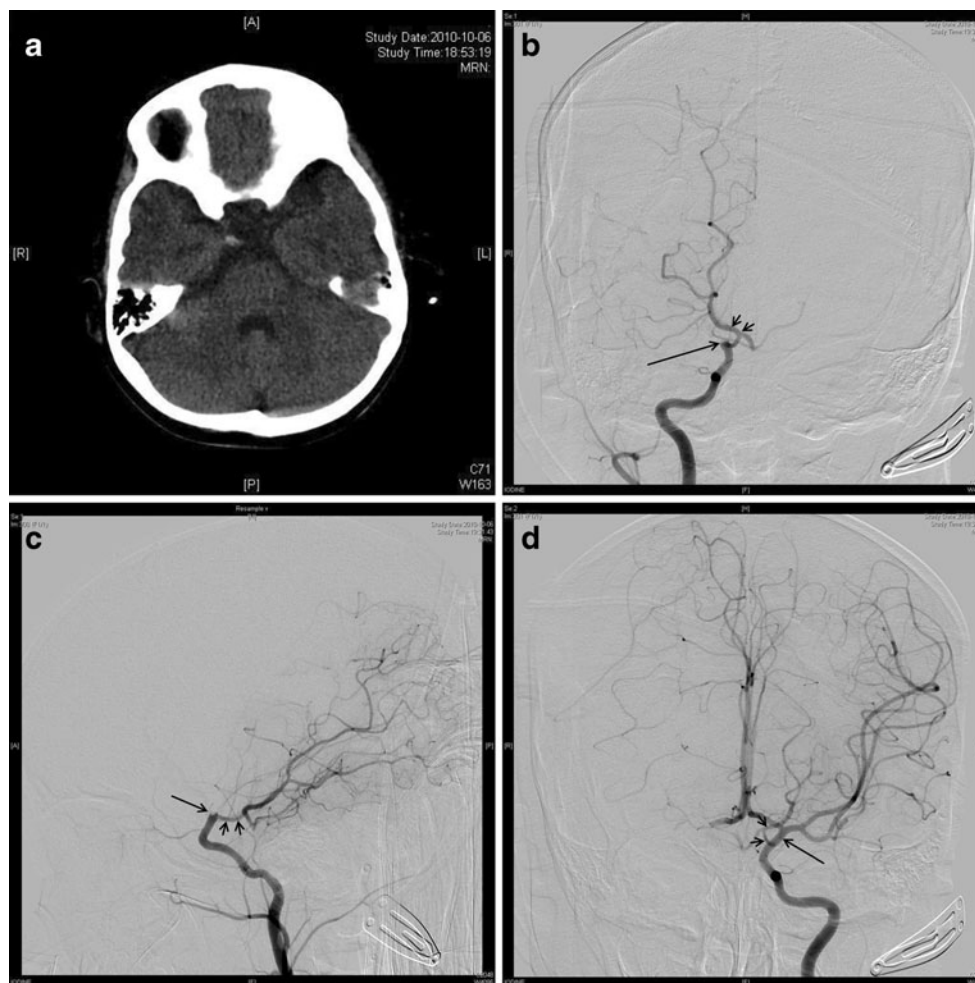
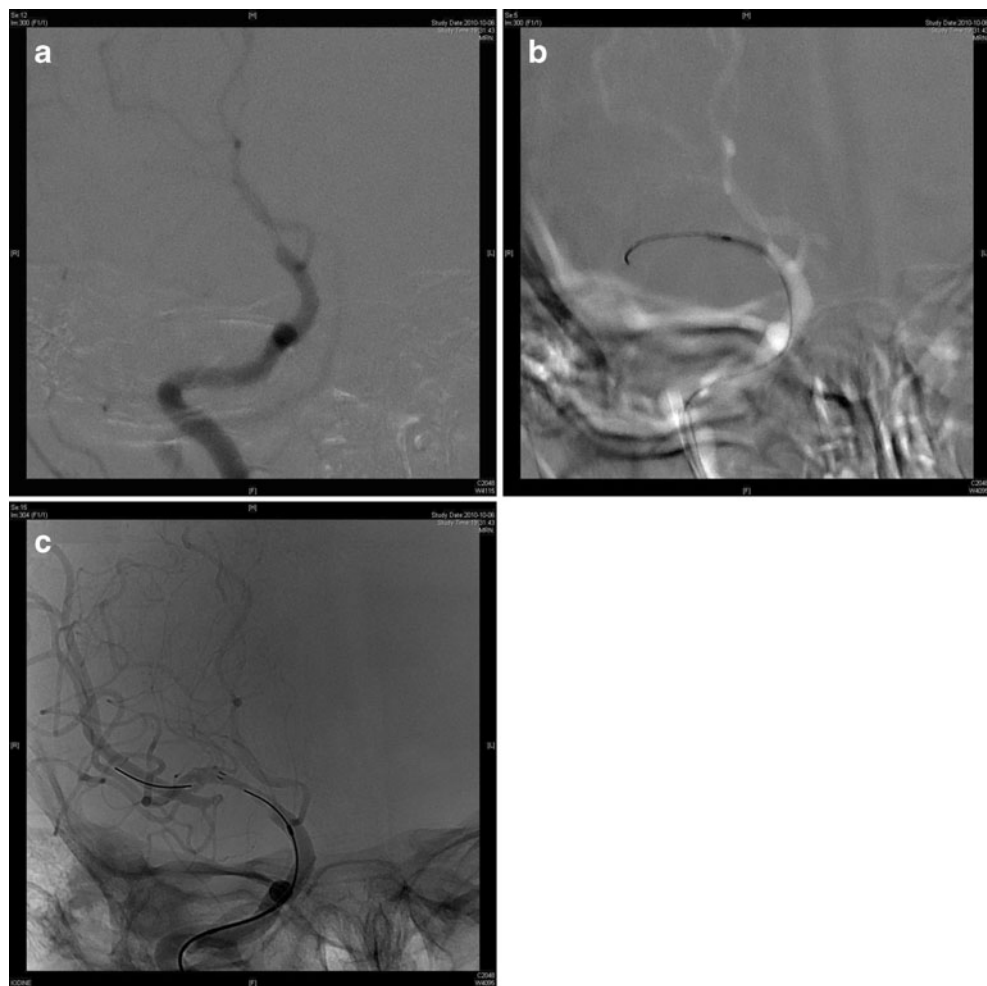


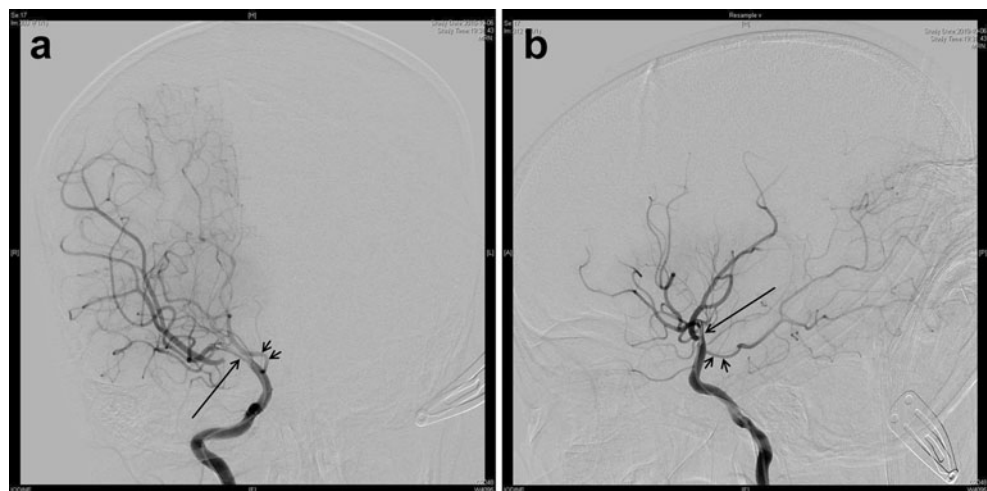
Fig. 2 Mechanical thrombolysis with ballooning is tried. Despite repetitive trials, the occlusion persisted (a and b). The inserted stent is delineated (c)



After the stent insertion, we administered heparin, aspirin, and clopidogrel to prevent thrombosis. The flow of MCA was monitored via transcranial Doppler ultrasonography. During the first monitoring after the stent insertion, the flow rate of the right MCA was faster than the left, reflecting relative narrowing. For 14 days of monitoring, the flow rate

was well maintained without abrupt change (Fig. 4). Left hemiparesis was nearly recovered 6 days after the stent insertion. Movement of the left arm was somewhat slower, but the motor power was normal, and the range of motion was not limited. On the eighth day after stent insertion, transient paresthesia and motor weakness in the left leg

Fig. 3 Recanalization of the middle cerebral artery is seen after stent insertion



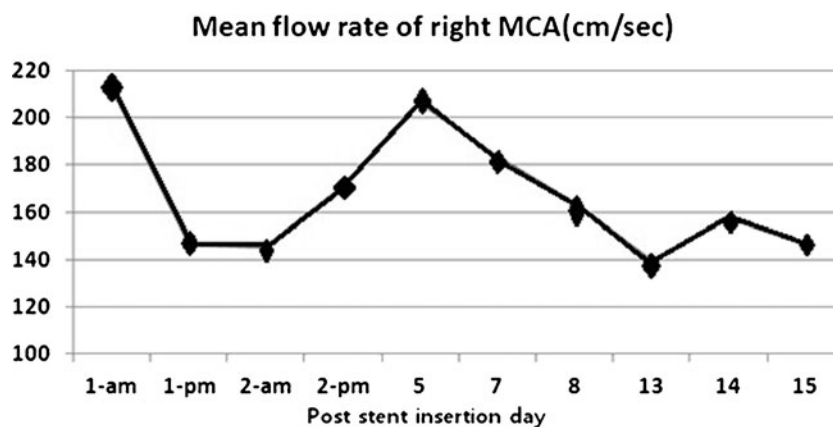


Fig. 4 This graph shows mean flow velocities of the right middle cerebral artery (MCA), as measured by transcranial Doppler study after stent insertion. Immediately after the stent insertion, highly increased flow velocities were recorded from the right middle cerebral artery, and mildly increased flow velocities were recorded from the left middle

cerebral artery, with the mean velocity at 112 cm/sec. The mean flow velocity of the right middle cerebral artery decreased and stabilized, and that of the left middle cerebral artery returned to normal (normal mean flow velocity of middle cerebral artery, 94 ± 10 cm/sec)

occurred and spontaneously recovered within 24 hours. The mean flow velocity of the right MCA has slightly improved compared to that of the previous day. The blood flow at the proximal and distal MCA was well maintained on the brain CT, examined at day 8, the evening after stent insertion. She was taking aspirin and warfarin at discharge. She has been followed-up for 6 months in the outpatient clinic without neurologic sequelae.

Discussion

This is a case of AIS associated with congenital heart disease, which was detected immediately, and had been successfully treated with arterial stent insertion after an unsuccessful mechanical thrombolysis.

The primary management of AIS in adults is the treatment with antithrombotic agents, such as aspirin or heparin. If the AIS is found in 4.5 hours, it is useful to use a thrombolytic agent or to adopt stent-associated revascularization [6]. The treatment of childhood AIS is different from that of adulthood. Many cases of childhood AIS are delayed in diagnosis and not eligible to treat with thrombolytic agents [4]. It was reported that in pediatric patients, the rate of episodes mimicking a stroke was slightly higher than in adults [13]. Conditions, which mimic a stroke includes migraine, epilepsy, postictal paralysis, tumor, acute disseminated encephalomyelitis, reversible posterior leukoencephalopathy syndrome, acute postinfectious cerebellitis, metabolic stroke, idiopathic intracranial hypertension, empyema, and intracranial abscess [13]. For that reason, diagnosis on children with AIS is delayed, and there is less opportunity to try thrombolysis. Additionally, there has been no report about stent insertion in childhood AIS.

This case was diagnosed immediately after the symptom onset, and the thrombolytic therapy could be applied. However, it had not been considered because, recently, she had undergone mitral valve replacement. Thus, we tried mechanical thrombolysis instead of applying a thrombolytic agent.

A thrombolytic agent, such as recombinant tissue plasminogen activator, has a narrow treatment time window of 4.5 hours from the onset of stroke. Delayed administration of recombinant tissue plasminogen activator, over the acceptable time window, can increase the risk of intracranial hemorrhage [4].

As an alternative treatment method, a mechanical device for revascularization was developed, and many clinical trials using a mechanical device in adult patients are in progress. The recanalization rate, using a mechanical device, is higher than the rate of using a thrombolytic agent alone [12]. The patient in this study was treated with the Enterprise stent, which is a self-expanding stent and is placed by a catheter-based delivery system. A stent can move emboli or thrombi toward the edges of the vessel lumen to rebuild luminal patency and restore the blood flow. The device has been shown to provide excellent navigability and ease of deployment [9]. Stent insertion requires anticoagulation, following the procedure, which may increase the possibility of intracranial hemorrhage [14]. It was reported that revascularization was achieved in 100 % of patients using the Enterprise stent, and symptomatic intracranial hemorrhage occurred in two patients (10 %) [9]. The rate of intracranial hemorrhage has been reported in 9–10 % of the patients who underwent intracranial stent insertion [9]. We also paid great attention to subsequent hemorrhage, monitoring the bleeding tendency and patient's neurologic status, and in our case, no clinically significant hemorrhagic complications occurred. In addition, the stent-associated thrombosis and restenosis may occur.

Fargen et al. reported long-term results of Enterprise stent, and angiographic in-stent stenosis was seen in 3.4 % and thromboembolic events occurred in 4.4 % [3]. In adult patients, stenting is a hopeful option that appears to yield higher recanalization rates and allows a broader treatment window [2]. According to the result of this study, stent implantation in children appears to be a safe and an optional treatment, which yields immediate recanalization, as in adults. If the thrombolysis could not be applied or balloon angioplasty failed, the intracranial stenting can be considered as a treatment option.

There are technical difficulties of using magnetic resonance imaging to evaluate postprocedural stent patency due to stent-induced artifacts [10]. Since stent artifacts, using sonography, are negligible, transcranial Doppler ultrasonography is useful to show stent patency after insertion. Transcranial Doppler ultrasonography has been in the limelight because it is a noninvasive technique and can allow continuous bedside monitoring with high accuracy [11]. A normal value of MCA velocity has not been established in children; therefore, we compared the right MCA velocity to the left MCA velocity. Additionally, it is safe in terms of radiation compared to that of the CT angiography.

We expect that the stent can be occluded in the future. Therefore, we will monitor the patency of the right MCA and the formation of collateral vessels with transcranial Doppler ultrasonography and angiography. In case the narrowing proceeds, we can consider encephaloduroarteriosynangiosis, which is frequently done in Moyamoya disease.

In conclusion, there is a relatively high possibility of AIS in children with congenital heart disease. We can consider thrombolysis if it is detected within 4.5 hours from onset. If the thrombolytic therapy is not possible for various reasons, mechanical thrombolysis can be considered to be an alternative method. This case suggests that intracranial stent insertion may be a safe and an effective modality in young children, when the thrombolytic therapy or ballooning is inapplicable. Additionally, transcranial Doppler ultrasonography is useful in monitoring the cerebral blood flow after stent insertion in children, as in adults.

Acknowledgments This study was supported by the Samsung Medical Center Clinical Research Development Program grant, CRS-108-06-1.

Conflict of interest The authors declared no potential conflicts of interest with respect to the research, authorship, and/or publication of this article.

Ethical approval Ethical approval for this retrospective study was provided by the institutional review board of Samsung Seoul Hospital in Seoul, Republic of Korea.

References

- Benedict SL, Ni OK, Schloesser P, White KS, Bale JF Jr (2007) Intra-arterial thrombolysis in a 2-year-old with cardioembolic stroke. *J Child Neurol* 22:225–227
- Cohen JE, Gomori JM, Leker RR, Eichel R, Arkadir D, Itshayek E (2011) Preliminary experience with the use of self-expanding stent as a thrombectomy device in ischemic stroke. *Neurol Res* 33:214–219
- Fargen KM, Hoh BL, Welch B, Lee Pride G, Lanzino G, Boulos AS, Carpenter JS, Rai A, Veznedaroglu E, Ringer A, Rodriguez-Mercado R, Kan P, Siddiqui A, Levy EI, Mocco J (2012) Long-term results of enterprise stent-assisted coiling of cerebral aneurysms. *Neurosurgery* 71(2):239–244
- Grunwald IQ, Walter S, Fassbender K, Kuhn AL, Hartmann KM, Wilson N, Sievert H, Kamran M, Hopkins LN, Wakhloo AK (2011) Ischemic stroke in children: new aspects of treatment. *J Pediatr* 159:366–370
- Jordan LC, Hillis AE (2011) Challenges in the diagnosis and treatment of pediatric stroke. *Nat Rev Neurol* 7:199–208
- Khalessi AA, Natarajan SK, Orion D, Binning MJ, Siddiqui A, Levy EI, Hopkins LN (2011) Acute stroke intervention. *JACC Cardiovasc Interv* 4:261–269
- Lai YJ, Chang FC, Lin CJ, Hsieh TC, Wang KL (2010) Endovascular therapy in pediatric intracranial carotid artery dissection. *Pediatr Neurol* 42:291–294
- Mackay MT, Wiznitzer M, Benedict SL, Lee KJ, Devereber GA, Ganesan V (2011) Arterial ischemic stroke risk factors: the International Pediatric Stroke Study. *Ann Neurol* 69:130–140
- Mocco J, Hanel RA, Sharma J, Hauck EF, Snyder KV, Natarajan SK, Linfante I, Siddiqui AH, Hopkins LN, Boulos AS, Levy EI (2010) Use of a vascular reconstruction device to salvage acute ischemic occlusions refractory to traditional endovascular recanalization methods. *J Neurosurg* 112:557–562
- Oehm E, Els T, Spreer J, Kassubek J, Hetzel A (2002) Transcranial color-coded sonography in basilar artery stenting. *Ultrasound Med Biol* 28:383–387
- Panerai RB (2009) Transcranial Doppler for evaluation of cerebral autoregulation. *Clin Auton Res* 19:197–211
- Roth C, Papanagiotou P, Behnke S, Walter S, Haass A, Becker C, Fassbender K, Politi M, Korner H, Romann MS, Reith W (2010) Stent-assisted mechanical recanalization for treatment of acute intracerebral artery occlusions. *Stroke* 41:2559–2567
- Shellhaas RA, Smith SE, O'Tool E, Licht DJ, Ichord RN (2006) Mimics of childhood stroke: characteristics of a prospective cohort. *Pediatrics* 118:704–709
- Stampfl S, Hartmann M, Ringleb PA, Haehnel S, Bendszus M, Rohde S (2011) Stent placement for flow restoration in acute ischemic stroke: a single-center experience with the Solitaire stent system. *AJNR Am J Neuroradiol* 32:1245–1248