

Case report

Paradoxical cerebral embolism with patent foramen ovale and deep venous thrombosis caused by a massive myoma uteri

Shuta Toru^{a,*}, Toyonari Murata^b, Maya Ohara^a, Taro Ishiguro^a, Takayoshi Kobayashi^a^a Department of Neurology, Nakano General Hospital, 4-59-16 Chuo, Nakano-ku, Tokyo 164-8607, Japan^b Department of Gynecology, Nakano General Hospital, Japan

ARTICLE INFO

Article history:

Received 29 September 2011

Received in revised form 27 June 2012

Accepted 30 June 2012

Available online 14 August 2012

Keywords:

Paradoxical cerebral embolism

Patent foramen ovale

Deep venous thrombosis

Myoma uteri

1. Introduction

Patent foramen ovale (PFO) is now regarded an important risk factor for cerebral infarction in young adults [1]. We report a rare case of multiple cerebral embolisms associated with PFO and deep venous thrombosis (DVT) caused by a gigantic myoma uteri.

2. Case report

A 42-year-old dextral woman came to our hospital with right hemiparesis. A huge uteral myoma was found 10 years ago, and she regularly visited our gynecology department. She had had neither other past illnesses nor the habit of drinking or smoking. Drug history for oral contraceptives is negative. At age 41, she suddenly suffered left hemiparesis and was admitted to another hospital. Cerebral infarction was diagnosed in the right middle cerebral artery (MCA) area. Brain angiography showed stenosis of the M2 portion of the right MCA, but no atherosclerotic changes. She was discharged with no neurological symptoms, after which cilostazol had been prescribed.

On admission to our hospital, right hemiparesis and severe motor aphasia were present, and there was slight edema in her left leg. Neurological and general findings showed no other abnormalities. D-Dimer was elevated to 30.8 $\mu\text{g/ml}$ (normal range < 1 $\mu\text{g/ml}$), but other laboratory data on admission for cholesterol, HbA1c,

various autoantibodies, anti-phospholipid antibodies, protein C or S activity and total homocysteine were normal. Brain MRI showed fresh cerebral infarction in the left MCA area and left cerebellar hemisphere (Fig. 1A and B) and an old infarction in the right MCA area (Fig. 1C). Electrocardiography (ECG) showed normal sinus rhythm and no right ventricle strain. No atrial fibrillation could be detected in a 24-h Holter ECG. Transesophageal echocardiography with contrast echo detected 10–15 air bubbles to the left atrium during Valsalva maneuver, indicative of PFO with right-to-left shunt. Although enhanced CT did not show pulmonary embolism, it revealed severe compression at bifurcation of the inferior vena cava caused by a massive uterine myoma, as well as DVT consecutive from the left common iliac vein to the left popliteal vein (Fig. 1D). These findings suggested that thrombi in the left common iliac vein, which had entered intra-arterially through PFO were the embolic source of the multiple cerebral infarction. We provided anticoagulation treatment for cerebral infarction of the acute period, then started warfarin to prevent embolism. She did not experienced dyspnea, tachypnea, tachycardia or a hypoxic event in the clinical course of treatment. She also did not have supine hypotension syndrome, which should have suggested involvement of inferior vena cava. She refused preventive treatment of recurrences of embolism by myoma and PFO. Her neurological symptoms severely remained, and she was moved to another hospital for rehabilitation.

3. Discussion

This patient had relapsing paradoxical cerebral embolism associated with PFO and deep venous thrombosis caused by a uterine

* Corresponding author. Tel.: +81 3 3382 1231; fax: +81 3 3382 1588.
E-mail address: shuta-toru@nakanosogo.or.jp (S. Toru).

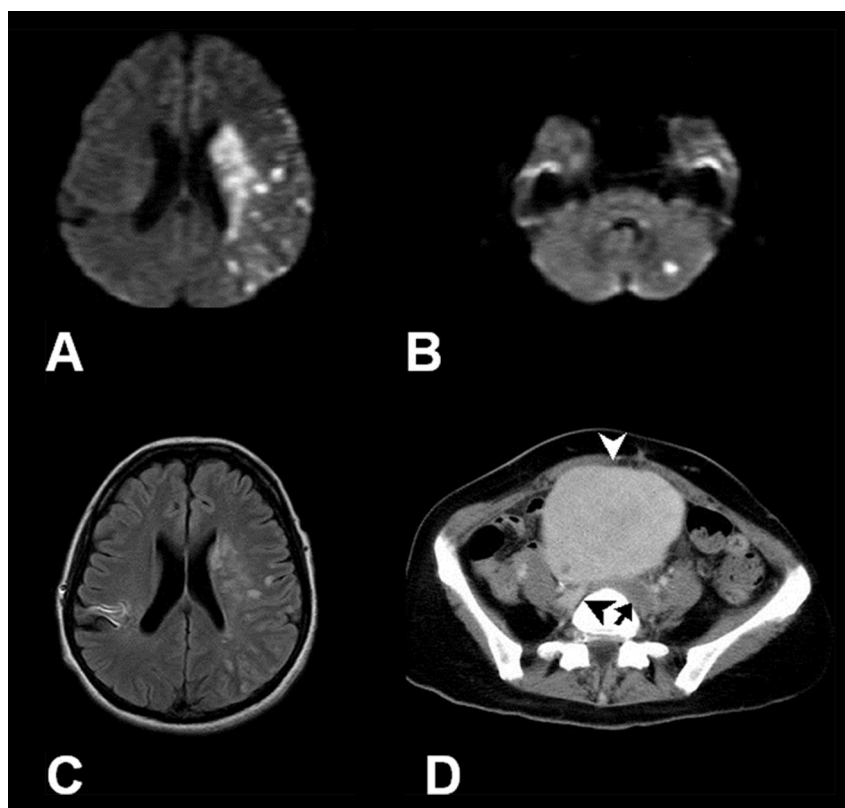


Fig. 1. (A) Diffusion weighted brain MRI image showing a fresh cerebral infarction in the left MCA area, (B) a fresh cerebral infarction in the left cerebellar hemisphere. (C) A FLAIR image of the brain MRI shows an old infarction in the right MCA area. (D) Enhanced CT reveals severe compression at bifurcation of the inferior vena cava due to a massive uterine myoma 10 cm in diameter (white arrow head) and DVT in the left common iliac vein (black arrow). The right common iliac vein (black arrow head) shows normal enhancement.

myoma. Recently, PFO has attracted attention as one cause of young or cryptogenic ischemic stroke [1]. Moreover, the incidence of PFO has been found to be frequent (27%) in autopsy specimens of human hearts [2]. A large myomatous uterus, however, rarely causes DVT leading to pulmonary embolism [3,4]. There has been only one report of cerebral embolism caused by PFO and a uterine myoma, in which DVT was detected [5].

4. Conclusion

We encountered a valuable case of multiple cerebral embolisms associated with PFO and DVT due to a giant uterine myoma. Uterine myoma should be considered as an important risk factor as an embolic source in the case of young female stroke patients with PFO.

References

- [1] Lechat P, Mas JL, Lascault G, Loron P, Theard M, Klimczak M, et al. Prevalence of patent foramen ovale in patients with stroke. *N Engl J Med* 1988;318:1148–52.
- [2] Hagen PT, Scholz DG, Edwards WD. Incidence and size of patent foramen ovale during the first 10 decades of life: an autopsy study of 965 normal hearts. *Mayo Clin Proc* 1984;59:17–20.
- [3] Nishikawa H, Ideishi M, Nishimura T, Kawamura A, Kamochi H, Tahara H, et al. Deep venous thrombosis and pulmonary thromboembolism associated with a huge uterine myoma: a case report. *Angiology* 2000;51:161–6.
- [4] Bonito M, Gulemi L, Basili R, Brunetti G, Roselli D. Thrombosis associated with a large uterine myoma: case report. *Clin Exp Obstet Gynecol* 2007;34:188–9.
- [5] Srivatsa A, Burdett J, Gill D. A 35-year-old woman with uterine fibroids and multiple embolic strokes. *Neurology* 2005;64:1479–80.