

Takayasu's arteritis: oral complications and dental guidelines

Anand Gupta, MDS, MFDS RCPS(Glasgow),^a Ongkila Bhutia, MDS,^b and Ajoy Roychoudhury, MDS,^c Chandigarh and New Delhi, India

GOVERNMENT MEDICAL COLLEGE AND HOSPITAL AND ALL INDIA INSTITUTE OF MEDICAL SCIENCES

Takayasu's arteritis (TA) is an inflammatory disease with an unknown cause. It is also known as aortic arch syndrome and pulseless disease. Complications of TA often include cerebral infarct, valvular heart disease, intracranial hemorrhage, congestive heart failure, seizures, retinopathy, and renovascular hypertension. We report a case of an 18-year-old female patient with TA who presented with a severe oral infection associated with a mandibular third molar. Such a complication in patients with TA is rare and this is probably the first reported case in the English medical literature. The patient was managed satisfactorily, with due precautions and no recurrence. More so, as the prognosis of TA has improved, the chances of dental treatments of patients afflicted with the same are likely to increase. In addition, this article highlights the guidelines for the management of patients in various dental specialties. (Oral Surg Oral Med Oral Pathol Oral Radiol 2013;116:e352-e355)

Takayasu's arteritis (TA) or aortic arch syndrome is an inflammatory disease with unknown cause. It involves the aorta, other main blood vessels from the heart, and also those attached to it. Although it has been reported worldwide, it is most commonly found in young Asian women.¹ It is also termed as the "pulseless disease" because pulses on the upper extremities (like radial pulse), may not be felt.²

Because the prognosis of TA has improved, the chances of dental treatment are likely to increase in such patients; however, because of the patients' debilitated status, oral hygiene may be poor. Consequently, during the immunosuppressed state, localized infections, such as pericoronitis, may progress into severe oral infections, such as facial cellulitis. This article presents a case of a severe oral infection in a rare disease of TA and guidelines for the management of the same.

CASE REPORT

An 18-year-old female patient in a wheelchair was brought to the outpatient department of the Centre for Dental Education and Research, All India Institute of Medical Sciences, New Delhi, India, by her parents. The chief complaint was

severe pain and swelling on the right cheek, and pus discharge from the mouth and face for the preceding 2 weeks. The patient was also finding it difficult to open her mouth. She was referred from the Department of Rheumatology for the management of facial abscess. She was a known case of TA with seizure disorder and blurring of vision in both eyes. She was prescribed antibiotics (amoxicillin 500 mg) and no intervention was made for the management of the facial abscess before reporting to our department. Further examination revealed that frank pus was draining from both extraoral and intraoral sinuses (Figure 1, A). The patient's oral hygiene was very poor with debris over the right retromolar region. The pericoronal tissue of the right mandibular third molar was swollen and erythematous (Figure 1, B). Severe trismus prevented complete intraoral examination. She was in a serious condition at the time of presentation, experiencing recurrent seizures on the dental chair, even during the examination. Furthermore, it was noted that her radial pulse was absent; blood pressure could not be recorded in either of her upper limbs, whereas in the lower limb it was 140/96 mm Hg.

Her medical history revealed a known case of TA for the preceding 4 years. Concomitantly, she had intermittent claudications and syncopal attacks on the erect posture. She had a history of hemiparesis with recurrent transient ischemic attacks. She was undergoing treatment with multiple medical specialities: rheumatology, interventional cardiology, neurology, and ophthalmology. At the time of presentation at the maxillofacial outpatient department, the patient was on immunosuppressants (azathioprine 50 mg), corticosteroids (prednisolone 20 mg), antiepileptics (sodium valproate 50 mg, levetiracetam 100 mg), and antiplatelet (aspirin 150 mg) drugs.

Funduscopy examination showed ischemic changes in her retina. Magnetic resonance image of the brain suggested the presence of an old infarct in the right occipital lobe. The angiography report showed complete blockage of the left common carotid artery and bilateral subclavian arteries, an almost complete blockage of the right common carotid artery, and thickening of the aortic wall. The activity assessment of the previous 6 months revealed an active disease with raised

^aAssistant Professor (Oral and Maxillofacial Surgery), Department of Dentistry, Government Medical College and Hospital (GMCH), Chandigarh, India.

^bAssociate Professor, Department of Oral and Maxillofacial Surgery, Centre for Dental Education and Research, All India Institute of Medical Sciences, New Delhi, India.

^cAdditional Professor, Department of Oral and Maxillofacial Surgery, Centre for Dental Education and Research, All India Institute of Medical Sciences, New Delhi, India.

Received for publication Jul 9, 2011; returned for revision Jan 2, 2012; accepted for publication Jan 18, 2012.

© 2013 Elsevier Inc. All rights reserved.

2212-4403/\$ - see front matter

<http://dx.doi.org/10.1016/j.oooo.2012.01.036>

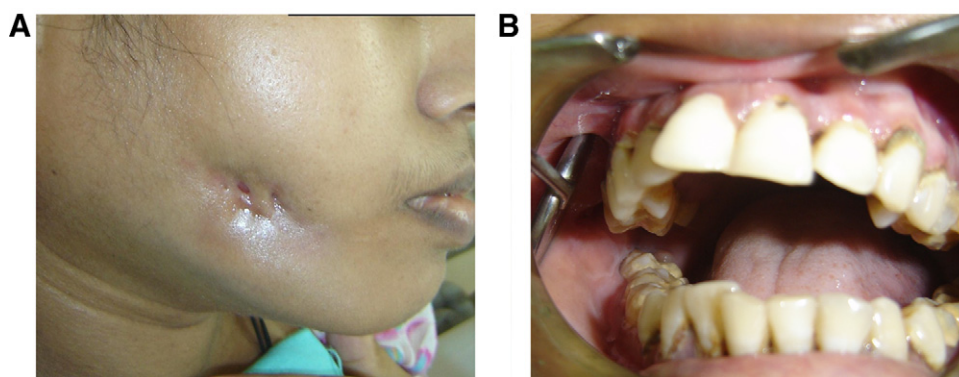


Fig. 1. **A**, Preoperative photograph showing swelling over the right cheek region with extraoral sinuses. **B**, Intraoral photograph showing trismus and pericoronitis in relation to the right mandibular third molar.

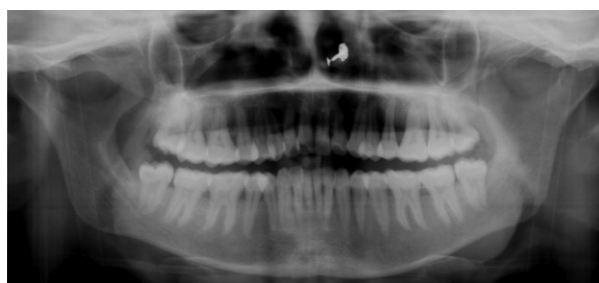

Fig. 2. Orthopantomogram showing bone resorption distal to the right mandibular third molar and anterior border of ramus.

erythrocyte sedimentation rate, C-reactive protein level, and arterial wall edema in the computed tomography angiogram. Blood and radiographic investigations were also performed. A complete blood count revealed low hemoglobin and leukocytosis with increased polymorphs. Orthopantomogram showed bone resorption distal to the right mandibular third molar, also involving a part of the anterior border of ramus (Figure 2).

On clinical and radiographic examination, the diagnosis of buccal space infection associated with pericoronitis in relation to the wisdom tooth was made. Initially, the incision and drainage of pus was done intraorally and injectable broad-spectrum antibiotic therapy (co-amoxycylav, a combination of amoxicillin and clavulanic acid) with analgesics was commenced. Pus culture and sensitivity investigation revealed *Staphylococcus aureus* species, sensitive to the combination of amoxicillin and clavulanic acid. Finally, a similar combination of antibiotics together with local wound care was maintained for a week. On the third day of the antibiotic course, approximately 1.5 cm mouth opening was achieved and the intraoral wound was meticulously debrided and irrigated. After 1 week, the patient's general condition improved and pus discharge from both the extraoral and the intraoral sites was absent. Expert opinion was taken from the rheumatology and neurology departments for a minor surgical procedure under local anesthesia. The procedure was done under strict cardiac monitoring in the dental chair, in a reclined position. Under antibiotic coverage and steroid supplementation, extraction of the mandibular third molar and curettage of

bone through the open wound was done under local anesthesia. After 2 weeks, the extraoral sinuses were healed and there were no signs of infection (Figure 3, A). She regained normal mouth opening and was encouraged to maintain proper oral hygiene (Figure 3, B). In the meantime, oral prophylaxis was done to improve oral health.

During the follow-up visits, pericoronal inflammation around the opposite side mandibular wisdom tooth was noticed. The offending tooth was extracted prophylactically under antibiotic coverage to prevent further complications, as the patient will have to remain on immunosuppressants long-term to control the TA disease. The follow-up examination 2 years later showed no recurrence and the orthopantomogram showed smooth anterior border of ramus together with complete healing of extraction sockets of the bilateral mandibular third molars. Adherence to proper oral hygiene measures, regular dental visits, and checkups were advised.

DISCUSSION

TA was first reported by Takayasu, a Japanese ophthalmologist, in 1908. It was defined as a condition involving a peculiar type of arteriovenous fistulas in the eyes.³ Although its etiology is unknown, some studies suggest that it may be an autoimmune disorder⁴ or it may occur after certain types of infections.¹ Although it affects people of all ethnic backgrounds, this predilection is most commonly seen in Asian women of childbearing age.⁵ The symptoms depend on the intensity and location of the inflammation in the body. Symptoms of TA may follow a pattern of stages. The first stage may present with fatigue, malaise, muscle aches, headaches, joint pain, skin rash, fever, or sometimes weight loss. The second stage (or vascular inflammatory stage) may present with pain in the extremities and joints, arm numbness, blurry or double vision, headaches, or shortness of breath. These symptoms may occur because of reduced blood supply to the affected area. Occasionally, the symptoms of the first and second stages may occur together. The third stage is usually associated with remission, but this stage does not occur in all

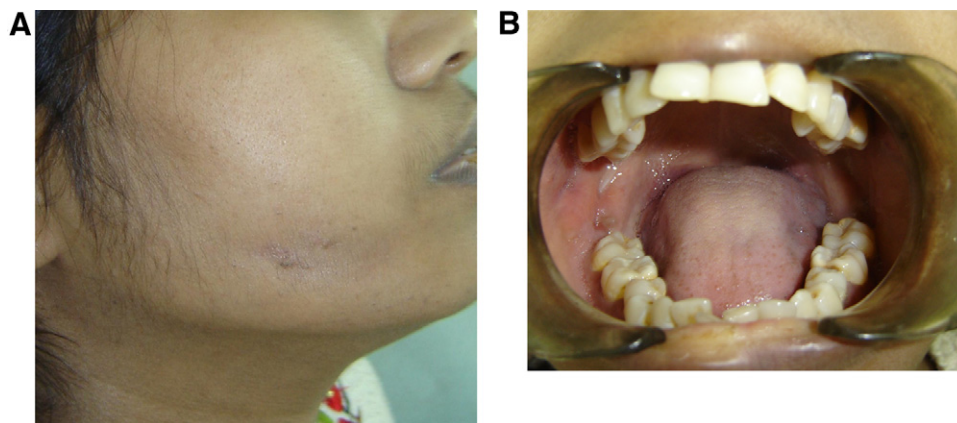


Fig. 3. **A**, Postoperative photograph showing healed extraoral sinuses and healthy skin. **B**, Intraoral photograph showing adequate mouth opening and healed intraoral extraction sites-bilateral mandibular third molars.

individuals. Also, the possibility of a relapse must be noted.⁶

Laboratory findings may show anemia, raised erythrocyte sedimentation rate, and the C-reactive protein test may show signs of inflammation.⁷ Furthermore, angiography using radiopaque dye can confirm the presence of the TA disease.

The goal of treatment is to reduce inflammation and slow or stop the autoimmune disease process. This can be achieved with corticosteroid medication, such as prednisone, and it may require administration for a long time. If corticosteroids do not reduce the symptoms, cytotoxic drugs, such as methotrexate, azathioprine, or cyclophosphamide, may be given.⁶

Recent advances of medical and surgical treatments, including endovascular interventions, have improved the prognosis of patients with stenotic/occlusive or dilated lesions. Several authors have tried to document predictive factors for the outcome of this disease after medical treatment.⁸⁻¹⁰ Among them, the grouping by Ishikawa⁸ revealed a good association with the life expectancy of patients and was adopted by others.⁹ Miyata et al.¹¹ did a retrospective study to elucidate the role of surgery in patients with TA by reviewing the long-term course of 106 consecutive patients treated surgically. The overall cumulative survival rate at 20 years was found to be 73.5%. The prognostic classification by Ishikawa⁸ had little influence on the survival of surgically treated patients. Surgery showed increased survival for stage 3 patients; however, for stage 1 patients, surgery-related complications conversely decreased survival.¹¹

Complications of TA may include cerebral infarct, valvular heart disease, intracranial hemorrhage, congestive heart failure, seizures, retinopathy, and renovascular hypertension.¹² The reported case is a young Asian

female patient who already had complications of cerebral infarct, seizures, and retinopathy. A thorough search of the biomedical literature on Medline did not highlight any case with complications in the maxillofacial region except for one case report on dental specialty that emphasized tooth extraction in Takayasu's syndrome.¹³ The cause of oral infection in the mentioned case could be immunosuppression, owing to anemia and immunosuppressant drugs. The infection must have started from the pericoronitis of the wisdom tooth and spread into the fascial space because of the patient's immunocompromised status and poor oral hygiene.

The principles of management of odontogenic infection are to determine the severity of infection, evaluate host defense, treat surgically, support medically, choose and prescribe antibiotic therapy, administer the antibiotic properly, and evaluate the patient frequently. All the mentioned principles were implemented properly and stage-wise treatment was given according to the compromised status of the patient.¹⁴

Yoshimura¹³ emphasized several problems of tooth extraction in patients with TA. He also stressed several points to be taken into consideration during the dental procedures in such patients. Based on his findings, some guidelines together with the problem list are enumerated for the management of patients with TA during dental procedures.

GUIDELINES FOR DENTAL PROCEDURES IN PATIENTS WITH TA

During all dental procedures, care must be taken to position the head in the most relaxed way so there is no pressure or stretch on the carotid sinus region. Excessive neck bending movements must be avoided because of impairment or hypersensitivity of the carotid sinus in

some patients with TA, which may lead to bradycardia or cardiac arrest. All the surgical procedures should be done in the inactive phase (remission) of the disease. The activity of this disease can be evaluated from clinical signs and symptoms (such as easy fatigability, general malaise, arthralgia, pain in blood vessels, and fever) and laboratory investigations, such as erythrocyte sedimentation rate, C-reactive protein level, high titer of antistreptolysin-O, increased gamma globulin, and leukocytosis.

Importantly, all dental procedures should be done under cardiac monitoring. It is beneficial to the operator to examine the patient's electrocardiogram, blood pressure, and pulse rate before starting the treatment. Because no pulsation is present at any extremity in many patients, careful monitoring is essential during treatment. In fact, it is often not realized that the symptoms derived from hypoperfusion of the cerebral circulation, which is a result of hyper or impaired reflexes of the carotid sinus and/or vagal nerve, may be mistaken for a dental shock. Therefore, it is preferable to treat these patients in a hospital setting to prevent any unwanted complications.

Importantly, antibiotic coverage should be given before any surgical procedure. The probable explanation could be that the bacteremia caused during any dental surgical procedure may lead to attachment and proliferation of bacteria at the intima of aorta, main branches, and pulmonary arteries with inflammatory granulation surfaces. Antibiotic coverage is also important because of the immunocompromised state of the patients, who are usually kept on immunosuppressants for the management of this disease.

Most surgical or painful dental procedures should be done under steroid supplementation, therefore taking care of any interaction of various prescribed drugs, such as anticoagulants, antihypertensives, and immunosuppressants. For minor oral and periodontal surgery, evidence suggests that adrenal insufficiency may be prevented when circulating levels of glucocorticoids are about 25 mg of hydrocortisone equivalent per day. This is equivalent to a dosage of about 5 mg of prednisone. In patients taking high dosages of steroid (more than 5 mg prednisolone), however, the usual dose should be doubled on the day of the procedure. It is recommended to schedule the surgery in the morning hours when normal cortisol levels are at the highest.

In conclusion, dental problems in a patient with TA are inevitable and their management needs extra precautions and monitoring to avoid any unwanted complications. The enumerated guidelines and the possible complications may provide enough knowledge of the disease and give confidence to the dental practitioner to manage such patients efficiently and satisfactorily.

REFERENCES

1. Lupi-Herrera E, Sánchez-Torres G, Marcushamer J, Mispireta J, Horwitz S, Vela JE. Takayasu's arteritis: clinical study of 107 cases. *Am Heart J* 1977;93:94-103.
2. James WD, Berger TG, Elston DM, Odom RB. *Andrews' diseases of the skin: clinical dermatology*. Philadelphia, PA; Saunders Elsevier; 2006. p. 841.
3. Takayasu M. A case with unusual changes of the central vessel in the retina. *Acta Soc Ophth Jap* 1908;12:554.
4. Noris M. Physiopathology of Takayasu's arteritis. *J Nephrol* 2001;14:506-13.
5. Koenig CL, Langford CA. Takayasu's arteritis. *Curr Treat Options Cardiovasc Med* 2008;10:164-72.
6. Johnston SL, Lock RJ, Gompels MM. Takayasu arteritis: a review. *J Clin Pathol* 2002;55:481-6.
7. Choe YH, Han BK, Koh EM, Kim DK, Do YS, Lee WR. Takayasu's arteritis: assessment of disease activity with contrast-enhanced MR imaging. *AJR Am J Roentgenol* 2000;175:505-11.
8. Ishikawa K. Patterns of symptoms and prognosis in occlusive thromboaropathy (Takayasu's disease). *J Am Coll Cardiol* 1986;8:1041-6.
9. Subramanyan R, Joy J, Balakrishnan KG. Natural history of aortoarteritis (Takayasu's disease). *Circulation* 1989;80:429-37.
10. Ishikawa K, Maetani S. Long-term outcome for 120 Japanese patients with Takayasu's disease. Clinical and statistical analyses of related prognostic factors. *Circulation* 1994;90:1855-60.
11. Miyata T, Sato O, Koyama H, Shigematsu H, Tada Y. Long-term survival after surgical treatment of patients with Takayasu's arteritis. *Circulation* 2003;108:1474-80.
12. Park MC, Lee SW, Park YB, Chung NS, Lee SK. Clinical characteristics and outcomes of Takayasu's arteritis: analysis of 108 patients using standardized criteria for diagnosis, activity assessment, and angiographic classification. *Scand J Rheumatol* 2005;34:284-92.
13. Yoshimura Y. Tooth extractions and aortitis syndrome (Takayasu's disease). *Int J Oral Surg* 1981;10:1.
14. Miloro M. *Peterson's principles of oral and maxillofacial surgery*. 2nd ed. Hamilton (ON): B. C. Decker; 2004. p. 277.

Reprint requests:

Anand Gupta, MDS, MFDS RCPS(Glasgow)
 Assistant Professor (Oral and Maxillofacial Surgery)
 Department of Dentistry
 Government Medical College and Hospital (GMCH)
 Sector 32 B
 Chandigarh, India Pin code 160030
 dranand_kgmc@rediffmail.com