

SHORT REPORT

An unusual aneurysm of a basilar perforating artery presenting with a subarachnoid haemorrhage

Vino Apok, Andrew Tarnaris & Howard L. Brydon

Department of Neurosurgery, University Hospital of North Staffordshire, North Staffordshire Royal Infirmary, Stoke-on-Trent, UK

Abstract

A 65-year-old man had a perimesencephalic subarachnoid haemorrhage with normal angiography initially. After a rebleed 5 days later, a repeat angiogram revealed a pea-like aneurysm a short distance behind and below the basilar bifurcation. It was not amenable to endovascular treatment and the feeding vessel was coagulated and divided at open surgery via a sub temporal approach. He developed a right hemiparesis and dysphasia, from which he slowly recovered. Basilar perforating artery aneurysms are extremely rare, with only 4 previous cases reported.

Keywords: basilar artery; cerebral aneurysm; hematoma; subarachnoid haemorrhage

Introduction

Aneurysms of the distal basilar artery are estimated to represent 5–8% of all intracranial aneurysms.¹ Aneurysms of the perforating arteries in this region are exceedingly rare. To date, there have been only five reported cases in the literature.

Case report

A 64-year-old, Italian man, who was fluent in spoken English, presented to the Accident and Emergency department complaining of a sudden onset occipital headache. There were no associated symptoms. He had a background history of hypertension and type II diabetes mellitus, and was a smoker.

On examination, he was alert and orientated and there was no focal neurological abnormality. Urgent computed tomography (CT) of his head confirmed a Fisher grade 3 subarachnoid haemorrhage (Fig. 1). However, initial CT angiography was normal. He had four vessel cerebral angiography which showed no evidence of an aneurysm. He was discharged 5 days later with arrangements for an outpatient MR scan.

Later that evening, he experienced a gradual onset of a new headache that was similar in nature to his previous headache. There was no photophobia and no systemic symptoms. The following day, he was nauseated and vomited. His headache worsened and he presented.

On admission, he was eye opening to speech, conversing normally and obeying commands. He had no neurological deficit. A new CT scan of his head indicated a rebleed and CT angiography showed a 6 × 5 mm pea-like aneurysm a short distance behind and slightly proximal to the basilar bifurcation (Fig. 2). A catheter angiogram confirmed the aneurysm, which was connected to the artery by a short stalk (Fig. 3). The stalk was longer and narrower than it appeared on the CT angiogram and was estimated to be only half the diameter of the angiogram catheter. Embolisation was not possible as the feeding vessel could not be catheterised.

He underwent a temporal minicraniotomy for securing of the aneurysm. Intraoperatively, a large amount of organised

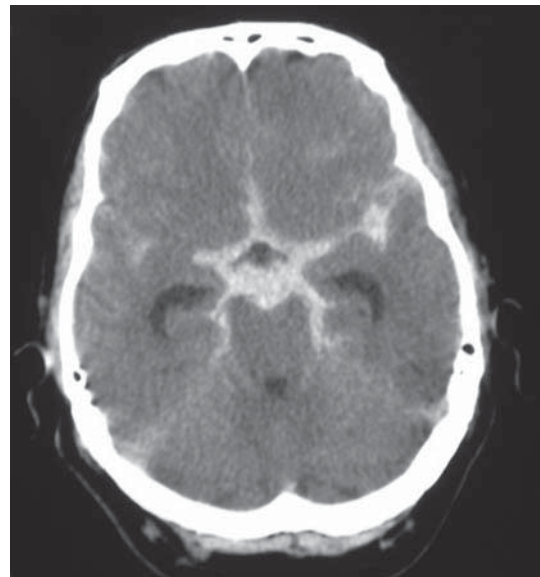


Fig. 1. Initial CT scan showing a Fisher grade 3 subarachnoid haemorrhage.

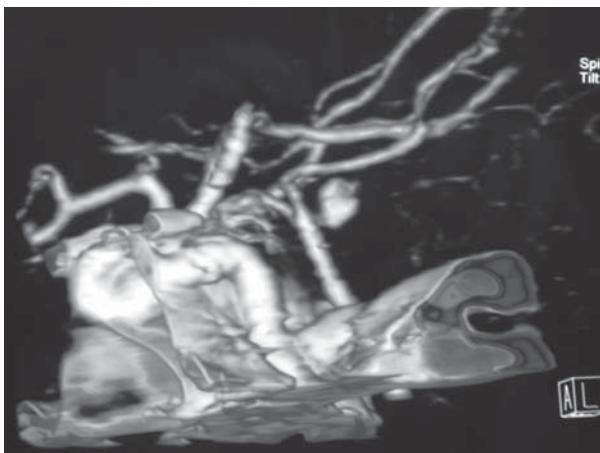


Fig. 2. CT angiogram showing a pea-like aneurysm a short distance behind the basilar bifurcation and connected to it by a short stalk.

clot was found surrounding the aneurysm and the clot was removed piecemeal with fine rongeurs. This opened the aneurysm sac, but the bleeding was slight as the feeding vessel was so narrow. The stalk was coagulated and was divided without the use of a clip.

He had a right hemiparesis and dysphasia on awaking from anaesthesia. A CT scan was satisfactory and nimodipine was injected into the basilar artery for presumed vasospasm. A lumbar drain was inserted 4 days later for hydrocephalus causing drowsiness. A CT the following week revealed a small area of brain stem hypodensity. He had a tracheostomy 11 days postoperatively because of a poor GCS and an inability to protect his airway. His recovery was further complicated by a chest infection. A right ventriculoperitoneal shunt was inserted 3 weeks after the aneurysm surgery.

The rest of his inpatient stay was uneventful and he continued to make slow progress with rehabilitation input.

His tracheostomy was removed when his consciousness had improved sufficiently. He was eventually discharged to a rehabilitation centre. At the time of discharge, his conscious level had improved significantly (GCS: 15/15). He was still hemiplegic on the right, although was able to sit independently. He also had poor short-term memory and a poor attention span.

At a 6-month outpatient clinic review, he had improving function of his right arm but still had significant dysphasia. He had reverted to Italian as his first language.

By 20 months his cognitive function had greatly improved as has his fluency in both languages. However, as he could converse easier in Italian, he decided to return to Italy permanently. His arm function was almost back to normal and he could take full personal care of himself. He could walk slowly for long distances with a walking stick.

Discussion

Basilar perforating aneurysms are very rare, with only 5 previous reports in the literature.¹⁻⁵ They are difficult to diagnose with the initial angiogram being inconclusive in four cases (including this case). One other case had a re-bleed before the aneurysm was diagnosed. The failure to diagnose them on initial angiography is probably because they are low flow aneurysms, with spasm or thrombus further hindering their visualisation.³ However, they can still re-bleed in spite of this.

The location of these aneurysms has varied. Two originated close to the origin of the superior cerebellar artery,^{1,4} one posterolaterally,¹ whereas another arose posteriorly from the mid third of the basilar trunk.² The other two aneurysms were in the midline, close to the basilar tip,^{3,5} in a similar position to this aneurysm.

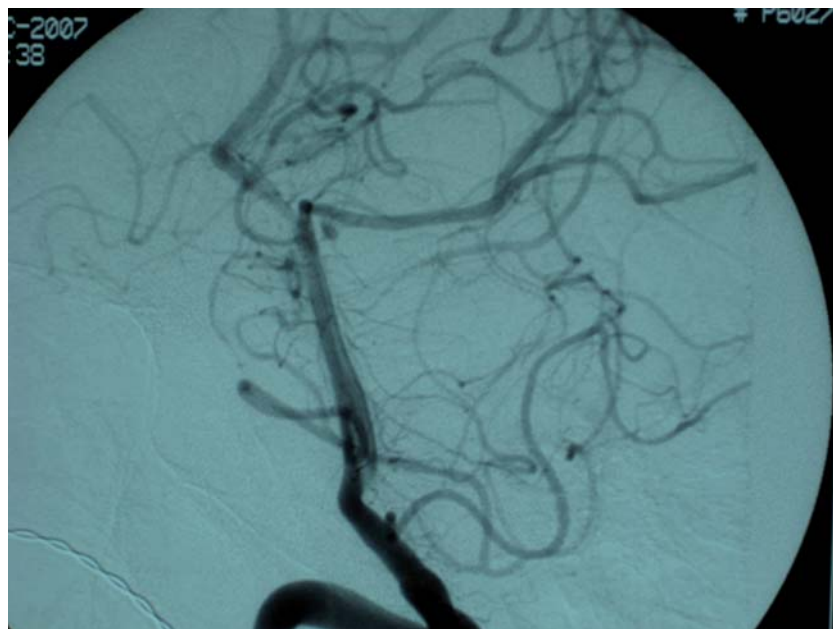


Fig. 3. Catheter vertebral artery angiogram showing the aneurysm behind the basilar bifurcation with a longer narrower stalk than on the CT angiogram.

Two cases of basilar circumflex artery aneurysms have also been reported.³ They were both very lateral and the parent vessels both originated at the level of the AICA. One was a post-traumatic pseudo-aneurysm in a 2-year-old-boy.

In no case has the aneurysm been suitable for endovascular embolisation, as the feeding vessel was so narrow. One case has been treated with flow-diverting (pipeline) stents, but two devices were necessary, one inside the other, as the initial stent still allowed aneurysm filling.⁵

One author has reported that it was possible to clip the aneurysm and preserve the parent vessel,¹ but the others reported that preserving the vessel was not possible and the aneurysms have been managed by coagulating or clipping the feeding vessel, with coagulation of the distal vessel, if one was present. In our case a distal vessel from the aneurysm was not seen.

One surprising feature of this case was the nature of the organised subarachnoid haematoma, which made surgery very difficult. We have been unable to find any other report of subarachnoid haemorrhage organising in such a manner.

It has been postulated that basilar perforating artery aneurysms could be responsible for perimesencephalic haemorrhages in some patients and that repeat angiography should be performed after an interval.³ However, the risk of rebleeding after a perimesencephalic bleed is so low that it is debatable if this can be justified.^{6,7}

It has been reported that these aneurysms have an excellent prognosis.³ However, our patient suffered from cerebral ischaemia that has resulted in significant disability. This was in part due to the operative difficulties caused by the subarachnoid thrombus. We therefore conclude

that these aneurysms present particular difficulties that can result in a poor outcome. However, there have been no reported deaths from these aneurysms, either from a rebleed or after surgery.

Conclusions

Basilar perforating aneurysms are very rare, but present unique therapeutic difficulties. They are often missed on initial angiography, but are susceptible to rebleeding. To date, they have only been manageable by open surgery.

Declaration of interests: The authors have no conflicts of interest to declare. The authors alone are responsible for the content and writing of the paper.

References

1. Ghogawala Z, Shumacher JM, Ogilvy CS. Distal basilar perforator artery aneurysm: case report. *Neurosurgery* 1996;39:393-6.
2. Hamel W, Grzyska U, Westphal M, Kehler U. Surgical treatment of a basilar perforator aneurysm not accessible to endovascular treatment. *Acta Neurochirurgica (Wien)* 2005;147:1283-6.
3. Sanchez-Mejia RO, Lawton MT. Distal aneurysms of basilar perforating and circumferential arteries. Report of three cases. *J Neurosurg* 2007;107:654-9.
4. Mathieson CS, Barlow P, Jenkins S, Hanzely Z. An unusual case of spontaneous subarachnoid haemorrhage - a ruptured aneurysm of a basilar perforating artery. *Br J Neurosurg* 2010;24:291-3.
5. Deshaies EM, Jacobsen W, Krishnamurthy S. Enterprise stent-within-stent embolization of a basilar artery perforator aneurysm. *World J Neurosci* 2011;1:45-8.
6. Greebe P, Rinkel GJ. Life expectancy after perimesencephalic subarachnoid hemorrhage. *Stroke* 2007;38:1222-4.
7. Huttner HB, Hartmann M, Kohrmann M, *et al.* Repeated digital subtraction angiography after perimesencephalic subarachnoid hemorrhage? *J Neuroradiol* 2006;33:87-9.