

Neurocase: The Neural Basis of Cognition

Publication details, including instructions for authors and subscription information:

<http://www.tandfonline.com/loi/nncs20>

Transient improvement in sensorimotor conversion during post-anoxic encephalopathy with bilateral medial temporal ischemia

Eloi Magnin^{acd}, Yavor Delchev^f, Gilles Chopard^{abcd}, Eric Berger^{ac}, Pierre Vandel^{bcd}, Daniel Sechter^{bd}, Lucien Rumbach^{ac} & Emmanuel Haffen^{bde}

^a Department of Neurology, University Hospital of Besançon, Besançon, France

^b Department of Clinical Psychiatry, University Hospital of Besançon, Besançon, France

^c Memory Center of Research and Resources (MCRR), University Hospital of Besançon, Besançon, France

^d EA 481 Neuroscience, IFR 133, University of Franche-Comté, Besançon, France

^e Clinical Investigation Center CIC-IT 808 INSERM, University Hospital of Besançon, Besançon, France

^f Department of Clinical Psychiatry, Hôpital Européen Georges Pompidou, Paris, France

Published online: 29 Aug 2012.

To cite this article: Eloi Magnin, Yavor Delchev, Gilles Chopard, Eric Berger, Pierre Vandel, Daniel Sechter, Lucien Rumbach & Emmanuel Haffen (2013) Transient improvement in sensorimotor conversion during post-anoxic encephalopathy with bilateral medial temporal ischemia, *Neurocase: The Neural Basis of Cognition*, 19:6, 576-582, DOI: [10.1080/13554794.2012.713488](https://doi.org/10.1080/13554794.2012.713488)

To link to this article: <http://dx.doi.org/10.1080/13554794.2012.713488>

PLEASE SCROLL DOWN FOR ARTICLE

Taylor & Francis makes every effort to ensure the accuracy of all the information (the "Content") contained in the publications on our platform. However, Taylor & Francis, our agents, and our licensors make no representations or warranties whatsoever as to the accuracy, completeness, or suitability for any purpose of the Content. Any opinions and views expressed in this publication are the opinions and views of the authors, and are not the views of or endorsed by Taylor & Francis. The accuracy of the Content should not be relied upon and should be independently verified with primary sources of information. Taylor and Francis shall not be liable for any losses, actions, claims, proceedings, demands, costs, expenses, damages, and other liabilities whatsoever or howsoever caused arising directly or indirectly in connection with, in relation to or arising out of the use of the Content.

This article may be used for research, teaching, and private study purposes. Any substantial or systematic reproduction, redistribution, reselling, loan, sub-licensing, systematic supply, or distribution in any form to anyone is expressly forbidden. Terms & Conditions of access and use can be found at <http://www.tandfonline.com/page/terms-and-conditions>

Transient improvement in sensorimotor conversion during post-anoxic encephalopathy with bilateral medial temporal ischemia

Eloi Magnin^{1,3,4}, Yavor Delchev⁶, Gilles Chopard^{1,2,3,4}, Eric Berger^{1,3}, Pierre Vandel^{2,3,4}, Daniel Sechter^{2,4}, Lucien Rumbach^{1,3}, and Emmanuel Haffen^{2,4,5}

¹Department of Neurology, University Hospital of Besançon, Besançon, France

²Department of Clinical Psychiatry, University Hospital of Besançon, Besançon, France

³Memory Center of Research and Resources (MCRR), University Hospital of Besançon, Besançon, France

⁴EA 481 Neuroscience, IFR 133, University of Franche-Comté, Besançon, France

⁵Clinical Investigation Center CIC-IT 808 INSERM, University Hospital of Besançon, Besançon, France

⁶Department of Clinical Psychiatry, Hôpital Européen Georges Pompidou, Paris, France

We report the case of a patient with sensorimotor conversion that improved transiently during post-anoxic medial temporal ischemia inducing anterograde and retrograde amnesia. Symptoms reappeared in parallel with mnemonic recovery. This case raises a hypothesis concerning the role of hippocampi and amygdalae, which are involved in emotionally-associated memory. The amnesia may have modified the patient's "self," giving her a "distant" point of view. Another hypothesis is that cerebral anoxic stress may have "reset" the cerebral network that controls behavior. These findings give clues about the mechanisms of somatoform disorder and highlight the possibility of specific therapeutic strategies to induce cognitive reappraisal of emotionally-associated experiences.

Keywords: Conversion disorders; Emotionally-associated memory; Amygdala; Hippocampus; Post-anoxic amnesia.

Conversion disorder is the term used in DSM-IV-TR to describe motor and/or sensory symptoms that lack a medical explanation (American Psychiatric Association, 2000). Functional symptoms affect approximately one-third of new neurological outpatients (Carson et al., 2000). This disorder has been reported in 1–3% of outpatient

referrals in mental health clinics, and in the general population rates range from 0.01 to 0.3% (American Psychiatric Association, 1994). Psychological, social, or medical precipitants are frequently observed. An organic cause must be excluded, and structural imagery is normal. Our understanding of the neural correlates of conver-

Author correspondence to Dr Eloi Magnin, Department of Neurology, University Hospital of Besançon, Besançon 25030, France. (E-mail: eloi.magnin@laposte.net).

The authors wish to thank Frances Sheppard of the Clinical Investigation Center of Besançon for correcting and improving the English in the manuscript.

Competing interests: None.

Ethics committee approval and patient consent: This case report was approved by the local ethics committee in accordance with the Declaration of Helsinki on Biomedical Studies involving human subjects. The patient signed an informed consent form.

sion is at the beginning, and the conclusions of neuroimaging studies are uncertain due to many confounding factors, small numbers of subjects, varying study designs, and heterogeneous populations (Vuilleumier, 2005). However, functional imagery (positron emission tomography scan, functional magnetic resonance imagery, and single-photon emission computed tomography (SPECT)) sometimes identifies a “functional or dynamic lesion,” in accordance with Charcot’s theory proposed at the end of the nineteenth century (Cojan, Waber, Carruzzo, & Vuilleumier, 2009; Sellal, Manning, Seegmuller, Scheiber, & Schoenfelder, 2002; Tiihonen, Kuikka, Viinamäki, Lehtonen, & Partanen, 1995; Vuilleumier et al., 2001). It has been found that the effect (but not the cause) of underlying mechanisms in psychogenic disorders is that a cortical and/or subcortical repression phenomenon can induce functional hypometabolism. The origin of the repression phenomenon remains unclear, although some studies have demonstrated increased cerebral activations, suggesting active inhibition from limbic structures (such as the cingulate or orbitofrontal cortex) (Cojan et al., 2009; Vuilleumier, 2005). This latter phenomenon may be common to both hysteria and hypnosis (Bell, Oakley, Halligan, & Deeley, 2011). These functional abnormalities disappear spontaneously as symptoms improve. Treatment is not chosen based on a clear understanding of the underlying pathophysiology of conversion disorder. Transient recuperation in conversion disorder can occur with persuasion, hypnosis, or psychotherapy, but pharmacological treatments do not have much effect. However, treating resistant conversion disorders remains a challenge for clinicians. In some cases, no treatment is effective, often leading to a high risk of chronicity and complications.

We report a case of sensorimotor conversion that resolved completely during post-anoxic encephalopathy with medial temporal ischemia with retrograde and anterograde episodic amnesia. However, conversion symptoms reappeared in parallel with mnesic recovery.

CASE REPORT

A 52-year-old right-handed woman who worked as a commercial representative and had three daughters was facing major family, financial, and professional difficulties. She lived with two of her daughters.

Her medical history was marked by diffuse chronic pain since 2001. Neck and lumbar back pain appeared following two car accidents that may have been suicide attempts. The most disabling symptoms were lumbar back pain associated with left lower limb pain and motor deficit. The symptoms corresponded to both left L5 and S1 radicular topography. Tomodensitometry of the lumbar spine showed left L5 and S1 herniated discs with no sign of nerve compression. Hyperalgesic and paralytic sciatica was diagnosed and the patient underwent surgery in 2004. The symptomatology did not improve. Three weeks later, an electroneuromyogram was normal, suggesting a non-organic symptomatology, and she was referred to a rehabilitation center. Her left foot became totally paralyzed and chronic pain required numerous specialized consultations over the following 2 years. Symptomatology improved slightly with morphine treatment. She required a foot lifter for her left foot and a cane in the right hand in order to walk.

A psychiatrist diagnosed sensorimotor conversion with a histrionic personality disorder. A major depressive disorder appeared later. A 6-month course of tricyclic and serotonergic antidepressant treatment did not improve the symptomatology.

In 2006, her two daughters left home, which was traumatic for her. One month later, the patient was admitted to the intensive care unit for suicide attempt by poisoning with benzodiazepine and oxycodone. She was found at home, probably after a prolonged coma. Her condition was critical (Glasgow Coma Scale: 3; oximetry oxygen saturation: 65%; hypothermia at 33°C). Outcome was favorable with total recovery of consciousness 48 hours later. Confusion and disorientation in time and space associated with anterograde and retrograde amnesia were observed. No abnormal reflex and no focal sensory or motor deficit was observed. Five days after the suicide attempt, a neuropsychological examination, including the RAPID battery (Ferreira et al., 2010), found severe anterograde amnesia (neuropsychological examination in Table 1). Her retrograde amnesia was focused on memories of the last 3 years, such as her medical history of chronic pain and limb deficit, rehabilitation, and her daughters’ departure. Furthermore, she was unable to describe her suicide attempt or her psychological state prior to it. She also had an anosodiaphoria with indifference to her memory disorders. She no longer suffered from pain disorder or left lower limb motor

TABLE 1
Cognitive performances for the patient 5 days (time 1), 2 months (time 2), and 5 months (time 3) after suicide attempt

<i>Neuropsychological tests</i>	<i>Time 1</i>	<i>Time 2</i>	<i>Time 3</i>
<i>Mini-Mental State Examination</i>			
Total score (range 0–30)	22*	24*	23*
Orientation to time (range 0–5)	3*	3*	3*
Orientation to place (range 0–5)	4*	5	5
<i>Memory Impairment Screen</i> (range 0–8)	0*	3*	2*
<i>Free and Cued Selective Reminding Test</i>			
Immediate recall (range 0–16)	NA	15*	14*
Free recall (range 0–48)	NA	6*	10*
Total recall (range 0–48)	NA	24*	25*
Recognition (range 0–16)	NA	12*	13*
False recognition (cut-off > 1)	NA	2*	0
Free delayed recall (range 0–48)	NA	0*	4*
Total delayed recall (range 0–48)	NA	5*	11*
<i>Isaac Set Test</i> (cut off <25)	29	32	25
<i>Trail-Making Test</i>			
Part A (range 0–150)	30	33	44
Part B (range 0–300)	85	84	87
<i>Picture naming</i> (range 0–30)	29*	30	30
<i>Copy</i> (range 0–6)	6	6	6

*Impaired performances (<5th percentile).

deficit, confirming the diagnosis of sensorimotor conversion.

One week after the suicide attempt, an magnetic resonance imagery (MRI) examination showed T2 and diffusion hyperintense signals of the bilateral medial temporal lobe, hippocampus, amygdala, and mamillary bodies corresponding to post-anoxic lesions (Figure 1).

Five months after the suicide attempt, her neuropsychological performances in episodic memory tests remained pathological (Table 1), while her ecological anterograde memory gradually improved along with a progressive reappearance of paresthesia, pain, and then motor deficit in the left lower limb between the third and fifth month after the overdose. Six months after the suicide attempt, while conversion symptoms had reappeared, a cerebral SPECT (99mTc-ethyl cysteinate dimmer) examination found hypoperfusion of the bilateral medial temporal cortices and superior frontal cortices as well as the right thalamus and right perirolandic cortex (Figure 1). A second MRI, performed 6 months after the suicide attempt, showed that pathological hypersignal had disappeared and a mild bilateral hippocampal atrophy predominated on the left side. No MRI abnormality in the right hemispheres and frontal superior gyri was observed. This suggests that some

of the hypometabolisms observed in the SPECT examination are not secondary to brain injuries but rather relate to changes in metabolism.

DISCUSSION

Evolution of conversion is very hard to predict. Cases of conversion sometimes improve dramatically. A medical event (such as minor brain injury or an overdose, for example) can be a triggering factor in recovery. The mechanisms involved in recovery and relapse of conversion remain mostly unknown. This single case of sensorimotor conversion improving transiently during a post-anoxic medial temporal ischemia with retrograde and anterograde episodic amnesia and subsequently reappearing alongside mnemonic recovery, does not, of course, enable us to understand the mechanisms of conversion, nor does it solve the problem of how best to treat it. However, it raises questions about these mechanisms and the brain changes that may play a role in conversion recovery. Based on our neuroimaging findings and neuropsychological data, as well as the literature, we hypothesize that brain and memory changes, induced by the post-anoxic encephalopathy, participate in this recovery. We draw parallels with

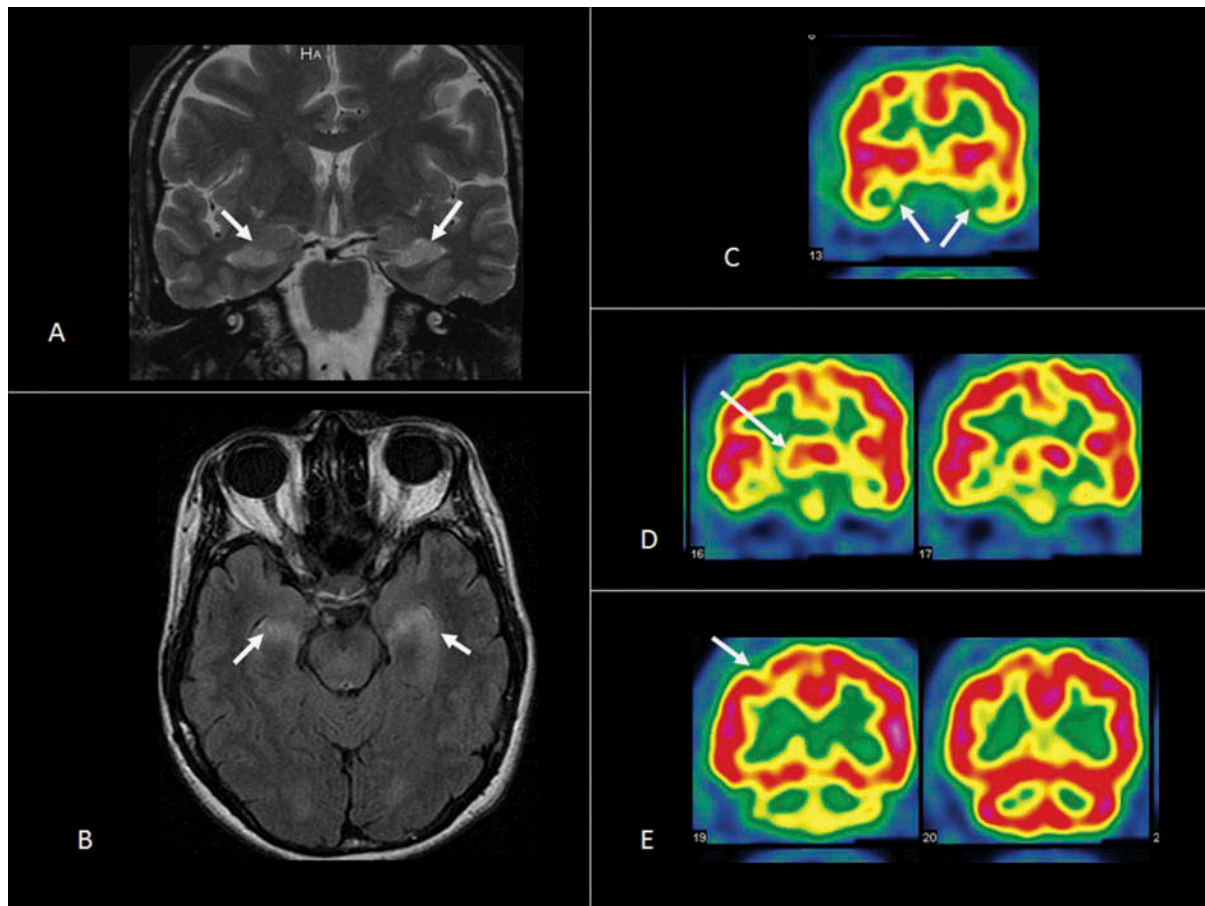


Figure 1. Imaging findings: MRI: T2 (A) and FLAIR (B) hypersignal of bilateral medial temporal lobe (hippocampus and amygdala). SPECT: Hypoperfusion of bilateral medial temporal cortices (C), right thalamus (D), and right sensitive motor cortex (E). [To view this figure in color, please see the online version of this Journal].

electroconvulsive therapy (ECT), which induces cognitive impairment and predominantly affects memory (Fraser, O'Carroll, & Ebmeier, 2008) and which may be helpful in treating refractory post-traumatic stress disorder (PTSD) (Margoob & Andrade, 2010).

Three hypothetical mechanisms involved in conversion, which are not mutually exclusive, are discussed: (1) change from conversion disorder to dissociative amnesia; (2) role of hippocampi and amygdalae in the emotionally-associated episodic memory; and (3) cerebral anoxic stress as a behavioral "reset" induced by neural plasticity.

First, in this context of a depressive episode, and because of traumatic events (her daughters' departure, suicide attempt), the conversion symptomatology may have changed into dissociative amnesia with retrograde amnesia, inducing an inability to recall basic personal information, including traumatic or stressful experiences. However, this diagnosis was excluded because

the cerebral lesions were consistent with an amnesic syndrome and retrograde amnesia was not disproportionate (no loss of personal identity, respect of the time-gradient of Ribot's law, as she forgot recent events but not diffuse autobiographical knowledge).

Second, the localization of cerebral ischemic lesions suggests that the hippocampi and amygdalae may play a role in the symptoms of conversion. These structures are involved in episodic and emotionally-associated memory (Grubb et al., 2000; Holemans, Dupuis, Misson, & Vanderijst, 2001; Kartsounis, Rudge, & Stevens, 1995; Zola-Morgan, Squire, & Amaral, 1986). Most of the patient's autobiographical memory was preserved, except for impaired spontaneous recollection of the previous 3 years, especially psychological experience (prior depression, suicide attempt). Anosodiaphoria could reflect the dysfunction of the hippocampus/amygdala complex. Personal history and experience, which are closely

linked to emotionally-associated episodic memory, play an important role in personality. Emotionally-associated memories (especially traumatic events) may induce disturbances in the sensorimotor network. The retrograde amnesic period encountered conversive motor deficit appearance (3 years beforehand). This “experimental” episodic and emotionally-associated amnesia could have cleared up the patient’s conversion disorders. This alteration of memory may have transiently modified her “self” (personal goals, self-image), also changing her sensorimotor knowledge (conversion and pain), and giving her a more “distant” point of view and a form of “self-neglect” of the somatoform disorder. The medial temporal lobe is closely connected with the medial prefrontal cortex, which is an important structure involved in the construction of the sense of self (Cojan et al., 2009; Vuilleumier, 2005). The superior medial frontal hypometabolism in our case may correspond to this diaschisis, with impaired connectivity with the medial temporal lobe. Emotional-associated memory is known to be more involved in right hemisphere activation in functional imaging (Fink et al., 1996; Tulving, Kapur, Craik, Moscovitch, & Houle, 1994). Seventy-eight percent of cases in one series (Stone, Sharpe, Rothwell, & Warlow, 2003) had left sensorimotor conversion. The lateralized symptoms in our patient correspond to right hemisphere dysfunction (as shown on SPECT results) and possibly to an emotion-associated mnemonic trace participating in the conversion disorder. Functional imaging data suggest that neural circuits linking volition, movement and perception are disrupted in conversion disorder (Vuilleumier, 2005). The recovery of memory led to the reappearance of left lower limb symptoms in our patient, suggesting a possible interaction between memory, the limbic network, and the right sensorimotor system.

The fact that medial temporal lesions induce recovery from conversion symptoms does not mean that these structures are the cause of conversion. However, they may play a role in the pathophysiology of conversion. This clinical improvement of conversion may relate to an “inactivation of cerebral repression.” Resurgence of cerebral repression could be linear as amnesia improves. While not pathological in the MRI examination (no ischemia, no atrophy, no abnormal signal), the right thalamic and perirolandic hypoperfusion found in our SPECT examination may relate to this resurgent “cerebral repression phenomenon” involved in left sensitive-motor conversion.

Third, the diffuse cerebral stress may have “reset” the cerebral networks involved in behavior. The mechanisms of the morphine overdose associated with anoxic encephalopathy induced brain changes and neural plasticity during recovery from the brain injury. For example, the brain derived neurotrophic factor (BDNF), involved in the mechanisms of neural plasticity (Segi-Nishida, Warner-Schmidt, & Duman, 2008), is decreased in psychiatric diseases, inducing a decrease in hippocampal neurogenesis (Warner-Schmidt & Duman, 2006) and is transiently increased after ischemic lesions (such as the anoxic encephalopathy in our case) (Bejot et al., 2011). The change in the BDNF level may participate in the transiently improved behavior in our case. However, the resurgence of conversion symptoms suggests that this mechanism did not break the behavior disorder network.

A parallel between our case and the mechanisms of ECT may be drawn. ECT is frequently used in resistant psychiatric disorders that can induce brain changes, such as the mild brain injuries sometimes involved in recovery from psychiatric diseases. For example, glutamatergic system regulation is similarly modified by ECT and brain injury in a rat model (Dong et al., 2010; Hinzman, Thomas, Quintero, Gerhardt, & Lifshitz, 2012). As the physiopathology of ECT remains unclear, the amnesia in our observation may be compared with the temporary amnesia induced by ECT. Usually considered as a side effect, it may be involved in clinical improvement. Moreover, as with hypoxic encephalopathy, it probably induces neuroplasticity, especially in the hippocampus (Meeter, Murre, Janssen, Birkenhager, & van den Broek, 2011). The ECT it is not a first line treatment for conversion, but if our hypotheses are confirmed, it should be evaluated in very severe cases.

Further studies of the mechanisms of conversion and recovery are needed to confirm these hypotheses. Discovering which mechanisms are involved in conversion and its improvement is a major issue, as it will pave the way for a specific therapeutic strategy in the future.

In addition to psychotherapy methods that aim to induce cognitive reappraisal, some therapies could be evaluated in order to improve the neural plasticity or to modify the emotionally-associated knowledge of “self.” This “modified self-representation” could be a useful period in which psychological therapy can begin by working on a reappraisal of stressful events in life and everyday

difficulties. Some therapies, such as repetitive transcranial magnetic stimulation (Chastan, & Parain, 2010), ECT (Meeter et al., 2011), and hypnosis (Bell et al., 2011), could be evaluated to modify neural plasticity and “self-representation.” If our understanding of the molecular mechanisms involved in conversion confirms neural plasticity takes place, the role of potential pharmaceutical treatments inducing neural plasticity could also be evaluated.

Manuscript received 29 November 2011
Revised manuscript received 30 April 2012
First published online 29 August 2012

REFERENCES

- American Psychiatric Association. (1994). *Diagnostic and statistical manual of mental disorders. DSM-IV*. 4th ed. Washington, DC: American Psychiatric Association.
- American Psychiatric Association. (2000). *Diagnostic and statistical manual of mental disorders. DSM-IV-TR*. 4th ed. revised. Washington, DC: American Psychiatric Association.
- Bell, V., Oakley, D. A., Halligan, P. W., & Deeley, Q. (2011). Dissociation in hysteria and hypnosis: Evidence from cognitive neuroscience. *Journal of Neurology, Neurosurgery & Psychiatry*, 82, 332–339.
- Bejot, Y., Prigent-Tessier, A., Cachia, C., Giroud, M., Mossiat, C., Bertrand, N., Garnier, P., & Marie, C. (2011). Time-dependant contribution of non neuronal cells to BDNF production after ischemic stroke in rats. *Neurochemistry International*, 58, 102–111.
- Carson, A. J., Ringbauer, B., Stone, J., McKenzie, L., Warlow, C., & Sharpe M. (2000). Do medically unexplained symptoms matter? A prospective cohort study of 300 new referrals to neurology outpatient clinics. *Journal of Neurology, Neurosurgery & Psychiatry*, 68, 207–210.
- Chastan, N., & Parain, D. (2010). Psychogenic paralysis and recovery after motor cortex transcranial magnetic stimulation. *Movement Disorders*, 25, 1501–1504.
- Cojan, Y., Waber, L., Carruzzo, A., & Vuilleumier, P. (2009). Motor inhibition in hysterical conversion paralysis. *Neuroimage*, 47, 1026–1037.
- Dong, J., Min, S., Wei, K., Li, P., Cao, J., & Li, Y. (2010). Effects of electroconvulsive therapy and propofol on spatial memory and glutamatergic system in hippocampus of depressed rats. *Journal of ECT*, 26, 126–130.
- Ferreira, S., Vanholsbeeck, G., Chopard, G., Pitard, A., Tio, G., Vandel, P., Galmiche, J., & Rumbach, L. (2010). Comparative norms of RAPID neuropsychological battery tests for subjects aged between 50 and 89 years. *Revue Neurologique (Paris)*, 166, 606–614.
- Fink, G. R., Markowitsch, H. J., Reinkemeier, M., Bruckbauer, T., Kessler, J., & Heiss, W. D. (1996). Cerebral representation of one's own past: Neural networks involved in autobiographical memory. *Journal of Neuroscience*, 16, 4275–4282.
- Fraser, L. M., O'Carroll, R. E., & Ebmeier K. P. (2008). The effect of electroconvulsive therapy on autobiographical memory: A systematic review. *Journal of ECT*, 24, 10–17.
- Grubb, N. R., Fox, K. A., Smith, K., Best, J., Blane, A., Ebmeier, K. P., Glabus, M. F., & O'Carroll, R. E. (2000). Memory impairment in out-of-hospital cardiac arrest survivors is associated with global reduction in brain volume, not focal hippocampal injury. *Stroke*, 317, 1509–1514.
- Hinzman, J., Thomas, T. C., Quintero, J., Gerhard, G., & Lifshitz, J. (2012). Disruptions in the regulation of extracellular glutamate by neurons and glia in the rat striatum two days after diffuse brain injury. *Journal of Neurotrauma*, in press. doi:10.10189/neu.2011.2261
- Holemans, X., Dupuis, M., Misson, N., & Vanderijst, J. F. (2001). Reversible amnesia in a Type 1 diabetic patient and bilateral hippocampal lesions on magnetic resonance imaging (MRI). *Diabetic Medicine*, 18, 761–763.
- Kartsounis, L. D., Rudge, P., & Stevens, J. M. (1995). Bilateral lesions of CA1 and CA2 fields of the hippocampus are sufficient to cause a severe amnesic syndrome in humans. *Journal of Neurology, Neurosurgery & Psychiatry*, 59, 95–98.
- Margoon, M. A., & Andrade, C. (2010). Efficacy of ECT in chronic, severe, antidepressant- and CBT-refractory PTSD: An open, prospective study. *Brain Stimulation*, 3, 28–35.
- Meeter, M., Murre, J. M., Janssen, S. M., Birkenhager, T., & van den Broek, W. W. (2011). Retrograde amnesia after electroconvulsive therapy: A temporary effect? *Journal of Affective Disorders*, 132, 216–222.
- Segi-Nishida, E., Warner-Schmidt, J. L., & Duman, R. S. (2008). Electroconvulsive seizure and VEGF increase the proliferation of neural stem-like cells in rat hippocampus. *Proceedings of the National Academy of Sciences (USA)*, 105, 11352–11357.
- Sellal, F., Manning, L., Seegmuller, C., Scheiber, C., & Schoenfelder, F. (2002). Pure retrograde amnesia following a mild head trauma: A neuropsychological and metabolic study. *Cortex*, 3, 499–509.
- Stone, J., Sharpe, M., Rothwell, P. M., & Warlow, C. P. (2003). The 12 year prognosis of unilateral functional weakness and sensory disturbance. *Journal of Neurology, Neurosurgery & Psychiatry*, 74, 591–596.
- Tiihonen, J., Kuikka, J., Viinamäki, H., Lehtonen, J., & Partanen, J. (1995). Altered cerebral blood flow during hysterical paresthesia. *Biological Psychiatry*, 37, 134–135.
- Tulving, E., Kapur, S., Craik, F. I., Moscovitch, M., & Houle, S. (1994). Hemispheric encoding/retrieval asymmetry in episodic memory: Positron emission tomography findings. *Proceedings of the National Academy of Sciences (USA)*, 91, 2016–2020.

- Vuilleumier, P. (2005). Hysterical conversion and brain function. *Progress in Brain Research*, 150, 309–329.
- Vuilleumier, P., Chicherio, C., Assal, F., Schwartz, S., Slosman, D., & Landis, T. (2001). Functional neuroanatomical correlates of hysterical sensorimotor loss. *Brain*, 124, 1077–1090.
- Warner-Schmidt, J. L., & Duman, R. S. (2006). Hippocampal neurogenesis: Opposing effects of stress and antidepressant treatment. *Hippocampus*, 16, 239–249.
- Zola-Morgan, S., Squire, L. R., & Amaral, D. G. (1986). Human amnesia and the medial temporal region: Enduring memory impairment following a bilateral lesion limited to field CA1 of the hippocampus. *Journal of Neuroscience*, 6, 2950–2967.