

Published in final edited form as:

J Neurol Sci. 2012 December 15; 323(1-2): 245–247. doi:10.1016/j.jns.2012.07.059.

Varicella Zoster Virus Vasculopathy: A treatable form of rapidly progressive multi-infarct dementia after 2 years' duration

Brian Silver^a, Maria A. Nagel^b, Ravi Mahalingam^b, Randall Cohrs^b, D. Scott Schmid^c, and Don Gilden^{b,d,*}

^aDepartment of Neurology, Warren Alpert Medical School of Brown University, Providence, Rhode Island, USA

^bDepartment of Neurology, University of Colorado School of Medicine, Aurora, CO, USA

^cCenters for Disease Control and Prevention, Atlanta, GA, USA

^dDepartment of Microbiology, University of Colorado School of Medicine, Aurora, CO, USA

Abstract

We describe an extraordinarily protracted case of varicella zoster virus (VZV) multifocal vasculopathy in a man who presented initially with ischemic optic neuropathy and then suffered 4 episodes of stroke manifesting as multi-infarct dementia over a 2-year period. Brain magnetic resonance imaging (MRI) and angiography (MRA) revealed cortical and subcortical infarctions as well as vasculitic occlusion and stenosis. The patient was treated with corticosteroids and later with cyclophosphamide. More than 2 years after the onset of neurological disease, two cerebrospinal fluid (CSF) examinations revealed the presence of anti-VZV IgG antibody with reduced serum-to-CSF ratios of anti-VZV IgG compared with ratios for total IgG and albumin, indicative of intrathecal synthesis of anti-VZV IgG. After definitive diagnosis, immunosuppressive drugs were discontinued and he was treated with intravenous acyclovir; both mental status and gait improved and no further episodes of neurological dysfunction ensued. The favorable outcome in this patient indicates that VZV vasculopathy can be treated successfully even after 26 months. VZV must be considered as a possible cause of neurological disease in any patient with idiopathic multifocal vasculopathy.

Keywords

VZV vasculopathy; ischemic optic neuropathy; multi-infarct dementia

1. Introduction

Varicella zoster virus (VZV) is the only virus proven to cause transient ischemic attacks and stroke in humans. VZV vasculopathy results from productive viral infection in arteries, as

© 2012 Elsevier B.V. All rights reserved.

*Corresponding author: Dr. Don Gilden, 12700 E. 19th Avenue, Mail Stop B182, Aurora, CO 80045, USA. Tel.: 1-303-724-4326; fax: 1-303-724-4329, don.gilden@ucdenver.edu.

Conflict of interest statement

All authors report no conflicts of interest.

Publisher's Disclaimer: This is a PDF file of an unedited manuscript that has been accepted for publication. As a service to our customers we are providing this early version of the manuscript. The manuscript will undergo copyediting, typesetting, and review of the resulting proof before it is published in its final citable form. Please note that during the production process errors may be discovered which could affect the content, and all legal disclaimers that apply to the journal pertain.

evidenced by the presence of multinucleated giant cells, Cowdry A inclusion bodies, herpes virus particles, VZV antigen and VZV DNA in cerebral arteries [1]. Brain imaging and vascular studies have shown that disease more often involves both large and small arteries rather than only small or only large arteries, and involvement of small retinal arteries may produce ischemic optic neuropathy (ION) [2]. VZV vasculopathy is often waxing and waning, and disease is protracted. Two fatal cases lasted for 10 and 12 months, respectively [3,4], while another patient was diagnosed and successfully treated at 6 months [5]. Herein, we describe an extraordinary case of a man with virologically-verified VZV multifocal vasculopathy that began with ION followed by 4 episodes of stroke manifesting as multi-infarct dementia over a 2-year period. After definitive diagnosis and treatment with intravenous acyclovir, his mental status and gait improved, with no further episodes of neurological dysfunction. The favorable outcome in the most protracted case of VZV vasculopathy known to date indicates that even patients with disease lasting for 26 months can be treated successfully.

2. Case Report

In February 2010, a 69-year-old man with no history of zoster experienced upper altitudinal vision loss in the right eye lasting about 5 minutes. He had been taking aspirin 81 mg daily and atorvastatin 20 mg daily for hypercholesterolemia. Ophthalmological examination was normal. LDL cholesterol was 83 mg%, fasting blood glucose was 99 mg% and sedimentation rate was 2 mm/h. Brain MRI (Fig. A), head magnetic resonance angiography (MRA) (B), transthoracic echocardiogram and carotid duplex were negative. Two days later, he became blind in the right eye. Visual acuity was OS 20/25. OD was restricted to finger-counting at 3 feet and a crescent of preserved temporal visual field; there was a relative afferent pupillary defect; funduscopy revealed diffuse whitening and retinal edema with a cherry red spot, consistent with branch retinal artery occlusion. Neck MRA revealed 60% stenosis at the origin of the left vertebral artery. C-reactive protein was 13.10 mg/L. Lupus anticoagulant, cardiolipin antibodies, antithrombin III, factor V Leiden mutation and serum protein electrophoresis were normal. In October 2010, a second episode of neurological dysfunction was characterized by word-finding difficulties. Brain CT scan showed a recent infarction in the left corona radiata and basal ganglia and an older infarction in the right basal ganglia (C). Urine toxicology was negative. In September 2011, the patient developed intermittent dysarthria and short-term memory loss. Brain MRI revealed new areas of deep-seated ischemia in both thalami and in the periventricular white matter (D). Head MRA demonstrated new carotid occlusion distal to the left M1 segment (E). Carotid duplex was normal. He was started on clopidogrel 75 mg daily, aspirin was increased to 325 mg daily, and atorvastatin was increased to 40 mg daily. In October 2011, he developed ataxia, dizziness and expressive language difficulties. Brain MRI showed multiple new cortical and subcortical infarctions bilaterally (F) and a large infarction in the right superior cerebellum (not shown). The CSF contained 46 white blood cells, 94% mononuclear; CSF protein was 135 mg% and glucose was 82 mg%. CSF cultures for bacteria, fungi and acid-fast bacilli and cytology were negative. CSF VDRL was negative, and CSF did not contain cryptococcal antigen or antibody to coccidioides or rickettsia. CSF PCR for VZV, herpes simplex virus (HSV) and West Nile Virus was negative. Serum ANA, anti-PR3, anti-cardiolipin, ANCA, anti-B2 glycoprotein, acetylcholine receptor antibody, neuronal potassium channel antibody, paraneoplastic antibodies, striated muscle antibodies, Purkinje cell cytoplasmic antibodies and amphiphysin antibody, hepatitis B and C, cryoglobulins, SPEP, CH50, C-reactive protein, myeloperoxidase, Lyme antibody, rheumatoid factor, CPK, TSH, B12 and HIV were all unremarkable. Cerebral angiography showed multiple areas of narrowing and irregularity with post-stenotic dilatation, mostly at arterial bifurcations (G); the M1 branch of the left middle cerebral artery was stenotic and there was no flow in the M2 segment; there was 40% stenosis of the left vertebral artery; distal branches of the left

posterior cerebral artery were stenotic and the left middle cerebral artery was occluded (not shown). CT of the chest, abdomen, and pelvis revealed no malignancy. Echocardiography showed no evidence of cardiomyopathy or patent foramen ovale. A brain biopsy was normal. Although the only vascular tissue in the brain biopsy specimen was capillaries, PCR and immunohistochemistry were applied to the tissue to see if VZV DNA or viral antigen could be detected, and neither was found. After empirical treatment with solumedrol 250 mg every 8 hours for one week, he had no clinical change in expressive language or gait. Brain MRI 2 weeks after steroids were started revealed a new infarction in the left centrum semiovale (H). He was treated with cyclophosphamide, 900 mg in October and November, 2011, 950 mg in January 2012 and 1 g in March, 2012.

In January 2012, he was unable to identify any elements of date or location, perform serial subtraction, name any words beginning with F in 60 seconds, and could only name 3 animals in 60 seconds. His vision in the right eye allowed discernment of colors only laterally and superiorly, and he could not identify any letters. He was unable to perform tandem gait. Reflexes were diffusely brisk, more on the right.

A CSF sample in February 2012 was acellular and CSF protein was 154 mg%. A third CSF exam in March 2012 revealed anti-VZV IgG antibody, but not anti-HSV antibody, and the serum-to-CSF ratio of anti-VZV IgG antibody was markedly reduced (7) compared to ratios for total IgG (57) and albumin (33), indicative of intrathecal synthesis of anti-VZV IgG antibody. Cyclophosphamide was discontinued and prednisone was tapered. In April 2012, he was treated with intravenous acyclovir 10 mg/kg every 8 hours for 2 weeks followed by oral valacyclovir 1000 mg twice daily for 3 months.

In June 2012, the patient was oriented to month, year and place, and able to perform serial subtraction to the second digit, to identify 2 words beginning with F and 7 animals in 60 seconds, and to perform tandem gait without difficulty. A 4th CSF was examined and found to contain anti-VZV IgG antibody with a reduced serum-to-CSF ratio (6.5).

3. Discussion

In this extraordinary case of VZV multifocal vasculopathy, manifested initially as ION followed by 4 episodes of multi-infarct dementia over a 2-year period, both MRI and vascular imaging revealed cortical and subcortical infarctions as well as vasculitic occlusion, stenosis and post-stenotic dilatation of large and small arteries. One CSF sample contained a mononuclear pleocytosis and markedly elevated CSF protein, while a repeat CSF exam 4 months later revealed no cells, although CSF protein remained high. More than 2 years after the onset of neurological disease, virological diagnosis was confirmed by the detection of anti-VZV IgG antibody in CSF with reduced serum/CSF ratios of anti-VZV IgG compared with ratios of total IgG and albumin, indicative of intrathecal synthesis of anti-VZV IgG. After definitive diagnosis, immunosuppressive drugs were discontinued and intravenous acyclovir was administered, followed by improvement in mental status and gait and no further episodes of neurological dysfunction.

Several features of this case are noteworthy. First, disease evolved over 26 months, the longest time ever reported for VZV vasculopathy. To our knowledge, the most protracted cases of VZV vasculopathy evolved over 10 and 12 months, respectively [3,4], neither of which was diagnosed before death. The course of another patient with VZV vasculopathy evolved over a 6-month period, after which he was cured by treatment with intravenous acyclovir [5]. The successful outcome in the latter patient, as well as in our patient, indicate that even when VZV vasculopathy continues for 6 to 26 months, patients can be treated successfully.

A second important feature is the initial presentation of neurological disease in our patient as ION. Three cases of ION produced by VZV, all after ophthalmic-distribution zoster, have been reported [5,6,7]; importantly, in the latter case, there was intrathecal synthesis of anti-VZV IgG antibody as well as VZV antigen in the ipsilateral asymptomatic temporal artery. Most recently, intrathecal synthesis of anti-VZV IgG antibody and VZV antigen in the ipsilateral asymptomatic temporal artery was demonstrated in another patient with ION and no history of zoster rash as was the case in this patient (Nagel, M., personal communication). Even if disease in our patient had not progressed to VZV multi-infarct dementia, his initial episode manifesting as ION is worthy of emphasis since early diagnosis and treatment would likely have obviated his protracted illness.

A third notable feature in this case is that while the clinical course after the initial episode of ION appeared to be that of a multi-infarct dementia, the pace of repeated infarction was far more rapid than that usually seen in patients with subcortical arteriosclerotic encephalopathy. Furthermore, the CSF of patients with subcortical arteriosclerotic encephalopathy is acellular.

Two other virological features in this study are important. First, in VZV vasculopathy, productive virus infection is almost exclusively found in cerebral arteries and areas of brain infarction do not contain virus [3]. Thus the absence of VZV DNA and viral antigen in the brain biopsy specimen was expected, because the biopsy specimen was not even in an area of infarction.

Second, we again emphasize that either the detection of VZV DNA or anti-VZV IgG or IgM antibody in CSF or of anti-VZV IgM antibody in serum confirms the diagnosis of VZV vasculopathy. However, because VZV vasculopathy is protracted, the sensitivity of detection of anti-VZV IgG antibody in CSF is greater than the detection of VZV DNA in CSF to diagnose disease [2]. Even in herpes simplex virus encephalitis, PCR for HSV DNA is usually positive for only a week or less while anti-HSV antibody begins to appear afterwards. Finally, VZV must be considered as a possible cause of neurological disease in any patient with idiopathic vasculopathy.

Acknowledgments

This work was supported in part by Public Health Service grants AG006127 and AG032958 from the National Institutes of Health.

The findings and conclusions in this report are those of the authors and do not necessarily represent the view of the Centers for Disease Control and Prevention.

References

1. Gilden D, Cohrs RJ, Mahalingam R, Nagel MA. VZV vasculopathies: diverse clinical manifestations, laboratory features, pathogenesis and treatment. *Lancet Neurol*. 2009; 8:731–40. [PubMed: 19608099]
2. Nagel MA, Cohrs RJ, Mahalingam R, Wellish MC, Forghani F, Schille A, et al. The varicella zoster virus vasculopathies: clinical, CSF, imaging and virological features. *Neurology*. 2008; 70:853–60. [PubMed: 18332343]
3. Gilden DH, Kleinschmidt-DeMasters BK, Wellish M, Hedley-Whyte ET, Rentier B, Mahalingam R. Varicella zoster virus, a cause of waxing and waning vasculitis. *N Engl J Med case 5–1995 revisited*. *Neurology*. 1996; 47:1441–46. [PubMed: 8960724]
4. Case Records of the Massachusetts General Hospital. Weekly clinicopathological exercises. Case 36–1996. A 37-year-old man with AIDS, neurologic deterioration, and multiple hemorrhagic cerebral lesions. *N Engl J Med*. 1996; 335:1587–95. [PubMed: 8900094]

5. Gilden DG, Lipton HL, Wolf JS, Akenbrandt W, Smith JE, Mahalingam R, et al. Two patients with unusual forms of VZV vasculopathy. *N Engl J Med.* 2002; 347:1500–3. [PubMed: 12421892]
6. Hall S, Carlin L, Roach ES, McLean WT Jr. Herpes zoster and central retinal artery occlusion. *Ann Neurol.* 1983; 13:217–18. [PubMed: 6830188]
7. Salazar R, Russman AN, Nagel MA, Cohrs RJ, Mahalingam R, Schmid DS, et al. VZV ischemic optic neuropathy and subclinical temporal artery involvement. *Arch Neurol.* 2011; 68:517–20. [PubMed: 21482932]

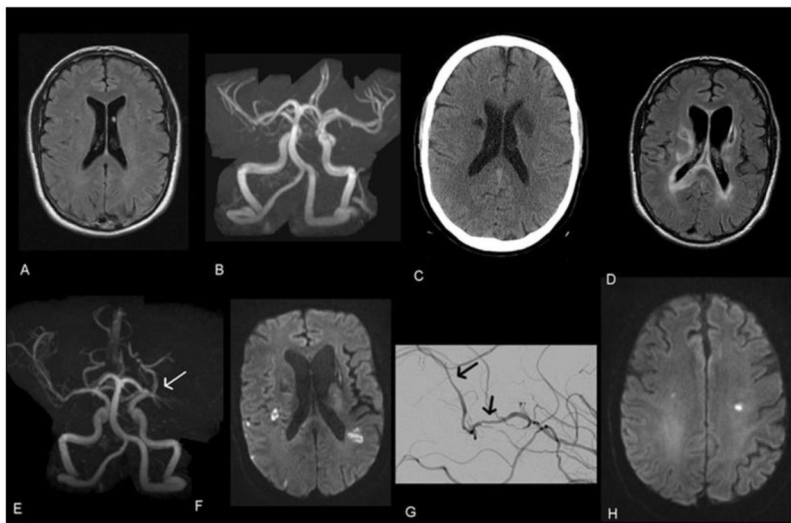


Fig. 1.

In February 2010, brain MRI (FLAIR sequence) (A) and brain MRA (B) were normal. In September 2010, head CT revealed subacute infarction in the left corona radiata and basal ganglia and an older infarction in the right basal ganglia (C). In September 2011, brain MRI (FLAIR sequence) showed new infarctions in both thalami and in periventricular white matter (D), and head MRA revealed a new occlusion of the left middle cerebral artery (E, arrow). In October 2011, brain MRI (DWI sequence) showed multiple acute infarctions bilaterally in subcortical white matter and in cortical regions of the right hemisphere (F), and a cerebral angiogram revealed multiple areas of vessel narrowing and dilation in distal branches of the right middle cerebral artery branches (G, arrows). In October 2011, while the patient was being treated with steroids, brain MRI showed a new infarction in the left corona radiata (H).