



Note

Pseudocortical and dissociate discriminative sensory dysfunction in a thalamic stroke

Francesca Notturmo^{a,b,*}, Rosamaria Sepe^c, Massimo Caulo^{a,c}, Antonino Uncini^{a,b} and Giorgia Committeri^{a,c}

^a Department of Neuroscience and Imaging, University "G. d'Annunzio" Chieti-Pescara, Italy

^b Neurocenter of Southern Switzerland (EOC), Lugano, Switzerland

^c ITAB: Institute for Advanced Biomedical Technologies (ITAB), Foundation "G. d'Annunzio", Chieti, Italy

ARTICLE INFO

Article history:

Received 7 June 2011

Reviewed 30 September 2011

Revised 6 December 2011

Accepted 20 July 2012

Action editor Yves Rossetti

Published online 14 August 2012

Keywords:

Thalamic stroke

Tactile agnosia

Pseudocortical dysfunction

ABSTRACT

In thalamic lesions a pseudocortical syndrome has been occasionally described but the effect of the lesion on the cortical network of tactile recognition has never been studied.

We report a patient who developed tactile agnosia in the left hand after right thalamic stroke, configuring a pseudocortical sensory syndrome. The discriminative sensory dysfunction was dissociate because only tactile agnosia and mild pseudoathetosis were present. A functional magnetic resonance imaging (fMRI) study showed that tactile recognition with the unaffected hand recruited a bilateral fronto-parietal network. During recognition with the left hand the activation was restricted and lateralized to the ipsilateral hemisphere.

In this patient with pseudocortical discriminative sensory dysfunction the lack of activation of the whole cortical network, implicated in tactile recognition, demonstrates that pseudocortical is functionally equivalent to cortical tactile agnosia.

© 2012 Elsevier Ltd. All rights reserved.

Tactile agnosia is defined as the inability to recognize an object by touch because of a selective impairment of textural cues processing (Wernicke, 1985). It is classified in apperceptive and associative (Wernicke, 1985). The former is characterized by the failure to discriminate texture, weight, roughness and shape, the latter by the inability in assigning a meaning to the object in presence of spared perceptual discrimination (Balsamo et al., 2008; Reed et al., 1996). Tactile agnosia is different from astereognosis which is, on the other hand, the failure in tactile recognition of spatial properties of the objects (Hömke et al., 2009).

After cortical lesions, epicritic sensibility (tactile recognition, graphesthesia, two points discrimination, position

sense) is compromised. The loss of only a few of epicritic sensory modalities configures a "dissociate discriminative sensory dysfunction" (Bassetti et al., 1993). After thalamic lesions, a protopathic sensibility (poorly localized sensibility to pain and temperature) is generally involved even if a "pseudocortical" syndrome, characterized by cortical clinical signs without cortical lesion, has been also described (Bassetti et al., 1993; Carrera and Bogousslavsky, 2006; Kim, 1992; Sacco et al., 1987).

We report a patient with tactile agnosia and thalamic stroke configuring a pseudocortical-dissociate discriminative sensory dysfunction. We tracked the thalamo-cortical somatosensory pathways by diffusion tensor imaging

* Corresponding author. Neurocenter of Southern Switzerland, Ospedale Civico, Via Tesserete 46, CH-6900 Lugano, Switzerland.

E-mail address: francnotturmo@yahoo.it (F. Notturmo).

0010-9452/\$ – see front matter © 2012 Elsevier Ltd. All rights reserved.

<http://dx.doi.org/10.1016/j.cortex.2012.07.002>

(DTI) and studied the subcortical lesion effect on tactile recognition network by functional magnetic resonance imaging (fMRI).

1. Case report

A 44-year-old, left-handed, man acutely developed difficulty in using the left arm. On admission the patient was alert and oriented, with normal speech, repetition, naming and comprehension (Token Test score: 36/36). He correctly recognized and named objects presented visually (Aachener Aphasia Test), was able to imitate meaningful or meaningless actions (Rumiati et al., 2005), draw simple and complex geometric objects, did not show short-term verbal and spatial deficits (Spinnler and Tognoni, 1987). There was no neglect or apraxia. Segmental strength was normal but there was mild left hand pseudoathetosis. Light touch, proprioception, vibratory sensation, two-point discrimination and graphesthesia were normal for both hands; there was no extinction to double stimulation in tactile, visual or auditory modalities. The patient presented marked difficulty to discriminate texture, weight, roughness and shape of the objects, to recognize the objects with left hand, to describe their use and name them. No errors were made with the right hand and through visual channel. Left upper quadrant anopsia and prosopagnosia were present.

FLAIR and TSE T2-weighted Magnetic Resonance (MR) sequences showed an ischemic lesion involving the anterior two thirds of right thalamus (Fig. 1A and B) and the ipsilateral temporo-occipital cortex in the right posterior cerebral artery territory. The ischemic lesion was secondary to a right posterior cerebral artery stenosis documented by MR angiography.

DTI were obtained using 15 diffusion gradient directions. Thalamo-cortical somatosensory pathways were tracked by manually seeding one Region Of Interest (ROI) in the thalamus and one in the centrum semiovalis below the primary somatosensory cortex of each hemisphere. DTI showed fibers reduction in right thalamo-cortical pathway (Fig. 1C).

Ninety fMRI images (echo-planar sequence, TR = 2.06 sec, TE = 35 msec, flip angle = 90°, 64 × 64 image matrix, 3.75 × 3.75 mm in-plane resolution, 33 slices, 3 mm slice thickness, no gap) were acquired using a 3T Philips Achieva in the AC–PC plane using blood-oxygenation-level-dependent imaging. A T1-weighted, whole-brain anatomical image, was acquired (3D-turbo-gradient-echo, 1 mm isotropic resolution). Images were analyzed using SPM8 (Wellcome Department of Cognitive Neurology, London, UK). Functional time series were temporally corrected for slice timing, spatially corrected for head movement, spatially normalized (final voxel size: 3 × 3 × 3 mm) and smoothed with a 6 mm FWHM Gaussian kernel.

An informed consent was obtained to perform the fMRI experiment, that was acquired during tactile recognition of 10 real objects and manipulation of foam rubber 3D non-sense objects (5 alternated 10-second trials of recognition and manipulation, two scans for each hand). Throughout the duration of the fMRI experiment the patient was monitored directly by the experimenters to ensure that he performed the

correct motor sequences, identical in both conditions (MANIPULATION and RECOGNITION). The patient was blindfolded, asked to remain quiet, concentrate in recognition with real objects and focus only on the motor sequence with non-sense objects. After the scan the patient was questioned whether he could identify the stimuli.

Statistical analysis was conducted on a voxel-by-voxel basis, according to the general linear model. Tactile manipulation of non-sense object was subtracted to real recognition (height threshold = $p < .01$ corrected for False Discovery Rate – FDR; extent threshold 10 voxels).

To identify regions related with specific tactile recognition and to exclude basic sensory-guided motor components fMRI activation patterns associated to the recognition task with the right (RecR) and the left (RecL) hands were compared to the manipulation task with the right (ManR) and the left (ManL) hands, respectively. RecR significantly activated premotor areas, bilateral superior and inferior frontal gyrus, right middle frontal gyrus, right anterior cingulum, left inferior parietal gyrus, left inferior temporal cortex and left insula. RecL activated only the sensorimotor cortex, the paracentral lobule and the inferior occipital gyrus of the left hemisphere (Fig. 1D).

2. Discussion

We report a patient with tactile apperceptive agnosia and an ischemic lesion in the right thalamus and occipito-temporal cortex.

Generally tactile agnosia is due to lesions in the post-central gyrus, in the secondary somatosensory area and posterior parietal cortex (Bassetti et al., 1993; Bohlhalter et al., 2002). On the other hand, all “cortical” syndromes maybe also mimicked by thalamic strokes. Albeit rarely, aphasia, amnesia, neglect and agnosia have been reported after a thalamic lesion (Carrera and Bogousslavsky, 2006). Even though thalamic lesions more frequently cause the loss of protopathic sensory modalities, few cases with selective impairment of epicritic sensory modalities have been described after thalamic stroke, probably because dorsal columns are strictly crossed whereas spinothalamic tracts project bilaterally (Kim and Choi-Kwon, 1996). Moreover spinothalamic fibers diffusely enter posterior thalamic, ventral posterolateral and central lateral nuclei whereas medial lemniscal fibers project specifically to caudal division of ventral posterolateral nucleus, therefore being more susceptible to lacunar stroke (Kim, 1992).

In the patient we describe, thalamic stroke could be responsible of tactile agnosia configuring a pseudocortical sensory dysfunction (Bassetti et al., 1993). Moreover this patient had a dissociate discriminative sensory dysfunction, with tactile agnosia and mild pseudoathetosis but undamaged position sense, graphesthesia, baresthesia and two points discrimination. The conservation of position sense in presence of pseudoathetosis might be due to the lack of sensitivity of the tests used for assessing it (Kim and Choi-Kwon, 1996) or might be explained by position sense fibers passing in the back of the thalamus that is spared by the ischemia.

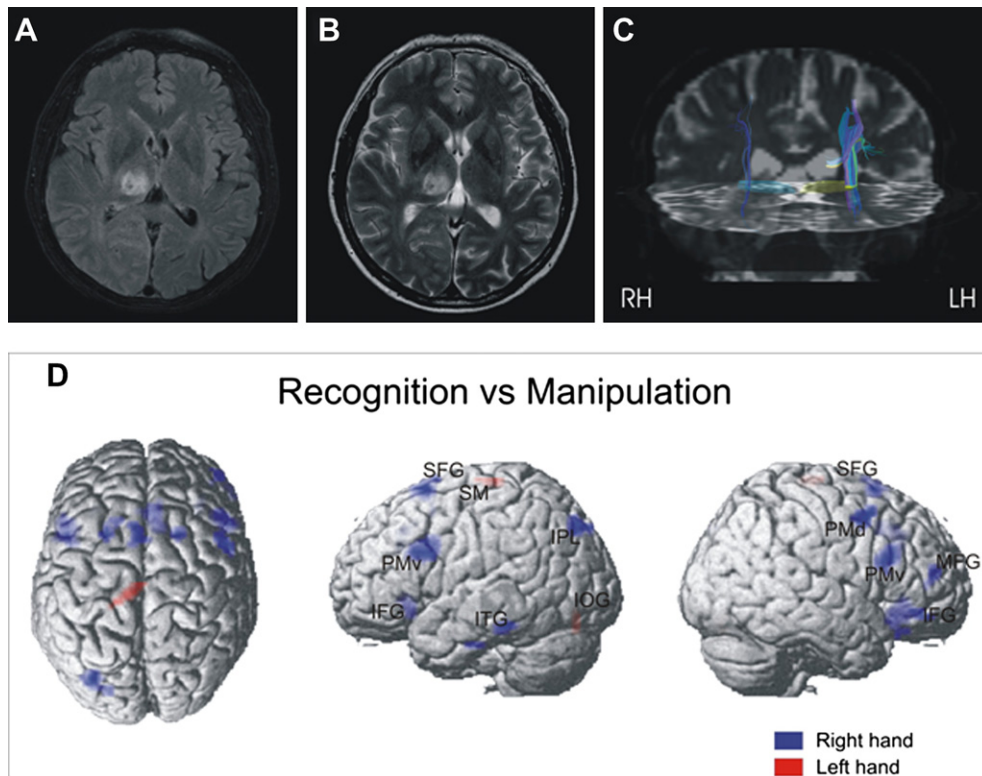


Fig. 1 – MR imaging, tractography and statistical parametric maps. Axial FLAIR (A) and TSE T2-weighted (B) sequences demonstrating the presence of right thalamus ischemic lesion. Diffusion tensor fiber tracking of the thalamo-cortical sensory pathways (C) demonstrates a reduction of fibers in the right hemisphere (images are displayed according to the radiological convention). Statistical parametric maps (D) showing areas with a significant ($p < .01$ corrected) effect of the recognition respect to the manipulation task. Blue patches represent right hand activation, red patches left hand activation. SFG, superior frontal gyrus; MFG, middle frontal gyrus; IFG, inferior frontal gyrus; PMv, ventral premotor cortex; PMd, dorsal premotor cortex; SM, sensorimotor cortex; IPL, inferior parietal lobule; ITG, inferior temporal gyrus; IOG, inferior occipital gyrus.

Previous fMRI studies on tactile object recognition found object exploration-related activity in a well defined parieto-premotor–temporal network (Binkofski et al., 1999; Reed et al., 2004; Roland et al., 1998; Stoeckel et al., 2003). Moreover, a recent meta-analysis (Lewis, 2006) showed that neural substrates for producing meaningful tools manipulations involve bilateral cortical networks with a clear left hemisphere bias. In accordance with this, the successful recognition with the right hand (RecR) recruited bilateral frontal premotor cortices and left parietal–temporal cortices, perfectly corresponding to cortical activation previously described in tactile recognition tasks (Stoeckel et al., 2003). By contrast during the poor recognition with the left hand (RecL) cortical fMRI activation was severely restricted to primary sensorimotor cortex and inferior occipital gyrus and lateralized in the ipsilateral hemisphere. We suggest that the pattern of cortical activation with the left hand could be the neuro-functional manifestation of tactile agnosia. In particular, a crucial role could be played by the lack of activation of areas related to coding of somatosensory object configuration (premotor cortex, anterior intraparietal sulcus) and areas associated to attention, object representation and encoding (prefrontal cortex, posterior intraparietal sulcus, middle

temporal gyrus), which are involved during a successful tactile recognition task (like during RecR) and during tools manipulation (Stoeckel et al., 2003; Lewis, 2006). However, we cannot completely rule out the possibility that the patient inside the MRI scanner moved less the left affected hand compared to the right. Therefore we mention also the possibility that a poorer movement with the affected hand might have contributed to the reduced activation during the manipulation task.

Haptic neuronal sensitivity has also been described in the lateral occipito-temporal cortex (Amedi et al., 2001; Costantini et al., 2011) probably reflecting a bimodal (visuo-haptic) representation of basic features and their spatial relationships, both of which are essential for identifying objects. This region is preferentially activated by visual objects but might represent also a bimodal convergence association zone of the two separate pathways involved in visual and somatosensory object processing (Amedi et al., 2001; Kourtzi and Kanwisher, 2000). The right occipito-temporal ischemic lesion in our patient is below the region reported by Amedi and colleagues, therefore we think that it can justify prosopagnosia, because of fusiform gyrus involvement, but not explain tactile agnosia. The fusiform gyrus has been recently reported to host

a trisensory (visual, auditory and tactile) representation of manipulable objects (Kassuba et al., 2011), but restricted to the left hemisphere. Our patient had a right-sided lesion and, moreover, cases of apperceptive tactile agnosia due to lateral or medial occipito-temporal lesions have never been reported to our knowledge. Further studies are needed to clarify the role of these regions in tactile recognition. In our case the successful recognition with the right hand indeed failed to activate them, whereas tactile recognition with the left impaired hand activated a left inferior occipital region nearby that described by Amedi et al. (2001), maybe reflecting a compensatory involvement of the visual system in internal object representation and topographic spatial processing of poor tactile recognition (Kosslyn et al., 1999).

In conclusion, in the patient we report with pseudocortical discriminative sensory dysfunction induced by thalamic lesion fMRI documented no activation of the cortical network involved in tactile recognition, demonstrating that pseudocortical is functionally equivalent to cortical tactile agnosia.

REFERENCES

- Amedi A, Malach R, Hendler T, Peled S, and Zohary E. Visuo-haptic object-related activation in the ventral visual pathway. *Nature Neuroscience*, 4(3): 324–330, 2001.
- Balsamo M, Trojano L, Giamundo A, and Grossi D. Left tactile agnosia after posterior callosal lesion. *Cortex*, 44(8): 1030–1036, 2008.
- Bassetti C, Bogousslavsky J, and Regli F. Sensory syndromes in parietal stroke. *Neurology*, 43(10): 1942–1949, 1993.
- Binkofski F, Buccino G, Posse S, Seitz RJ, Rizzolatti G, and Freund H-J. A fronto-parietal circuit for object manipulation in man. Evidence from a fMRI-study. *European Journal of Neuroscience*, 11(9): 3276–3286, 1999.
- Bohlhalter S, Fretz C, and Weder B. Hierarchical versus parallel processing in tactile object recognition: A behavioural–neuroanatomical study of apperceptive tactile agnosia. *Brain*, 125(Pt 11): 2537–2548, 2002.
- Carrera E and Bogousslavsky J. The thalamus and behavior: Effects of anatomically distinct strokes. *Neurology*, 66(12): 1817–1823, 2006.
- Costantini M, Urgesi C, Galati G, Romani GL, and Aglioti SM. Haptic perception and body representation in lateral and medial occipito-temporal cortices. *Neuropsychologia*, 49(5): 821–829, 2011.
- Hömke L, Amunts K, Binkofski F, Zilles K, and Weder B. Analysis of lesions in patients with unilateral tactile agnosia using cytoarchitectonic probabilistic maps. *Human Brain Mapping*, 30(5): 1444–1456, 2009.
- Kassuba T, Klinge C, Hölig C, Menz MM, Ptito M, Röder B, et al. The left fusiform gyrus hosts trisensory representations of manipulable objects. *NeuroImage*, 56(3): 1566–1577, 2011.
- Kim JS. Pure sensory stroke. Clinical–radiological correlates of 21 cases. *Stroke*, 23(7): 983–987, 1992.
- Kim JS and Choi-Kwon S. Discriminative sensory dysfunction after unilateral stroke. *Stroke*, 27(4): 677–682, 1996.
- Kosslyn SM, Pascual-Leone A, Felician O, Camposano S, Keenan JP, Thompson WL, et al. The role of area 17 in visual imagery: Convergent evidence from PET and rTMS. *Science*, 284(5411): 167–170. Erratum in: *Science*, 284 (5416): 197, 1999, 1999.
- Kourtzi Z and Kanwisher N. Cortical regions involved in perceiving object shape. *The Journal of Neuroscience*, 20(9): 3310–3318, 2000.
- Lewis WL. Cortical networks related to human use of tools. *Neuroscientist*, 12(3): 211–231, 2006.
- Reed CL, Caselli RJ, and Farah MJ. Tactile agnosia. Underlying impairment and implications for normal tactile object recognition. *Brain*, 119(Pt 3): 875–888, 1996.
- Reed CL, Shoham S, and Halgren E. Neural substrates of tactile object recognition: An fMRI study. *Human Brain Mapping*, 21(4): 236–246, 2004.
- Roland PE, O’Sullivan B, and Kawashima R. Shape and roughness activates different somatosensory areas in the human brain. *Proceedings of the National Academy of Sciences USA*, 95(6): 3295–3300, 1998.
- Rumiati RI, Weiss PH, Tessari A, Assmus A, Zilles K, Herzog H, et al. Common and differential neural mechanisms supporting imitation of meaningful and meaningless actions. *Journal of Cognitive Neuroscience*, 17(9): 1420–1431, 2005.
- Sacco RL, Bello JA, Traub R, and Brust JC. Selective proprioceptive loss from a thalamic lacunar stroke. *Stroke*, 18(6): 1160–1163, 1987.
- Spinnler H and Tognoni G. Standardizzazione e taratura italiana di test neuropsicologici. *Italian Journal of Neurological Sciences*, (Suppl. 8): 1–120, 1987.
- Stoeckel MC, Weder B, Binkofski F, Buccino G, Shah NJ, and Seitz RJ. A fronto-parietal circuit for tactile object discrimination: An event-related fMRI study. *NeuroImage*, 19(3): 1103–1114, 2003.
- Wernicke C. *Zwei faelle von rinden laesionen*. Arbeiten aus dem psychiatrische Klinik in Breslau. 33–53, 1985.