

Severe Envenomation by *Cerastes cerastes* Viper: An Unusual Mechanism of Acute Ischemic Stroke

Houssam Rebahi, MD, Hicham Nejmi, MD, Taoufik Abouelhasan, MD, Khadija Hasni, MD, and Mohamed-Abdenasser Samkaoui, MD

Cerebral complications after snake bites—particularly ischemic complications—are rare. Very few cases of cerebral infarction resulting from a viper bite have been reported, and we call attention to this uncommon etiology. We discuss 3 authenticated reports of acute ischemic cerebrovascular accidents after 3 typical severe envenomations by *Cerastes cerastes* vipers. The 3 patients developed extensive local swelling and life-threatening systemic envenomation characterized by disseminated intravascular coagulopathy, increased fibrinolysis, thrombocytopenia, microangiopathic hemolytic anemia, and acute renal failure. This clinical picture involved atypical neurologic manifestations. These patients had either low Glasgow Coma Scale (GCS) or hemiparesis within hours to 4 days after being bitten, and they were found to have computed tomographic evidence of single or multiple ischemic (nonhemorrhagic) strokes of small- to large-vessel territories of the brain. One patient had good clinical recovery without neurologic deficits. Thrombotic complications occurred an average of 36 hours after being bitten, and their importance depends on the degree of envenomation. The possible mechanisms for cerebral infarction in these cases include generalized prothrombotic action of the venom (consumptive coagulopathy), toxin-induced vasculitis, and endothelial damage. **Key Words:** *Cerastes cerastes*—ischemic stroke—snakebite—vasculitis.

© 2014 by National Stroke Association

Cerebral complications after snake bites—particularly ischemic complications—are rare. Reports of infarction are unusual and amount to only a few observations. For the most part, they involve multiple or massive cerebral lesions.

From the Department of Anesthesia and Intensive Care Medicine, Mohammed VI's University-Hospital of Marrakech, Cadi Ayyad University, Marrakech, Morocco.

Received April 9, 2010; revision received June 4, 2012; accepted July 8, 2012.

Address correspondence to Houssam Rebahi, MD, Ibn Tofail Hospital, Al Moustachfa Street, Gueliz, Marrakech 40000, Morocco. E-mail: r-houssam@hotmail.com.

1052-3057/\$ - see front matter

© 2014 by National Stroke Association

<http://dx.doi.org/10.1016/j.jstrokecerebrovasdis.2012.07.008>

Case 1

A 32-year-old previously healthy woman was bitten on her left hand by a horned viper in a paddy field. One day later, she developed generalized tonic-clonic seizures on her way to the local hospital (in the city of Ouarzazate) and was noted to be drowsy. She was then transferred to our emergency unit within 3 hours with a Glasgow Coma Scale (GCS) score of 12 and spontaneous bleeding from her gums. She had a normal pulse and blood pressure (120/70 mm Hg), and her electrocardiographic results were normal. Her GCS further reduced to 8, at which time she was electively intubated and ventilated because she could not protect her airway. Her dark port-wine-like colored urine was associated with oliguria. We noted a tight swollen hand in an intrinsic minus position (compartment syndrome of the hand). A computed

tomographic (CT) scan of the brain (Fig 1), carried out 2 days after the bite, revealed extensive infarction of the brain including frontal, temporal, and parietal lobes with cerebral edema. She had a normal blood cell count, a hemoglobin level of 13 g/L, with a hematocrit of 40% (normal 40-54%), 5000 cells/mm³ of leukocytosis, and 268,000 platelets/mm³ were observed. She also showed signs of disseminated intravascular coagulation (prothrombin 18.5% [normal 70-100%], activated cephalin time 50 seconds [normal 32 seconds]). Fasciotomy and supportive management of biologic and renal disorders were conducted. Her GCS did not improve, and she died.

Case 2

A 5-year-old girl without any particular pathologic antecedents was bitten by a *Cerastes cerastes* viper on her left leg 4 days before hospitalization; witnesses specified that the viper had 2 horns on its head. At admission, she was confused, polypneic (respiratory rate of 32 breaths per minute), her blood pressure was 100/70 mm Hg, and compartment syndrome was found in her lower limb. Initial laboratory findings revealed a prolonged prothrombin time, thrombocytopenia (35,000 platelets/mm³), acute anemia (5.4 g/dL), and 0.4 g/L of urea. She was intubated on admission because of her neurologic degradation and because her respiratory system was compromised. A CT scan of the brain conducted 4 days after the bite revealed right extensive frontal temporo-parieto-occipital ischemic stroke (Fig 2). In spite of the correction of her biologic disorders and fasciotomy, she underwent unfavorable neurologic evolution and died on day 7.

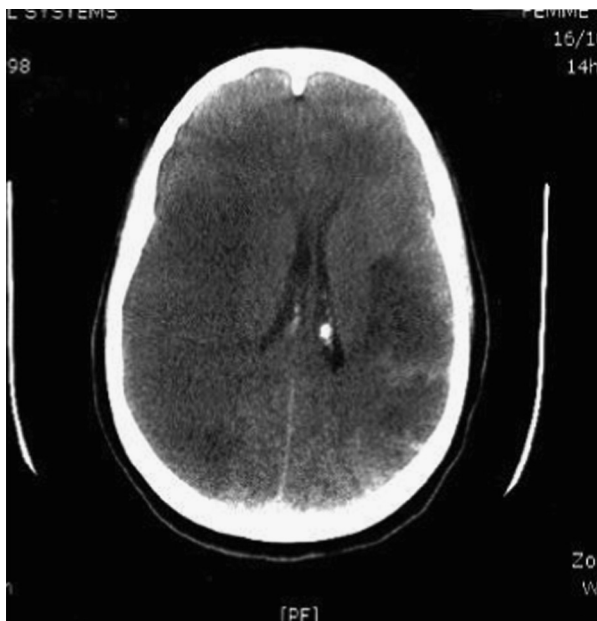


Figure 1. Computed tomographic scan of the brain of case 1 revealing an extensive infarction of the right cerebral hemisphere with important edema of the brain.

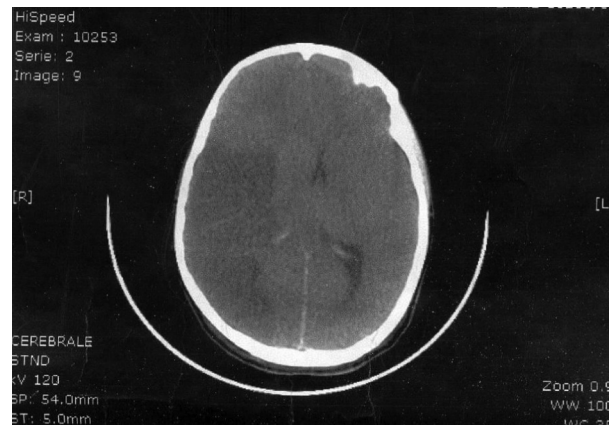

Figure 2. Computed tomographic scan of the brain of case 2 revealing right frontal temporo-parieto-occipital ischemic stroke.

Case 3

A 51-year-old previously healthy man was bitten on the right leg, and the snake was identified as a *C cerastes* viper by its distinctive supraorbital horns. The physical examination revealed initially impaired consciousness. The site of the bite was extremely painful. Marked swelling, local erythema, and generalized ecchymosis of the right leg were also observed. The patient presented with a diffuse edema extending to the root of the right limb, causing compartment syndrome. Breathing and urine output were normal. At admission, his pulse was 122 beats per minute and his blood pressure was 80/50 mm Hg. He was considered to be in a state of hemodynamic shock. Laboratory investigations at admission revealed: acute anemia (3.2 g/dL), mild leukocytosis, low prothrombin level (45%), prolonged activated cephalin time (50 sec), and the platelet count was $25 \times 10^3/\text{mm}^3$. Serum fibrinogen was 0.2 g/dL. The patient also presented with a biologic rhabdomyolysis with hyperkalemia (6 mmol/L), all without cardioelectrical repercussion. His serum creatinine peaked on day 2 and settled afterwards. Hepatic function was within the normal range. Our patient was subjected to electrocardiograms, 2-dimensional echocardiograms, and carotid duplex studies that were normal. The treatment consisted mainly of supportive therapy; he required a blood transfusion. Fresh frozen plasma and units of platelets were administered, and he also received vitamin K. Immunotherapy was not available. Fasciotomy was carried out. Within 48 hours of this surgical procedure, his neurologic status deteriorated and his GCS dropped to 10. At this point, a CT scan of the brain revealed acute bilateral cerebral infarctions in internal capsules (Fig 3). Our patient was intubated and later extubated on day 7. He was noted to have elevated blood pressure (150/90 mm Hg), and his coagulopathy receded gradually and returned to normal on discharge. He had a good clinical recovery, and his neurologic examination was normal at 3 months of follow-up.

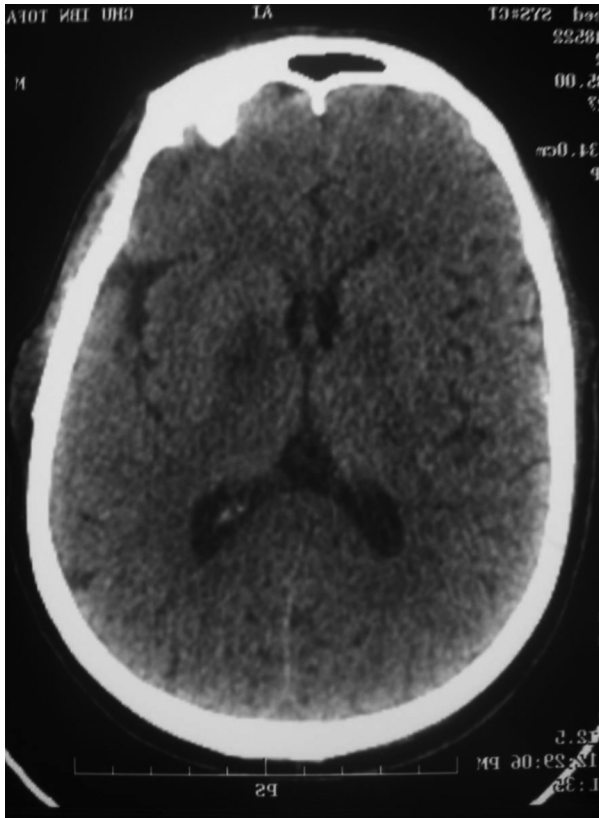


Figure 3. Bilateral cerebral infarctions located in the internal capsules (case 3).

Discussion

C cerastes is commonly known as the desert-horned or Egyptian sand viper.¹ *C cerastes* inhabits the sandy dunes of the western Negev, Sinai, and is also found in arid North Africa. It belongs to the family of Viperidae and the genus of *Cerastes*. Several cases of human envenomation by *C cerastes* have been reported.^{2,3} Apart from coagulation abnormalities, the clinical course is relatively benign.

Snake venoms of the Viperidae and Crotalidae families lead to disturbances of hemostasis because they contain a vast arsenal of hemotoxic toxins; envenomation by these snakes generally results in persistent bleeding. However, certain species of vipers possess neurotoxins in their venom capable of causing oculomotor paralysis and other neuromyopathies by their effects on neuromuscular junctions. Acute ischemic strokes after bites by snakes of the Viperidae family are more rare than those caused by the Crotalidae family.⁴⁻⁶

The putative mechanism causing the thrombotic process and cerebral infarcts remains complex and unknown. They occur an average of 36 hours after being bitten (range 7 hours to 4 days), and their proportion increases with the degree of envenomation.⁶ In large doses, it can cause massive disseminated intravascular coagulopathy with vessel occlusions resulting in cerebral infarction. Procoagulant activity of the venom (such as cerastocytin,

which is a thrombin-like serine protease with potent platelet-aggregating property purified from *C cerastes* venom⁷), vascular damage, and hyperviscosity secondary to circulatory shock may also contribute to cerebral infarcts.

Several authors have noted that the gradual disturbance of the hematologic picture of the envenomized patients suggests that this relatively late complication might also have been the result of a toxic vasculitis associated with the thrombotic process.^{8,9} In patients who have been bitten by members of the Viperidae family, vascular endothelial damage is usually caused by venom hemorrhagins or metalloproteinases.¹⁰⁻¹²

The most significant histopathologic finding in literature was the association of the infarctions with unusual and multifocal diffuse thrombotic microangiopathy involving small arteries and arterioles of noble organs. However, the occlusion of small blood vessels and, rarely, even of single major arteries has been described in fatal envenomations by Viperidae.¹³⁻¹⁵

Thomas et al⁶ also reported that no thrombotic complications were observed in 70 patients who received antivenom treatment within 6 hours of being bitten.

In conclusion, these uncommon cerebrovascular accidents in our patients were most likely due to generalized prothrombotic action of the venom and to toxin-induced vasculitis rather than the existence of an underlying prothrombotic tendency. The timing of the stroke in relation to the bite would add additional insight to the cause of the phenomenon. Envenomation in humans must await detailed studies of the venom. It is possible that these studies may improve our understanding of the pathogenesis of other vasculopathies and may help in the identification of potential victims of neurologic complications, ultimately leading to more effective treatment of these bites.

References

1. Soslau G, El-Asmar MF, Parker J. *Cerastes cerastes* (Egyptian sand viper) venom induced platelet aggregation as compared to other agonist. *Biochem Biophys Res Commun* 1988;150:909-916.
2. Zimmerman J, Mann G, Kaplan HY, et al. Envenoming by *Cerastes vipera*: A report of two cases. *Trans R Soc Trop Med Hyg* 1977;75:702-705.
3. Ben-Baruch N, Porath A, Kleiner-Baumgarten A, et al. *Cerastes vipera* envenoming—A report of seven cases. *Trans R Soc Trop Med Hyg* 1986;80:664.
4. Merle H, Donnio A, Ayeboua L, et al. Occipital infarction revealed by quadrantanopsia following snakebite by *Bothrops lanceolatus*. *Am J Trop Med Hyg* 2005;73:583-585.
5. Thomas L, Chausson N, Uzan J, et al. Thrombotic stroke following snake bites by the "Fer-de-Lance" *Bothrops lanceolatus* in Martinique despite antivenom treatment: A report of three recent cases. *Toxicon* 2006;48:23-28.
6. Thomas L, Tyburn B, Ketterlé J, et al. Prognostic significance of clinical grading of patients envenomed by

- Bothrops lanceolatus* in Martinique. Trans R Soc Trop Med Hyg 1998;92:542-545.
7. Marrakchi N, Barbouche R, Guermazi S, et al. Procoagulant and platelet-aggregating properties of cerastocytin from *Cerastes cerastes* venom. Toxicon 1997;35:261-272.
 8. Panicker JN, Madhusudanan S. Cerebral infarction in a young male following viper envenomation. J Assoc Physicians India 2000;48:744-745.
 9. Lee BC, Hwang SH, Bae JC, et al. Brainstem infarction following Korean viper bite. Neurology 2001;56:1244-1245.
 10. Moura-da-Silva AM, Butera D, Tanjomi I. Importance of snake venom metalloproteinases in cell biology: Effects on platelets, inflammatory and endothelial cells. Curr Pharm Des 2007;13:2893-2905.
 11. Serrano SM, Wang D, Shannon JD, et al. Interaction of the cysteine-rich domain of snake venom metalloproteinases with the A1 domain of von Willebrand factor promotes site-specific proteolysis of von Willebrand factor and inhibition of von Willebrand factor-mediated platelet aggregation. FEBS J 2007;274:3611-3621.
 12. Gomes MS, Mendes MM, de Oliveira F, et al. BthMP: A new weakly hemorrhagic metalloproteinase from *Bothrops moojeni* snake venom. Toxicon 2009;53:24-32.
 13. Ameratunga B. Middle cerebral occlusion following Russel's viper bite. J Trop Med Hyg 1972;75:95-97.
 14. Bush SP. Fatal and horrific rattlesnake bites. Presented at Venom Week 2007, Tucson, AZ, September 3-7, 2007.
 15. Mosquera A, Idrovo LA, Tafur A, et al. Stroke following *Bothrops* spp. snakebite. Neurology 2003;60:1577-1580.