

Striatal infarct with paroxysmal nonkinesigenic dyskinesia

Mine Hayriye Sorgun · M. Cenk Akbostancı ·
Canan Yücesan · Seyda Erdoğan · Nermin Mutluer

Received: 29 April 2012 / Accepted: 20 August 2012 / Published online: 14 September 2012
© Belgian Neurological Society 2012

Paroxysmal nonkinesigenic dyskinesia (PNKD) is a rare disorder characterized by episodic hyperkinetic movement attacks of any combination of dystonia, chorea, athetosis, and ballismus. Attacks may be triggered by emotional stress, fatigue or consumption of alcohol and caffeine. PNKD is usually inherited as an autosomal dominant trait [1].

The most common cause of secondary PNKD is multiple sclerosis [1]. However, PNKD has been reported in encephalitis, endocrine dysfunction (hypoglycemia, thyrotoxicosis, hypoparathyroidism), inherited bipterin synthesis defect, head injury, primer antiphospholipid syndrome, and HIV [1]. Symptomatic PNKD has rarely been

reported to be caused by thalamic or subcortical lacunar infarcts [2, 3].

In this letter, we describe a 45-year-old woman with short-lasting hemidystonia attacks in left side which commenced 3 weeks ago in 2009 (video). The characteristic of onset was abrupt. The episodes occurred 5–50 times per day, lasted from 10 to 30 s, and they rarely occur during sleep, and never precipitated by any factor. There were no other signs or symptoms. Our diagnosis was PNKD. Interictal EEG was normal, which helped us excluding an epileptic seizure. Neuroimaging studies showed a subacute infarct in the right nuclei lentiformis and caudatus (Fig. 1). Factor V Leiden mutation detected in the patient was accepted to be the cause of infarct and attacks have completely disappeared by carbamazepine (800 mg/day).

Symptomatic PNKD is rare and is reported in association with vascular lesions. In 1974, Lee et al. [2] described a PNKD with thalamic ischemia. Norlinah and Shahizon reported two patients with subcortical white matter ischemia. One of them presented with paroxysmal kinesigenic dyskinesia and the other was PNKD [3].

Alemdar et al. reported a PNKD with hypoparathyroidism. Neuroimaging studies showed calcifications in the basal ganglia, thalamus, brain stem, subcortical and cerebellar regions [4]. Basal ganglia and striatal lesions had been reported with PNKD [5]. Lesions in basal ganglia were similar to the neuroimaging findings of our case.

Although PNKD was reported to be associated with transient ischemic attacks, thalamic or subcortical lacunar infarcts, the presented patient were associated with an infarct of striatum [1–3]. We could rarely find similar reported relationship in our literature survey. Moreover, it has rarely been reported to be caused by lacunar infarcts.

Electronic supplementary material The online version of this article (doi:10.1007/s13760-012-0129-7) contains supplementary material, which is available to authorized users.

M. H. Sorgun (✉) · M. C. Akbostancı · C. Yücesan ·
S. Erdoğan · N. Mutluer
Department of Neurology, Ankara University School
of Medicine, İbni Sina Hospital, Samanpazarı, Ankara, Turkey
e-mail: drmsorgun79@yahoo.com.tr

M. C. Akbostancı
e-mail: cenk.akbostanci@medicine.ankara.edu.tr

C. Yücesan
e-mail: cyucesan@yahoo.com

S. Erdoğan
e-mail: dr-seyda@yahoo.com

N. Mutluer
e-mail: nmutluer@yahoo.com

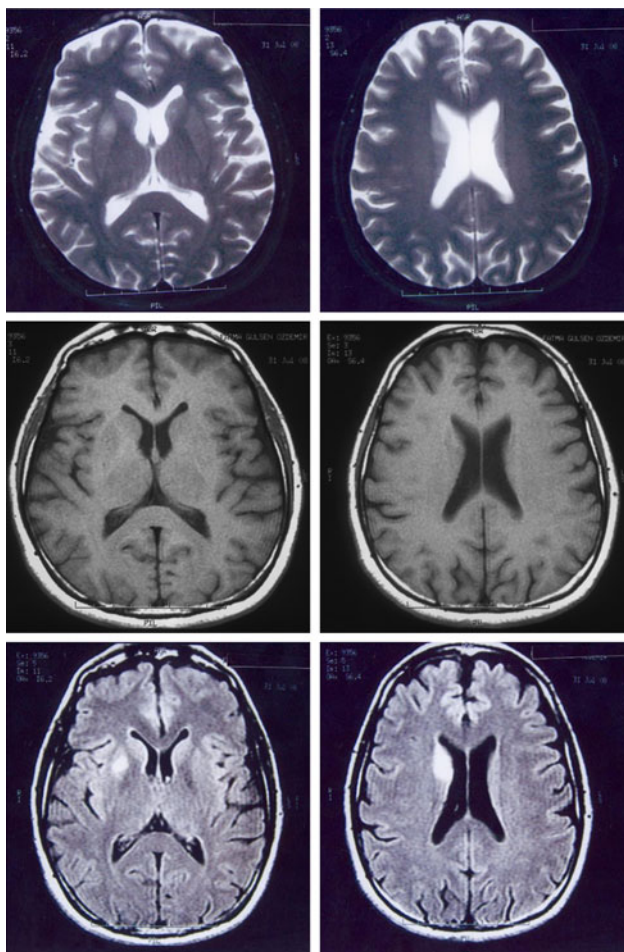


Fig. 1 Infarct in the right nuclei lentiformis and caudatus in T2, T1 weighted and FLAIR sequences of MRI

Conflict of interest None.

References

1. Fahn S, Jankovic J (2007) Principles and practice of movement disorders. Churchill Livingstone/Elsevier, Philadelphia, pp 553–575
2. Lee MS, Marsden CD (1994) Movement disorders following lesions of the thalamus or subthalamic region. *Mov Disord* 9:493–507
3. Norlinah MI, Shahizon AM (2008) Paroxysmal dyskinesia as an unusual and only presentation of subcortical white matter ischaemia: a report of two cases. *Med J Malaysia* 63(5):410–412
4. Alemdar M, Iseri P, Selekler M, Komşuoğlu SS (2007) Levetiracetam-responding paroxysmal nonkinesigenic dyskinesia. *Clin Neuropharmacol* 30(4):241–244
5. Blakeley J, Jankovic J (2002) Secondary paroxysmal dyskinesias. *Mov Disord* 17(4):726–734