

# **Bilateral Supratentorial Epidural Hematomas: a Rare Complication in Adolescent Spine Surgery**

## **—Case Report—**

Zhao-Jian LI,<sup>1</sup> Peng SUN,<sup>1</sup> Yi-He DOU,<sup>1</sup> Xiao-Lei LAN,<sup>1</sup>  
Jian XU,<sup>1</sup> Chun-Yong ZHANG,<sup>2</sup> and Jian-Peng WANG<sup>1</sup>

<sup>1</sup>Department of Neurosurgery, the Affiliated Hospital of Medical College,  
Qingdao University, Qingdao, Shandong Province, China;

<sup>2</sup>Department of Neurosurgery, the 8<sup>th</sup> People's Hospital of Qingdao City,  
Qingdao, Shandong Province, China

### **Abstract**

A 14-year-old girl presented with a rare case of spontaneous bilateral supratentorial epidural hematomas which developed rapidly following cervical surgery. The hematomas presumably resulted from dural dynamics changes secondary to cerebrospinal fluid loss and intracranial hypotension. Intracranial epidural hemorrhage after spinal surgery is extremely uncommon with only one previous case report. Spontaneous intracranial epidural hematoma is an extremely rare complication, but should be considered as a possible complication of spine surgery, especially in adolescents complicated by delayed consciousness and breathing restoration from anesthesia. This case report expands the presently known clinical spectrum of this uncommon complication.

Key words: cerebrospinal fluid loss, intracranial epidural hematoma, intracranial hypotension, spine surgery, adolescent

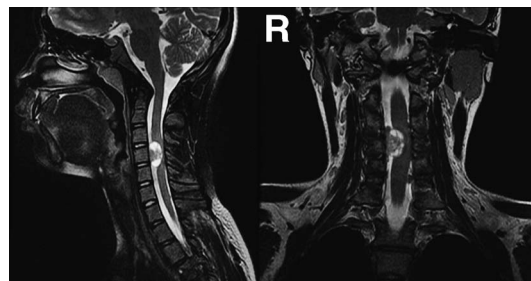
### **Introduction**

Intracranial epidural hematoma generally occurs following head trauma or cranial surgery. In contrast, spontaneous intracranial epidural hematoma has been infrequently reported in association with cranial decompression,<sup>10)</sup> coagulopathy,<sup>13)</sup> sphenoid sinusitis,<sup>12)</sup> ruptured middle meningeal artery pseudoaneurysm,<sup>4)</sup> or cranial metastasis.<sup>6)</sup> However, spontaneous intracranial epidural hematoma as a complication of spine surgery is extremely unusual, with only one such case described in an adolescent,<sup>11)</sup> who underwent resection of a thoracic spine lesion and developed acute supratentorial epidural hematoma postoperatively. Here we describe the occurrence of supratentorial bilateral epidural hematomas after cervical schwannoma surgery in a teenager, analyze the pathogenesis in detail, and emphasize early identification and treatment of this hazardous complication to avoid or minimize permanent neurological injury.

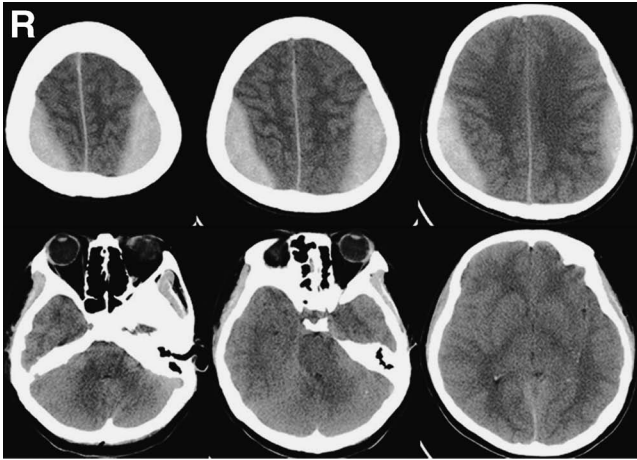
### **Case Report**

A 14-year-old girl was referred for neurosurgical evaluation with a complaint of 3-month chest and back pain on the right radiating to the ipsilateral shoulder. No remarkable medical history was noted, no anticoagulant agents had been administered, and no bleeding tendency was

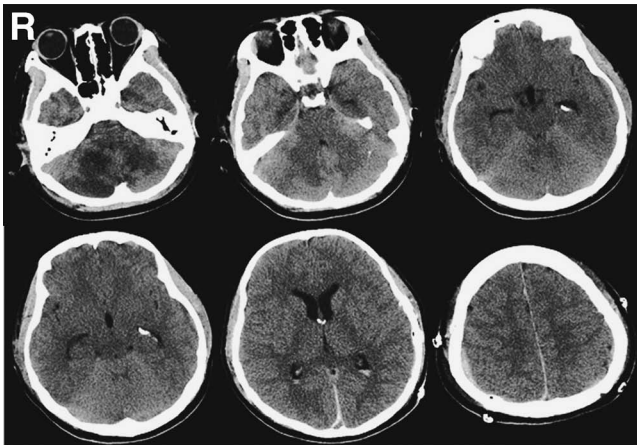
clinically observed. Laboratory results including platelet count, prothrombin time, and partial thromboplastin time found no abnormalities. Initial magnetic resonance imaging showed a  $1.5 \times 1.5 \times 1.8$  cm intradural space-occupying lesion with degenerative cyst at the C4 level, which had clearly compressed and displaced the cervical spinal cord (Fig. 1). Lesion resection was performed via a posterior cervical midline approach in the prone position without rigid pin fixation of the head. After cerebrospinal fluid (CSF) release for local decompression, the tumor was identified within the arachnoid layer, and adherent laterally and anteriorly to the dorsal nerve roots of C3 and C4, and was totally removed in a piecemeal manner. The oper-



**Fig. 1** T<sub>2</sub>-weighted magnetic resonance images revealing an intradural well-circumscribed mass displacing the cervical spinal cord dorsally and laterally at the C4 segment.



**Fig. 2** Emergent brain computed tomography scans disclosing symmetric epidural hematomas with a total volume of 80 ml and brain herniation with disappearance of the ventricles and cisterns.



**Fig. 3** Postoperative brain computed tomography scans showing multiple cerebellar hypodensity areas, extensive decreased density in the white matter and cerebral cortex, and cerebral atrophy.

ation was completed uneventfully, the dura was repaired, and epidural drainage with normal pressure was located 10 cm under the incision. During the whole operation, systolic blood pressure was well controlled and never exceeded 140 mmHg, CSF loss was about 100 ml, blood loss was only 300 ml, and no blood infusion was required. The tumor pathology was consistent with schwannoma.

The light reflex of the pupils was normal at the time of leaving the operation room. Two hours following surgery, delayed emergence from general anesthesia and bilateral dilated pupils with positive Babinski reflex were noted, and the amount of CSF drainage was 60 ml. Emergent computed tomography (CT) revealed bilateral parietal epidural hematomas with obliteration of the cerebral ventricles and cisterns (Fig. 2), and the drainage was closed immediately and extubated. Her postoperative blood clot-

ting and platelet parameters were reexamined and found to be normal. Bilateral craniotomies was then performed for removal of the hematomas, and scattered small blood oozes along the branches of the middle meningeal artery on the outer surface of dura mater were found without evident fracture, middle meningeal artery injury, or pseudoaneurysm, and were easily controlled by gelatin sponge compression or mild electric coagulation hemostasis. The patient regained spontaneous breathing at 6 hours and complete consciousness at 82 hours following hematoma removal. After final cessation of 85-hour mechanical ventilation, repeat CT demonstrated bilateral cerebellar infarctions and supratentorial hypoxic encephalopathy (Fig. 3). Hyperbaric oxygen therapy was then performed at 2.5 atmospheres absolute twice daily for 2 weeks. The 6-month follow-up examination found her upper limb hemiparesis had resolved leaving severe residual gait ataxia and amnesic disorder.

## Discussion

Three distinct forms of hemorrhage associated with spinal surgery have been classified according to bleeding location: supratentorial subdural hematoma,<sup>2,3)</sup> cerebellar hematoma,<sup>5,7)</sup> and supratentorial epidural hematoma.<sup>11)</sup> Intracranial epidural hematoma is most uncommon with only one case report.<sup>11)</sup> Similar to our case, a 15-year-old girl developed bilateral acute supratentorial epidural hematomas after spinal metastasis resection via a T4-T5 laminotomy.<sup>11)</sup> Both cases share several common traits: young age, simultaneously bilateral convex hematomas with acute progression, delayed emergence from surgical anesthesia, and durotomy performed during surgery.

The common etiology of postoperative intracranial epidural hematomas may involve use of anticoagulants, blood clotting dysfunction, incomplete hemostasis of the dura mater or diploe, poorly controlled high arterial blood pressure, and the misuse of rigid pins for head fixation. However, all these hemorrhagic risk factors can be ruled out in both cases. Due to the extremely low frequency of occurrence, there is still no satisfactory explanation for the mechanism of this unpredictable complication, but presumably large CSF loss during surgery may be important in the pathogenesis of such hemorrhage.<sup>11)</sup> In the present case, CSF release following durotomy and postoperative epidural drainage may have contributed to CSF depletion. CSF hypovolemia reduced intracranial buoyant support and displaced the whole brain caudally, resulting in secondary intracranial hypotension or even negative pressure. However, decreased intracranial pressure may just be the essential factor for epidural hematoma formation rather than a sufficient factor since intracranial epidural hematoma has never been reported in patients with spontaneous intracranial hypotension syndrome.

Both patients were aged 14 or 15 years, and epidural hematoma following spine surgery has an evident predilection for adolescents. Cranium growth is more active in children than in adults, and the adhesion between the dura mater and the internal table of the cranial vault

bones is less tight than in adults or the elderly.<sup>8)</sup> Therefore, teenagers are more liable to suffer mechanical separation of the dura from the cranium. Further, the separating forces might come from two different origins. Firstly, acute vascular caliber enlargement in the middle meningeal artery and vein, secondary to CSF loss and decreased intracranial pressure, may generate a dissecting force to loosen the dura-cranium adhesion by constantly fluctuating dilation. Based on the Monro-Kellie hypothesis, which states that the sum of the volumes of intracranial blood, CSF, and brain tissue must remain constant in an intact cranium, dural vascular engorgement and vasodilation has been confirmed to compensate for reduced CSF volume in patients with spontaneous intracranial hypotension.<sup>8)</sup> Secondly, negative intracranial pressure has been identified in CSF leakage patients,<sup>1,9)</sup> so rapid and large CSF loss could result in negative intracranial pressure and produce inner suction, which will facilitate dura separation from the internal table of the cranium. Therefore, we speculate that multiple factors contribute to the formation of intracranial epidural hematoma following spine surgery, but rapid CSF depletion is an important precondition or initiating agent, which induces two categories of dura-separating forces and ultimately results in dura splitting-hemorrhage collection and enlargement. In contrast, cerebellar or subdural hemorrhage related to spine surgery is of venous origin, and results from stretching of supratentorial bridge veins or cerebellar superior veins that cross the subdural space.<sup>2,3,5,7)</sup> Compared with adolescents, the elderly or adults have larger subdural spaces, and so these veins are more vulnerable to stretching injury by intracranial hypotension in the elderly or adults than in adolescents.<sup>2,3,5,7)</sup> Therefore, cerebellar or subdural hemorrhage mainly occurs in old or adult patients with no predilection for adolescents.

Bilateral intracranial epidural hematomas following spine surgery is a life-threatening complication, which can rapidly cause central brain herniation and subsequent cerebellar tonsillar herniation (Fig. 2). Early detection and correct management could result in full recovery as in the previous case.<sup>11)</sup> However, delayed hematoma removal will cause irreversible brain ischemic injury or even brain death. In our case, repeat CT revealed cerebellar infarction involving the territory of the bilateral posterior inferior cerebellar arteries (PICAs) and cerebrum anoxic encephalopathy in spite of the short 2-hour interval between spine surgery and craniotomy (Fig. 2). The cerebellar infarction in our case may have resulted from tonsillar herniation that stretched the hemispheric branches of the bilateral PICAs down to the edge of the foramen magnum, and the branches were directly compressed by the herniated tissue. Therefore, postoperative vigilance and early management are the most important factors for avoiding adverse outcomes. On the other hand, avoiding unnecessary CSF loss via minimally invasive spine surgery may be an effective procedure to decrease the incidence of such complications if intracranial hypotension by excessive CSF depletion is the cause.

Spontaneous intracranial epidural hematoma is an extremely rare condition, but should be considered a possi-

ble complication of spine surgery, especially in adolescents complicated by delayed consciousness and breathing restoration from general anesthesia.

## Acknowledgments

This work was funded by the National Natural Science Foundation of China (No. 11004114) and the Natural Science Foundation of Shandong Province (No. Z2008C06).

## Conflict of Interest Notification

There is no potential conflict for this study.

## References

- 1) Babl FE, Arnett AM, Barnett E, Brancato JC, Kharasch SJ, Janecka IP: Atraumatic pneumocephalus: a case report and review of the literature. *Pediatr Emerg Care* 15: 106–109, 1999
- 2) Beier AD, Soo TM, Claybrooks R: Subdural hematoma after microdiscectomy: a case report and review of the literature. *Spine J* 9: e9–e12, 2009
- 3) Burkhard PR, Duff JM: Bilateral subdural hematomas following routine lumbar discectomy. *Headache* 40: 480–482, 2000
- 4) de Andrade AF, Figueiredo EG, Caldas JG, Paiva WS, De Amorim RL, Puglia P: Intracranial vascular lesions associated with small epidural hematomas. *Neurosurgery* 62: 416–420, 2008
- 5) Enel D, Blamoutier A, Bacon P, Gentili ME: Spine surgery associated with fatal cerebellar haemorrhage. *Eur J Anaesthesiol* 26: 891–892, 2009
- 6) Hassan MF, Dhamija B, Palmer JD, Hilton D, Adams W: Spontaneous cranial extradural hematoma: a case report and review of literature. *Neuropathology* 29: 480–484, 2009
- 7) Morofuji Y, Tsunoda K, Takeshita T, Hayashi K, Kitagawa N, Suyama K: Remote cerebellar hemorrhage following thoracic spinal surgery. *Neurol Med Chir (Tokyo)* 49: 117–119, 2009
- 8) Paldino M, Mogilner AY, Tenner MS: Intracranial hypotension syndrome: a comprehensive review. *Neurosurg Focus* 15(6): ECP2, 2003
- 9) Schoffer KL, Benstead TJ, Grant I: Spontaneous intracranial hypotension in the absence of magnetic resonance imaging abnormalities. *Can J Neurol Sci* 29: 253–257, 2002
- 10) Stiver SI: Complications of decompressive craniectomy for traumatic brain injury. *Neurosurg Focus* 26(6): E7, 2009
- 11) Surash S, Bhargava D, Tyagi A: Bilateral extradural hematoma formation following excision of a thoracic intradural lesion. *J Neurosurg Pediatr* 3: 137–140, 2009
- 12) Takahashi Y, Hashimoto N, Hino A: Spontaneous epidural hematoma secondary to sphenoid sinusitis—case report. *Neurol Med Chir (Tokyo)* 50: 399–401, 2010
- 13) Zheng FX, Chao Y: Spontaneous intracranial extradural hematoma: case report and literature review. *Neurol India* 57: 324–326, 2009

---

Address reprint requests to: Zhaojian Li, MD, Department of Neurosurgery, the Affiliated Hospital of Medical College, Qingdao University, Qingdao, Shandong Province 266003, China.  
e-mail: lzj0532@yahoo.com.cn