

## CASE REPORT

Neurol Med Chir (Tokyo) 52, 686 ~ 690, 2012

## **Syringomyelia and Arachnoid Cysts Associated With Spinal Arachnoiditis Following Subarachnoid Hemorrhage**

### **—Case Report—**

Shunsuke ISHIZAKA,<sup>1</sup> Kentaro HAYASHI,<sup>1</sup> Munehiro OTSUKA,<sup>1</sup>  
Shuji FUKUDA,<sup>1</sup> Keishi TSUNODA,<sup>1</sup> Ryujiro USHIJIMA,<sup>1</sup>  
Naoki KITAGAWA,<sup>1</sup> Kazuhiko SUYAMA,<sup>1</sup> and Izumi NAGATA<sup>1</sup>

<sup>1</sup>Department of Neurosurgery, Nagasaki University, School of Medicine, Nagasaki, Nagasaki

### **Abstract**

A 66-year-old woman with primary Sjogren syndrome developed syringomyelia following two episodes of subarachnoid hemorrhage (SAH) due to the rupture of basilar artery aneurysms. Gait disturbance and abnormal sensation with pain over the foot and abdomen appeared 3 years after the last SAH. Magnetic resonance (MR) imaging revealed a syringomyelia throughout the thoracic cord, from the T2 to T11 levels. In addition, the thoracic cord was compressed by multiple arachnoid cysts in the ventral side of spinal cord. Computed tomography myelography revealed complete block of cerebrospinal fluid (CSF) flow at the T7 level. Surgery for microlysis of the adhesions and restoration of the CSF flow pathway was performed. Postoperatively, leg motor function slowly improved and she could walk unaided. However, abdominal paresthesia was persisted. Postoperative MR imaging revealed diminished size of the syrinxes. We should recognize syringomyelia and arachnoid cysts due to adhesive arachnoiditis as a late complication of SAH. Microlysis of the adhesions focusing on the lesion thought to be the cause of the symptoms is one of the choices to treat massive syringomyelia and arachnoid cysts associated with arachnoiditis following SAH.

Key words: syringomyelia, arachnoid cyst, subarachnoid hemorrhage, adhesive arachnoiditis

## Introduction

Syringomyelia and arachnoid cysts associated with arachnoiditis are commonly caused by trauma, infection, and surgery of the spinal cord, but are rare complications of subarachnoid hemorrhage (SAH). Severe cases with extensive adhesive arachnoiditis are very difficult to treat.<sup>6)</sup> Here, we present a severe case which was successfully treated with a simple surgical strategy.

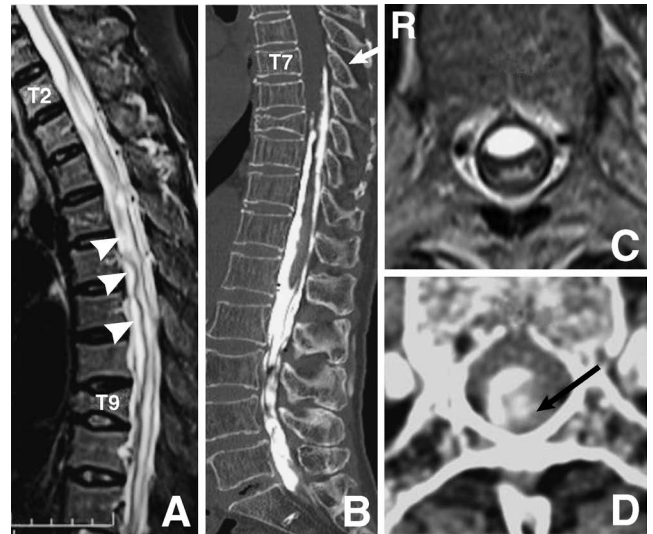
## Case Report

A 46-year-old female patient presented with SAH caused by rupture of a basilar artery and posterior inferior cerebellar artery aneurysm. The patient was treated with craniotomy and clipping of the basilar artery aneurysm. She presented with dry eyes, dry mouth, Raynaud's phenomenon, erythema annulare, and polyarthritides of the hands at age 50 years. Lacrimal and salivary hyposecretion was confirmed by physiological examination. As a result, she was diagnosed with primary Sjögren's syndrome. The patient developed SAH caused by the rupture of the basilar tip aneurysm at age 63 years. She was treated by coil embolization followed by lumbar drainage for a few days. There were no signs of hydrocephalus.

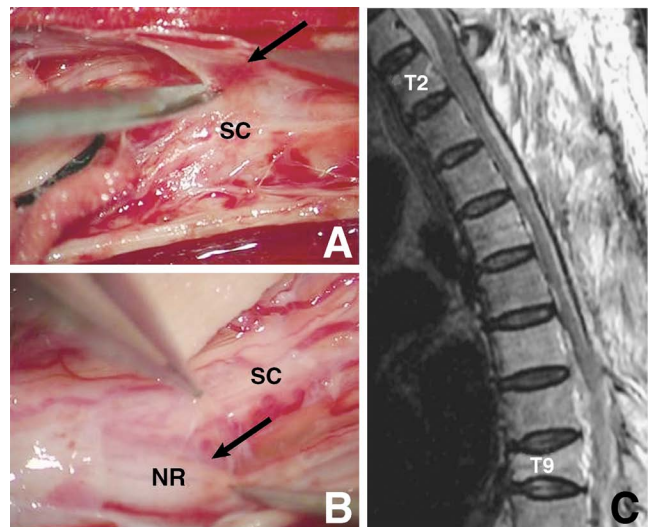
The patient presented at our institution at age 66 years with a 4-month history of gait disturbance and numbness in the lower extremities. On admission, the manual muscle test in the lower extremities demonstrated antigravity strength proximally and 4/5th of antigravity strength distally. However, tone was increased in the bilateral lower extremities. Sensory examination demonstrated pinprick hypesthesia at T10 on the left and T6 on the right, and abnormal sensation with pain on the foot. The patient also complained of gradual worsening of bladder function, with occasional episodes of urinary incontinence. Preoperative examination included lumbar puncture, which



**Fig. 1** Photograph of the viscous and xanthochromic cerebrospinal fluid (CSF) obtained from the lumbar puncture. CSF protein, glucose, adenosine deaminase, and cell count were within normal limits and CSF Gram stain was negative.



**Fig. 2** A: Sagittal T<sub>2</sub>-weighted magnetic resonance (MR) image revealing deformation of the spinal cord and a syrinx cavity extending from the T2 to T11 levels, and multiple arachnoid cysts on the ventral side of spinal cord (arrowheads). B: Sagittal computed tomography (CT) myelogram revealing a complete block of cerebrospinal fluid flow at the T7 level (arrow). C: Axial T<sub>2</sub>-weighted MR image revealing a cyst compressing the spinal cord from the ventral side at the T5-6 level. D: Axial CT myelogram revealing that the spinal cord was displaced laterally due to arachnoid adhesion and the syrinx was filled with contrast medium (arrow) at the T10 level.



**Fig. 3** A: Intraoperative photograph after opening the dura showing thickened arachnoid membrane (arrow) around the spinal cord (SC). B: Intraoperative photograph showing the arachnoid adhesions were carefully dissected, and the spinal cord (SC) and nerve roots (NR) were untethered (arrow). C: Sagittal T<sub>2</sub>-weighted magnetic resonance image revealing diminished size of the syrinxes.

revealed viscous and xanthochromic cerebrospinal fluid (CSF) (Fig. 1). CSF protein, glucose, adenosine deaminase, and cell count were all within normal limits, whereas Gram staining was negative. Preoperative magnetic resonance (MR) imaging revealed extensive syringomyelia from T2 to T11 (Fig. 2A). In addition, the thoracic cord was compressed by multiple cystic lesions on the ventral side (Fig. 2A, C). Computed tomography (CT) myelography revealed complete blockage of CSF flow at T7 (Fig. 2B) and adhesion of the spinal cord to the dura mater laterally (Fig. 2D). The syrinx of the lower thoracic level was filled with contrast medium on CT 24 hours after myelography (Fig. 2D). She was diagnosed with syringomyelia and arachnoid cysts associated with adhesive arachnoiditis. We determined that the isolated subarachnoid space extended from T2 to T7, because contrast medium injected from the L4-5 level stopped at the T7 level on CT myelography and the spinal cord was intact above the T2 level on MR imaging.

Because the symptoms were progressive, laminectomy and microlysis of the adhesions from T2 to T7 were performed. We decided on the range of laminectomy to restore the completely blocked CSF flow and resolve the mass effect caused by the multiple arachnoid cysts from T5 to T7. Shunt placement was not performed because of the risk of surgical site infection and poor outcome according to previous reports. On opening the dura mater, the arachnoid membrane was found to be thick and adhered to the dura mater and spinal cord (Fig. 3A, B). The adhesions were carefully dissected along the plane between the dura mater and arachnoid membrane under the operating microscope, and the spinal cord was released from the T2 to T7 levels. We avoided manipulating the spinal cord as far as possible, and dissected only the arachnoid membrane which could be confirmed without retraction of the spinal cord. A cyst located on the ventral side of the spinal cord at the T5-6 level was punctured, causing CSF to gush out under high pressure. The top level of adhesive arachnoiditis was at the T2 level, so we could open the isolated subarachnoid space to the intact upper subarachnoid space. CSF flowed out from the intact subarachnoid space above the T2 level when the arachnoid membrane was dissected. However, we confirmed the connection between the intact and lesioned subarachnoid spaces at the T2 level. We could not define intact subarachnoid space lower than the T7 level because of intense adhesion of the arachnoid membrane to the surrounding tissue. The dura mater was sutured with 4-0 Nurolon® (Johnson & Johnson Medical Ltd., Livingston, West Lothian, UK). Her urinary incontinence and spastic gait were improved postoperatively and MR imaging demonstrated reduction in the size of the syringes (Fig. 3C). Three years after the surgery, the patient could walk unaided and there was no evidence of the recurrence. However, abdominal paresthesia persisted.

## Discussion

Syringomyelia and arachnoid cysts are rare complications of SAH, with a few reports about this clinical condition

(Table 1). According to previous studies, ruptured aneurysm located in the posterior circulation may pose a higher risk for adhesive arachnoiditis compared with aneurysm in the anterior circulation.<sup>1,5,9,10,13,14</sup> We speculate that the hematoma volume in the spinal subarachnoid space is related with the occurrence of spinal arachnoiditis. Adhesive arachnoiditis occurred in cases treated with both clipping and coiling, so the chronic inflammatory response of the pia-arachnoid mater persisting due to SAH is thought to be a cause of spinal arachnoiditis.<sup>8,12</sup> In addition, according to previous studies, protracted bed rest and fibrin glue usage also cause spinal arachnoiditis.<sup>13</sup> Furthermore, repeated SAH, as well as occult meningitis caused by lumbar drainage, may have contributed to the manifestation of adhesive arachnoiditis in this case. Thus, collapse of the subarachnoid space due to the lumbar drainage might enhance adhesion of the arachnoid membrane. Syringomyelia has been hypothesized to be caused by blockage of the spinal subarachnoid CSF pathway.<sup>4</sup> The syringomyelia tends to improve after the imbalance of subarachnoid pressure around the adhesive point was corrected by the shunt placement. Based on this finding, the imbalance of the subarachnoid pressure around the adhesive point is thought to be the main cause of syringomyelia.<sup>2,3</sup> The interesting point in this case was that the syrinx was filled with contrast medium after myelography, which implied that the CSF in the isolated subarachnoid space could flow into the syrinx after the subarachnoid pressure increased. This mechanism might have contributed to the formation of syringomyelia following adhesive arachnoiditis.

Patients with arachnoid cysts, which tend to occur on the ventral side, demonstrated paraparesis<sup>5,7,13,15</sup> and patients with syringomyelia demonstrated sensory disturbance.<sup>1,5,13</sup> Our patient presented with paraparesis, paresthesia, and urinary incontinence. Multiple arachnoid cysts which compress the spinal cord from the ventral side might contribute to paraparesis as a pyramidal sign. On the other hand, syringomyelia might contribute to paresthesia and urinary incontinence. In particular, tethering of the spinal cord and nerve roots caused by adhesion between the arachnoid and dura mater also might contribute to paresthesia with pain, because our patient presented with severe pain on the foot during the injection of contrast medium. Severe pain on the foot was improved just after the injection of contrast medium. We speculate that the increase of subarachnoid pressure after injection of contrast medium caused tethering of the nerve root.

Surgical decompression tends to improve paraparesis caused by arachnoid cysts. However, paresthesia caused by syringomyelia tends to persist even if syrinx size decreases. Furthermore, shunt placement is a commonly performed operation but is associated with an unfavorable long-term prognosis and high rates of syrinx recurrence and infections.<sup>4</sup> Therefore, we performed only laminectomy and microlysis of adhesion without shunt placement to normalize the CSF flow and achieve decompression of the arachnoid cysts. We speculate that the puncture of arachnoid cysts at the ventral side resulted in recovery of the paraparesis, and the release of the spinal cord and

Table 1 Summary of reported cases of arachnoid cyst and/or syringomyelia following subarachnoid hemorrhage (SAH)

Author (Year)	Aneurysm location	Treatment for SAH	Interval after SAH	Level of adhesive arachnoiditis	Spinal lesion	Treatment for spinal lesion	Presurgical symptoms/outcome
Taguchi et al. (1996) <sup>[3]</sup>	unknown	none	4 yrs	T7-T11	arachnoid cyst	laminectomy, syringostomy, and CSF drainage	paraparesis and paresthesia/persisted
	PICA	clipping	9 mos	at least C2-T4	unknown	laminectomy	paraplegia with sensory/persisted
	VA-PICA	clipping and duraplasty with fibrin glue	4 mos	T6-T8	arachnoid cyst at T3-T8, syringomyelia at T8	laminectomy and microlysis of adhesion	pain sensation/ improved; leg spasticity/persisted
Lorenzana-Honrado et al. (1996) <sup>[8]</sup>	PICA	clipping	unknown	unknown	arachnoid cyst	cyst-peritoneal shunt	lower extremity myelopathy and urinary retention/ improved
Kok et al. (2000) <sup>[7]</sup>	ICA-PcomA	craniotomy	5 wks	T7	arachnoid cyst and spinal cord atrophy at T1-T3	none	paraparesis/ improved; urinary incontinence/persisted
	unknown	none	10 wks	T6-T7	arachnoid cyst at C7-T1	none	pyramidal sign/ improved
Kiekamp et al. (2002) <sup>[6]</sup>	unknown	unknown	unknown	unknown	unknown	unknown	unknown
Brodbeck and Stoodley (2003) <sup>[1]</sup>	PICA	unknown	6 yrs	T1	syringomyelia at C6-T3	1st: syringo-subarachnoid and syringo-peritoneal shunt; 2nd: syringo-subarachnoid and microlysis of adhesion	1st: not improved; 2nd: paraparesis was slightly improved
Tumialan et al. (2005) <sup>[5]</sup>	PICA	ligation of PICA	1 yr	unknown	arachnoid cyst at C7-T3	laminectomy and microlysis of adhesion, cyst-peritoneal shunt	paraparesis/ improved
Nakata et al. (2006) <sup>[10]</sup>	VA-PICA	ligation of VA and OA-PICA anastomosis	6 mos	T3-T4	presyrinx state at T3	syringo-subarachnoid shunt	paraparesis/persisted; paresthesia/ improved
Eneling et al. (2012) <sup>[9]</sup>	AcomA	coiling	18 mos	T3-T5	arachnoid cysts at T3-T5, syringomyelia at T5-T11	1st: laminectomy and microlysis of adhesion, cyst-peritoneal shunt; 2nd: shunt revision	paraparesis/ improved; paresthesia/persisted
	PICA	endovascular embolization	6 yrs	at least T4-T9	syringomyelia at C1-T11	laminectomy and microlysis of adhesion	tetraparesis, urinary incontinence, and sensibility deficit/persisted

AcomA: anterior communicating artery, CSF: cerebrospinal fluid, ICA: internal carotid artery, PcomA: posterior communicating artery, PICA: posterior inferior cerebellar artery, VA: vertebral artery.

nerve roots resulted in the improvement of paresthesia with pain in this case. Our strategy might be reasonable as treatment for severe cases with syringomyelia and multiple arachnoid cysts due to adhesive arachnoiditis. A previous case was successfully treated with expansive laminoplasty and duraplasty using a Gore-Tex membrane.<sup>11)</sup> We agree with this strategy, because the essential aim of the treatment is normalization of CSF flow and one of the key points for good outcome is to avoid the recurrence of adhesive arachnoiditis. However, we performed duraplasty without Gore-Tex to avoid surgical site infection due to the usage of steroids for Sjögren's syndrome. If the syrinx size increases in follow-up examinations, we plan to implement the shunt procedure. However, discussion regarding the best treatment method for syringomyelia and arachnoid cysts associated with arachnoiditis is still underway. The treatment strategy should be decided on the basis of the extent of syringomyelia and adhesive arachnoiditis. In addition, clarification of the symptom to be improved and the lesion thought to cause the symptom are most important. For severe cases as in the present patient, the surgical treatment should be focused on the lesion which contributes to motor function, especially arachnoid cysts in this case. Extensive arachnoid scarring may be strongly associated with poor clinical outcomes.<sup>4)</sup> Needless to say, early-stage diagnosis is most important for a good clinical outcome.

In conclusion, syringomyelia and arachnoiditis should be recognized as late complications of SAH. Severe cases with extensive arachnoiditis can be treated with laminectomy and microlysis of the adhesion. Our surgical strategy focusing on the lesion thought to cause the symptom, especially motor weakness, may be useful for severe cases.

## References

- 1) Brodbelt AR, Stoodley MA: Syringomyelia and the arachnoid web. *Acta Neurochir (Wien)* 145: 707-711, 2003
- 2) Caplan LR, Norohna AB, Amico LL: Syringomyelia and arachnoiditis. *J Neurol Neurosurg Psychiatry* 53: 106-113, 1990
- 3) Chang HS, Joko M, Matsuo N, Kim SD, Nakagawa H: Subarachnoid pressure-dependent change in syrinx size in a patient with syringomyelia associated with adhesive arachnoiditis. Case report. *J Neurosurg Spine* 2: 209-214, 2005
- 4) Chang HS, Nakagawa H: Theoretical analysis of the pathophysiology of syringomyelia associated with adhesive arachnoiditis. *J Neurol Neurosurg Psychiatry* 75: 754-757, 2004
- 5) Eneling J, Bostrom S, Rossitti S: Subarachnoid hemorrhage-associated arachnoiditis and syringomyelia. *Clin Neuroradiol* 22: 169-173, 2012
- 6) Klekamp J, Iaconetta G, Batzdorf U, Samii M: Syringomyelia associated with foramen magnum arachnoiditis. *J Neurosurg* 97(3 Suppl): 317-322, 2002
- 7) Kok AJ, Verhagen WI, Bartels RH, van Dijk R, Prick MJ: Spinal arachnoiditis following subarachnoid haemorrhage: report of two cases and review of the literature. *Acta Neurochir (Wien)* 142: 795-799, 2000
- 8) Koyanagi I, Iwasaki Y, Hida K, Houkin K: Clinical features and pathomechanisms of syringomyelia associated with spinal arachnoiditis. *Surg Neurol* 63: 350-356, 2005
- 9) Lorenzana-Honrado L, Cabezudo-Artero JM, Gozez-Perals L: Arachnoid cyst. *J Neurosurg* 85: 734-735, 1996
- 10) Nakata Y, Yagishita A, Taniguchi M: [The presyrinx state due to adhesive arachnoiditis: a case report.]. *No To Shinkei* 58: 500-504, 2006 (Japanese)
- 11) Ohata K, Gotoh T, Matsusaka Y, Morino M, Tsuyuguchi N, Sheikh B, Inoue Y, Hakuba A: Surgical management of syringomyelia associated with spinal adhesive arachnoiditis. *J Clin Neurosci* 8: 40-42, 2001
- 12) Sercombe R, Dinh YR, Gomis P: Cerebrovascular inflammation following subarachnoid hemorrhage. *Jpn J Pharmacol* 88: 227-249, 2002
- 13) Taguchi Y, Suzuki R, Okada M, Sekino H: Spinal arachnoid cyst developing after surgical treatment of a ruptured vertebral artery aneurysm: a possible complication of topical use of fibrin glue. Case report. *J Neurosurg* 84: 526-529, 1996
- 14) Tjandra JJ, Varma TR, Weeks RD: Spinal arachnoiditis following subarachnoid haemorrhage. *Aust N Z J Surg* 59: 84-87, 1989
- 15) Tumialan LM, Cawley CM, Barrow DL: Arachnoid cyst with associated arachnoiditis developing after subarachnoid hemorrhage. Case report. *J Neurosurg* 103: 1088-1091, 2005

---

Address reprint requests to: Shunsuke Ishizaka, MD, Department of Neurosurgery, Nagasaki University School of Medicine, 1-7-1 Sakamoto, Nagasaki 852-8501, Japan.