

Rare disease

Extensive extracranial and intracranial Varicella zoster vasculopathy

Rajesh Verma, Rakesh Lalla, Tushar B Patil

Department of Neurology, Chhatrapati Shahuji Maharaj Medical University, Lucknow, Uttar Pradesh, India

Correspondence to Professor Rajesh Verma, drrajeshverma32@yahoo.com

Summary

Varicella zoster virus (VZV)-induced vasculopathy is an uncommon cause of stroke in a young immunocompetent host. Owing to scarcity of data of VZV-induced vasculopathy and lack of awareness about this condition and its diagnostic test, these cases may be easily missed. In this case, we report an immunocompetent host presenting right-side hemiplegia with motor aphasia and complete loss of vision in the left eye due to complete occlusion of the left common carotid artery without any history of skin rash preceding stroke. Cerebrospinal fluid analysis for varicella antibody revealed very high titres and CT aortogram demonstrated aortoarteritis with occlusion of left common carotid artery. To our knowledge, varicella zoster vasculopathy-associated aortoarteritis has not been described in the literature.

BACKGROUND

Varicella zoster virus (VZV) is a neurotropic α herpes virus, which primarily causes chicken pox in children. The reactivation of the latent virus due to deficient T-cell-mediated immunity can lead to herpes zoster. Varicella zoster-induced vasculopathy has been reported in numerous reports since 1970. Although it is considered as an important cause of stroke and transient ischaemic attacks (TIA) in children, however its data in adults are still lacking. The adult onset vasculopathy is more commonly seen in immunocompromised host and usually occurs following herpes zoster even in the absence of rash (zoster sine herpete). Both the large as well as small arteries can be involved in VZV vasculopathy and diagnosis requires high degree of clinical suspicion (especially in the absence of rash) and confirmation with CSF PCR and IgM antibodies against VZV. However, aortoarteritis associated with VZV vasculopathy has not been described in the literature.

CASE PRESENTATION

A right-handed, young business man, aged 30 years, has been referred to our institute from a private hospital with chief complaints of sudden onset of weakness in the right half of the body since the last 10 days. The patient was apparently alright 10 days ago when he suddenly developed profound weakness in the right half of his body and face. His relatives noticed that he was unable to move his right arm and leg and there was an angle of deviation of the mouth to the left side. Within 1–2 h the patient became drowsy but arousable. He was also unable to speak and occasionally understood whatever was spoken to him. The informant denied any premorbid history of hypertension, diabetes mellitus, ischaemic or valvular heart disease. There was no family history of stroke, haemoglobinopathy, bleeding disorders or premature vascular disease.

On examination, his pulse was regular but left carotid and left radial pulse was feeble compared with the right

side. Rest of the pulses were palpable. He was found to be hypertensive (blood pressure 140/100), no significant difference in blood pressure in any limb. He was drowsy, irritable and Glasgow coma score (GCS) was 12/15. There was no rash, arthritis, oral ulcers, cutaneous infarcts or stigmata of tuberculosis.

On neurological assessment, he was drowsy, irritable and inattentive. Motor aphasia was present and comprehension was limited to simple verbal commands. Cranial nerve examination revealed absent menace reflex in left eye and absent direct light reflex along with normal consensual light reaction in the left eye. Funduscopy of the left eye revealed diffusely pale retina suggestive of central retinal artery obstruction. Partial ptosis of the left eye lid was noted and right upper motor neuron-type facial paralysis was also seen. Power in the left upper limb and lower limb was grade 5 and right upper limb and lower limb was grade 0 as per medical research council (MRC) grading. Babinski response was seen on the right side.

INVESTIGATIONS

Complete haemogram, renal and liver function tests were within normal limits. Erythrocyte sedimentation rate was 36. Antinuclear antibody by immunofluorescence, anti-phospholipid IgG antibodies and anti-neutrophil cytoplasmic antibody (ANCA) were not detected. IgG toxoplasmosis in the serum was negative. ELISA for HIV-1 and 2 was not reactive and Venereal Disease Research Laboratory (VDRL) was negative. CSF examination revealed protein value of 68 mg/dl, sugar 72 mg/dl, 40 cells (95% were lymphocytes) and was negative for cryptococcal antigen. Anti-varicella zoster virus IgG antibody in the cerebrospinal fluid (CSF) (Novatech Immuno diagnostic GmbH, Berlin, Germany) was significantly elevated (32.2 novatech units (NTU)), levels less than 9 NTU are considered negative. CSF antibodies against Japanese encephalitis virus, Herpes simplex virus and dengue virus

were negative. CSF PCR for tuberculosis was negative. The echocardiogram did not reveal any abnormality. MRI of the brain done initially revealed moderate size rounded, irregular and confluent intra-axial lesions involving the left ganglio-capsular and fronto-parieto-temporal regions with patchy enhancement on contrast. Hence, the differential diagnosis of vasculitic infarct or granulomatous disease like tuberculosis was considered. MRI of the brain was repeated along with MR angiogram, which showed T2 hyperintensity with restriction on DWIs with low ADC value in the left basal ganglia, external capsule and left temporal region suggestive of acute infarct (figure 1). There are areas of blooming on gradient echo images suggestive of haemorrhagic transformation. The M2 and M3 segments of the left middle cerebral artery (MCA) and A1 segment of anterior cerebral artery (ACA) appear thrombosed and there is vasospasm in the rest of the MCA (figure 2). CT aortography revealed thickening and failure of opacification of the left common carotid and most of the external and internal carotid (figure 3).

DIFFERENTIAL DIAGNOSIS

Few other conditions such as tuberculous vasculitis, sarcoidosis, fungal infections, neurosyphilis, autoimmune

vasculitis such as systemic lupus erythematous (SLE), ANCA-associated vasculitis; giant cell arteritis (especially in the elderly) may have similar clinico-radiological presentation. Hence, appropriate testing for aetiology should be done.

TREATMENT

The patient was initially started on anti-tuberculosis drugs with steroids based on the findings of the first MRI. It was later stopped and subsequently on CSF analysis, anti-IgG VZV was found in high titres. Hence, the patient was started on intravenous steroids for 3 days and intravenous acyclovir 10 mg/kg three times daily for 14 days. Oral low-dose aspirin 75 mg was added. The patient was advised limb physiotherapy and speech therapy.

OUTCOME AND FOLLOW-UP

The patient was admitted in the neurology ward for 21 days and gradually improved clinically. The patient became more alert and motor aphasia improved in terms of content after speech therapy. Power also improved from grade 0 to grade 2 in the right upper limb and lower limb. Presently, he can turn in bed on his own or with minimal

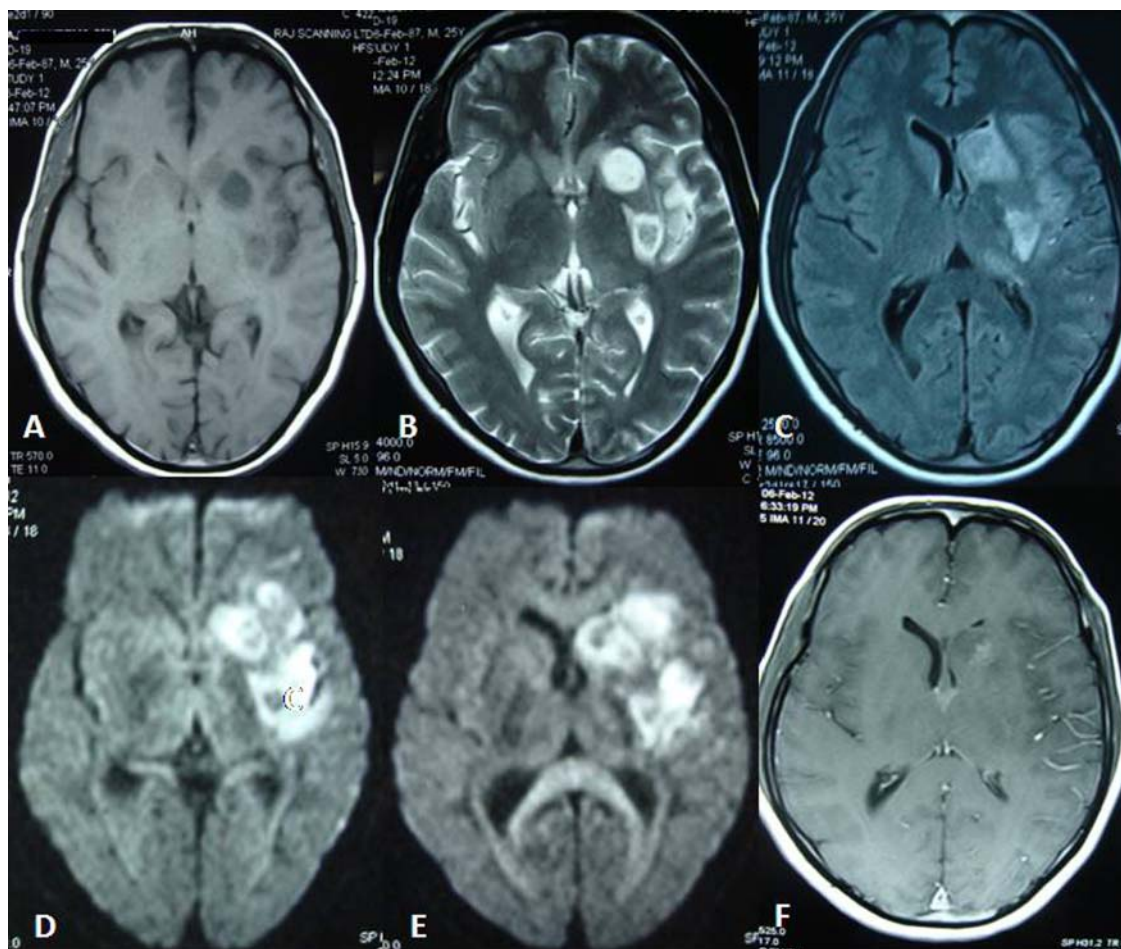


Figure 1 MRI of the brain (A) T1-weighted images showing hypointensities in the left caudate, external capsule and insular cortex, (B) and (C) T2-weighted MRI and T2 FLAIR (Fluid Attenuated Inversion Recovery) images show heterogeneous hyperintensities in left caudate, thalamus, globus pallidus, internal capsule, external capsule and insular cortex, (D and E) show restriction on DWI in the above mentioned regions. (F) MRI contrast shows patchy enhancement of the left caudate.

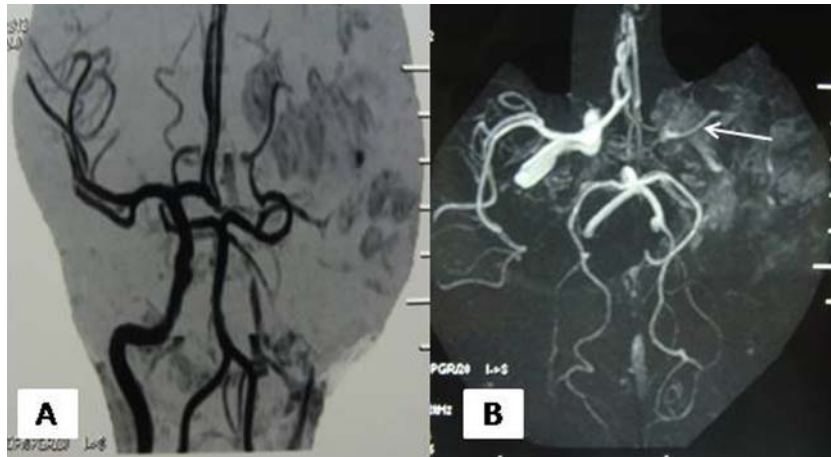


Figure 2 A & B MR Angiogram: occlusion of left internal carotid, left MCA.

assistance. However, there was only slight improvement in the vision of the left eye with the patient barely appreciating projection of light and perception of light.

DISCUSSION

This case report describes varicella-induced aortoarteritis leading to occlusion of the common carotid and its branches in an immunocompetent young man with no evidence of chicken pox (primary infection) or herpes zoster (reactivation).

Cravioto and Feign first described granulomatous non-infectious angitis affecting cerebral blood vessels characterised by thrombosis and inflammatory cells such as histiocytes, mononuclear cells and multinucleated giant cells.¹ Later on, similar findings were described by Rosenblum and Hadfield² in patients with herpes zoster and lymphosarcoma leading to granulomatous angitis. The exact incidence of VZV vasculopathy is not known but it seems to be high in children and immunocompromised hosts. In a study of unilateral intracranial arteriopathy in children, 44% cases of transient cerebral arteriopathy had chicken pox preceding stroke.³

VZV is the only known human virus that can replicate in the cerebral arteries.⁴ Direct viral invasion of brain parenchyma during primary infection, contiguous spread through cerebral vessels and autoimmune response leading to tissue injury are few of the mechanisms that have been hypothesised for varicella-induced vasculopathy. Apart from haematogenous dissemination, direct spread through ophthalmic nerve has also been hypothesised.^{5 6} Kang *et al* observed that the risk of stroke in elderly individuals increased by 31% post herpes zoster attacks anywhere in the body and almost by four times after zoster ophthalmicus. The increase in risk was observed for both types of strokes haemorrhagic as well as ischaemic with high prevalence of haemorrhagic stroke in Asian and Chinese populations.^{7 8}

The pathophysiology behind the selective involvement of large vessels was considered analogous to that occurring in the Moya Moya disease. The exaggerated sympathetic stimulation of superior cervical ganglion and sympathetic nerves due to intense pain and chronic recurrent inflammation along with circulating antigen-antibody complexes predisposes ipsilateral thrombosis of carotid

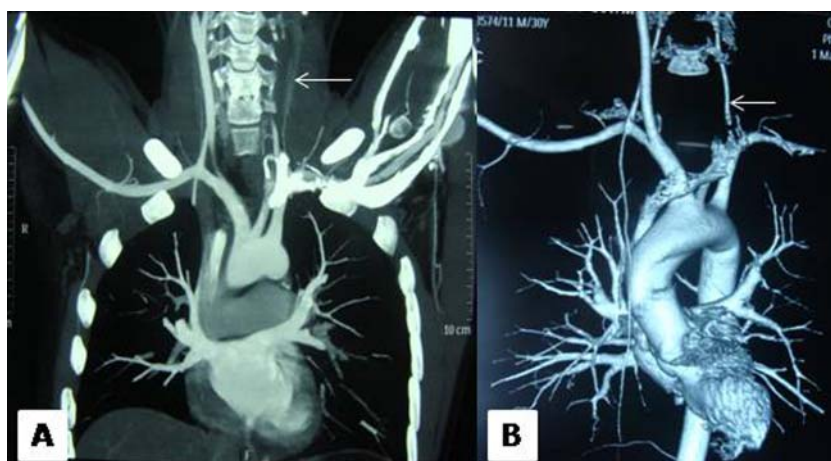


Figure 3 (A) and (B) CT aortogram near complete occlusion of the left common carotid artery.

arteries.^{4 9} The vascular affection of VZV is not limited to large vessels as was thought previously.

The clinical spectrum can be divided into two major types according to the types of vessels involved as large vessel disease, medium vessel and small vessel disease. Large vessel involvement is common in an immunocompetent host, in children it occurs due to virus-induced inflammation and presents mostly as acute hemiplegia, ataxia, monocular blindness, etc.^{23 10} Small vessel vasculitis produces non-specific symptoms such as fever, headache, seizures, encephalitis and cognitive decline. This type of presentation is common in the immunocompromised host.¹⁰ The vasculopathy can be unifocal or multifocal and it may develop many months after the rash has disappeared. Both small vessel and large vessel disease occurring together have also been reported in HIV-positive patients.^{11–13}

Most of the patients with VZV vasculopathy have findings on brain imaging. MRI of the brain reveals multiple cortical infarcts, infarcts at grey–white matter junction and deep infarcts in central grey and white matter and brainstem. Most of the lesions are ischaemic and enhance partly or completely on gadolinium.^{6 12} In our patient, the presence of similar radiological presentation of thalamic infarct and multiple cortical infarctions with patchy enhancement on contrast led to suspicion of infective vasculopathy. The angiography changes of VZV vasculopathy comprise of segmental constriction with post-stenotic dilation. The most common finding is that both small vessel and large vessel disease and pure large vessel are least common.⁶ The evaluation of CSF may reveal moderate lymphocytic predominant pleocytosis, presence of RBCs and mildly elevated protein along with IgG oligoclonal bands against VZV. IgG antibody against VZV is the investigation of choice as it has better diagnostic value than VZV DNA PCR. This is due to the time lag between the varicella infection and the onset of vascular symptoms making VZV DNA undetectable in CSF within 14–50 days of infection.^{13 14} Few protean complications associated with VZV are aneurysm, ectasia formation and carotid dissection. These occur due to infection of tunica media of the arteries and disruption of internal elastic lamina. VZV vasculopathy is associated with other complications such as subarachnoid haemorrhage, spinal cord infarction, peripheral artery disease and polyneuritis cranialis.^{15 16} Jain *et al*¹⁶ have reported a case of subarachnoid haemorrhage due to diffuse small and medium vessel vasculitis along with herpes zoster. The vasculitic changes partly recovered on use of acyclovir and methylprednisolone.

The use of intravenous acyclovir (10–15 mg/kg thrice daily) for 14 days has category III recommendation with use of short course of steroid (prednisolone 1 mg/kg) for 5 days to reduce inflammation in cerebral vessels and stopping it without tapering.^{6 15} In our patient, we used IV acyclovir for 14 days along with 3 days of IV methyl prednisolone (1 g/day).

Learning points

- ▶ Stroke in the young population puts substantial burden on the society.
- ▶ The causes of stroke are different in the younger population: cardioembolic stroke, infective arteritis (tuberculous, HIV, Varicella zoster), aorto-arteritis and hypercoagulable state.
- ▶ Varicella zoster-induced vasculopathy involved both small and large intracranial vessels and causes stroke in immunocompetent as well as immunodeficient individuals.
- ▶ Varicella zoster is an uncommon cause of stroke in the young.
- ▶ Extensive extracranial and intracranial vasculature involvement has not been previously reported in the literature.
- ▶ The timely administration of intravenous acyclovir therapy seems to greatly affect the clinical outcome.

Competing interests None

Patient consent Obtained.

REFERENCES

1. **Cravioto H**, Feigin I. Noninfectious granulomatous angiitis with a predilection for the nervous system. *Neurology* 1959;**9**:599–608.
2. **Rosenblum WI**, Hadfield MG. Granulomatous angiitis of the nervous system in cases of herpes zoster and lymphosarcoma. *Neurology* 1972;**22**:348–54.
3. **Braun KPJ**, Bulder MMM, Chabrier S, *et al*. The course and outcome of unilateral intracranial arteriopathy in 79 children with ischaemic stroke. *Brain* 2009;**132**:544–57.
4. **Bodensteiner JB**, Hille MR, Riggs JE. *Clinical features of vascular thrombosis following Varicella* AJDC. 1992;**146**:100–2.
5. **Kleinschmidt-DeMasters BK**, Gilden DH. Varicella-zoster virus infections of the nervous system: clinical and pathologic correlates. *Arch Pathol Lab Med* 2001;**125**:770–80.
6. **Nagel MA**, Cohrs RJ, Mahalingam R, *et al*. The varicella zoster virus vasculopathies. Clinical, CSF, imaging, and virologic features. *Neurology* 2009;**70**:853–60.
7. **Kang JH**, Ho JD, Chen YH, *et al*. Increased risk of stroke after a herpes zoster attack a population-based follow-up study. *Stroke* 2009;**40**:3443–8.
8. **Potluri R**, Natalwala A. Increasing prevalence of haemorrhagic stroke among South Asian patients in the United Kingdom from 1997 to 2005. *J Clin Neurosci* 2009;**16**:605–6.
9. **Suzuki J**. *Moya Moya disease*. New York, NY: Springer-Verlag NY Inc, 1983: 131–43.
10. **Gilden DH**. Varicella zoster virus vasculopathy and disseminated encephalomyelitis. *J Neurol Sci* 2002;**195**:99–101.
11. **Ortiz GA**, Koch S, Forteza A, *et al*. Ramsay Hunt syndrome followed by multifocal vasculopathy and posterior circulation strokes. *Neurology* 2008;**70**:1049–51.
12. **Gilden DH**, Mahalingam R, Cohrs RJ, *et al*. The protean manifestations of varicella-zoster virus vasculopathy. *J Neuroviral* 2002;**8**:75–9.
13. **Russman AN**, Lederman RJ, Calabrese LH, *et al*. Multifocal varicella zoster virus vasculopathy without rash. *Arch Neurol* 2003;**60**:1607–9.
14. **Nagel MA**, Forghani B, Mahalingam R, *et al*. The value of detecting anti-VZV antibody in CSF to diagnose VZV vasculopathy. *Neurology* 2007;**68**:1069–73.
15. **Gilden DH**, Cohrs RJ, Mahalingam R, *et al*. Varicella zoster virus vasculopathies: diverse clinical manifestations, laboratory features, pathogenesis and treatment. *Lancet Neurol* 2009;**8**:731–40.
16. **Jain R**, Deveikis J, Hickenbottom S, *et al*. Varicella Zoster vasculitis presenting with intracranial haemorrhage. *Am J Neuroradiol* 2003;**24**:971–4.

This pdf has been created automatically from the final edited text and images.

Copyright 2012 BMJ Publishing Group. All rights reserved. For permission to reuse any of this content visit <http://group.bmj.com/group/rights-licensing/permissions>.

BMJ Case Report Fellows may re-use this article for personal use and teaching without any further permission.

Please cite this article as follows (you will need to access the article online to obtain the date of publication).

Verma R, Lalla R, Patil TB. Extensive extracranial and intracranial Varicella zoster vasculopathy. *BMJ Case Reports* 2012;10.1136/bcr-2012-006845, Published XXX

Become a Fellow of BMJ Case Reports today and you can:

- ▶ Submit as many cases as you like
- ▶ Enjoy fast sympathetic peer review and rapid publication of accepted articles
- ▶ Access all the published articles
- ▶ Re-use any of the published material for personal use and teaching without further permission

For information on Institutional Fellowships contact consortiasales@bmjgroup.com

Visit casereports.bmj.com for more articles like this and to become a Fellow