

A mucormycosis case presented with orbital apex syndrome and hemiplegia in a renal transplant patient

Mehmet Nuri Turan · Erhan Tatar · Mustafa Yaprak · Bilgin Arda ·
Ömer Kitiş · Dilek Yeşim Metin · Cüneyt Hoşçoşkun · Hüseyin Töz

Received: 16 July 2012 / Accepted: 10 September 2012
© Springer Science+Business Media Dordrecht 2012

Abstract Solid organ transplantation is a risk factor for mucormycosis. Mucormycosis is a necrotizing opportunistic fungal infection with high morbidity and mortality. We report a fatal mucormycosis case with rhino-orbital-cerebral involvement in a renal transplant patient, which presented with orbital apex syndrome and hemiplegia.

Keywords Mucormycosis · Orbital apex syndrome · Hemiplegia · Renal transplantation

M. N. Turan (✉) · E. Tatar · M. Yaprak · H. Töz
Department of Nephrology, Ege University School
of Medicine, 35100 Bornova, Izmir, Turkey
e-mail: mnturan@mail.com

B. Arda
Department of Infectious Disease and Clinical
Microbiology, Ege University School of Medicine,
Izmir, Turkey

Ö. Kitiş
Department of Radiology, Ege University School
of Medicine, Izmir, Turkey

D. Y. Metin
Department of Microbiology and Clinical Microbiology,
Ege University School of Medicine, Izmir, Turkey

C. Hoşçoşkun
Department of General Surgery, Ege University School
of Medicine, Izmir, Turkey

Introduction

Opportunistic infections are important life-threatening problems despite advances in treatment, especially in the immunosuppressive patients like solid organ recipients [1, 2]. Mucormycosis caused by infection with fungi of the family Mucoraceae is a necrotizing opportunistic fungal infection with high morbidity and mortality [3, 4].

Orbital apex syndrome (OAS) is a rare syndrome with retro-orbital pain, complete ophthalmoplegia, and visual loss due to the optic nerve dysfunction together with damage of the oculomotor nerve (III), trochlear nerve (IV), abducens nerve (VI), and ophthalmic branch of the trigeminal nerve (V1) [5].

We report a clinically atypical and fatal mucormycosis case with rhino-orbital-cerebral involvement in a renal transplant patient, initially presented with OAS and then progressed to hemiplegia.

Case

A 54-year-old male patient underwent renal transplantation from a 2 HLA-mismatched, 67-year-old, expanded criteria, deceased donor in May 2011. Panel-reactive antibody was detected 0 %. Cold ischemia time was 16 h. He had a history of chronic atrial fibrillation. He did have diabetes and any history of other cardiovascular risk factors. He was on continuous ambulatory peritoneal dialysis (CAPD)

treatment for 6 years. Primary renal disease was unknown. Antithymocyte immunoglobulin (ATG, Fresenius) was preferred for induction therapy according to our clinic approach in deceased donors. Seven hundred milligrams of ATG was given within 14 days after renal transplantation. ATG dosage was adjusted to keep the absolute CD3+ T-cell count between 25 and 50/mm³. The patient received methylprednisone I.V. 500 mg b.i.d in the pretransplant and post-transplant period at day 0. Steroid dose was gradually reduced to 30 mg/day by 9th day post-transplant. Mycophenolate sodium (MPS) was started at a dose of 1,440 mg/day at the day of operation. Postoperatively, the patient had adequate urine output. But slow graft function (defined by serum Cr > 3 mg/dl on postoperative day 5 but no need for dialysis) was observed. When the creatinine level fell below 3 mg/dl, tacrolimus was started at the dose of 0.1 mg/kg. The target range for tacrolimus was 10–15 ng/mL. Metoprolol (100 mg/day) and prophylactic enoxaparin sodium (60 mg/day) were started at the 7th day postoperatively due to the chronic atrial fibrillation. In the follow-up, serum creatinine level decreased to 1 mg/dl.

On day 12, the patient suffered from headache at the right side of the head. Ear–nose–throat and neurological examination was normal. Brain computed tomography did not reveal any abnormalities. On day 16, the patient complained of severe right orbital pain, ptosis, and ophthalmoplegia. Cranial magnetic resonance imaging did not reveal any pathology to explain the clinical findings. In orbital CT, there was no orbital pathology, but mucosal thickening compatible with sinusitis of the maxillary and sphenoidal sinuses existed. The patient had fever, 36.7 °C. White-cell count and C-reactive protein level were estimated 17,130/mm³ and 16.24 mg/dl, respectively. Teicoplanin and meropenem were started empirically after the cultures. In the follow-up, the patient underwent a second MRI because of newly developed left hemiplegia. Acute ischemic changes were found at the level of vertex in the right cerebral hemisphere internal watershed zone (Fig. 1). The thrombus was not detected in the heart cavities with transthoracic echocardiography. Black necrotic crusts were detected in the bilateral nasal cavities by oro-nasal fiber optic endoscopy, and a biopsy specimen from necrotic area was taken for mycological examination. Thereafter, 5 mg/kg/day liposomal amphotericin B (AmB) was started. Tacrolimus treatment was discontinued, and

MPS dose was reduced. Serum creatinine level was 1.1 mg/dl. Maxillofacial CT scan, which was taken on the same day, revealed focal hypodense areas especially at the frontal region, mucosal thickening at the right frontal, right maxillary and both ethmoid sinuses and aeration loss on sphenoid sinus. Follow-up MRI examination showed marked progression of the cerebral watershed infarction (Fig. 2). Multifocal acute ischemic foci at the level of the right cerebral hemisphere internal watershed zone vertex spread to the right frontal region and occipital lobe.

The patient had worsened clinically, bilaterally phthisis bulbi was developed, and he became unconscious. Respiratory failure developed, and he was intubated. A biopsy from nasal cavity culture revealed the growth of *Rhizopus*. Debridement could not be performed because of the unstable vital signs. All immunosuppressive therapies were discontinued. On day 29, despite the supportive and specific antimycotic treatment, cardiac arrest developed and the patient died.

Discussion

Zygomycosis is a rare invasive fungal infection. The incidence of zygomycosis in solid organ transplant recipients is 2 per 1,000 patients [4]. The incidence of mucormycosis in renal transplant recipients was 0.4–0.5 per 1,000 patients [6, 7].

The most commonly found organisms are *Rhizopus* and *Mucor* [3, 8]. The most common risk factors observed with mucormycosis are diabetes mellitus, especially with ketoacidosis, immunosuppressive conditions like hematologic malignancies and solid organ transplantations [3, 4, 9].

Mortality of zygomycosis in organ transplant recipients is about 38–48 % [3, 4, 8]. Rhino-orbital-cerebral involvement of zygomycosis is important with 93 % mortality rate [4]. It usually begins in the nasal and paranasal sinuses and then spreads to orbita and cerebrum [10]. Spreading to cerebrum, which is responsible for the worst prognosis, can be prevented with early debridement. Therefore, mucormycosis should be considered in the differential diagnosis of organ transplant recipients with a normal clinical presentation like OAS, albeit our case was fatal.

Orbital apex syndrome (OAS) is a rare syndrome with retro-orbital pain, complete ophthalmoplegia,

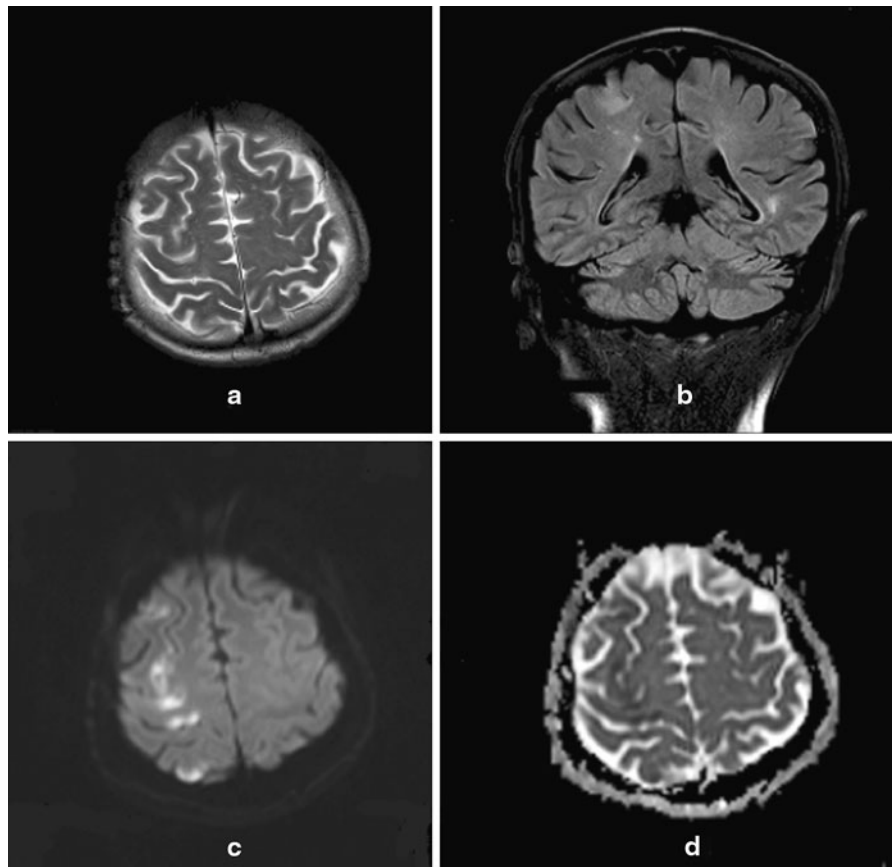


Fig. 1 T2-weighted **a** MRI and FLAIR sequence **b** show cortical hyperintense areas at the initial stage. Corresponding diffusion-weighted MRI (**c** b1000 image and **d** ADC map) reveals restricted diffusion consistent with acute cortical watershed infarction

and visual loss. In the etiology of the OAS, inflammatory, infectious, neoplastic, iatrogenic/traumatic, and vascular pathologies should be considered. A fungal cause should be suspected in patients with immunosuppressive conditions like solid organ transplants [5, 11].

Spreading to cerebrum of mucormycosis can also be presented with cerebral infarct [12]. The invasion of vasculature by hyphae presumably leads to infarction and necrosis of host tissues [13]. Our case had a history of chronic atrial fibrillation. There was no thrombus in the cavities of the heart by transthoracic echocardiography. The cerebral infarct has progressed follow-up. We suggested this infarction due to the mucormycosis infection although postmortem autopsy or cerebral biopsy was not performed.

Mucormycosis presented with OAS and hemiplegia is an unusual clinical situation. In the follow-up of our case, slow graft function was observed. Therefore, the

induction therapy with ATG was given within 14 days after renal transplantation. When the creatinine level fell below 3 mg/dl, tacrolimus was started and ATG therapy was stopped. Effect of ATG as an immunosuppressive therapy could be responsible for the development of mucormycosis. The patient had no history of diabetes that could be a risk factor for mucormycosis. In the follow-up, the levels of glucose were in normal range. At the beginning of patient's symptoms, the physical examination and brain computed tomography did not reveal any abnormalities. But in a few days, the patient's clinical condition had worsened progressively. As soon as black necrotic crusts were detected in the bilateral nasal cavities, we suspected mucormycosis and started AmB empirically.

When surgery was combined with AmB, compared with AmB alone, mucormycosis outcome was better in solid organ transplant patients [4]. Surgical

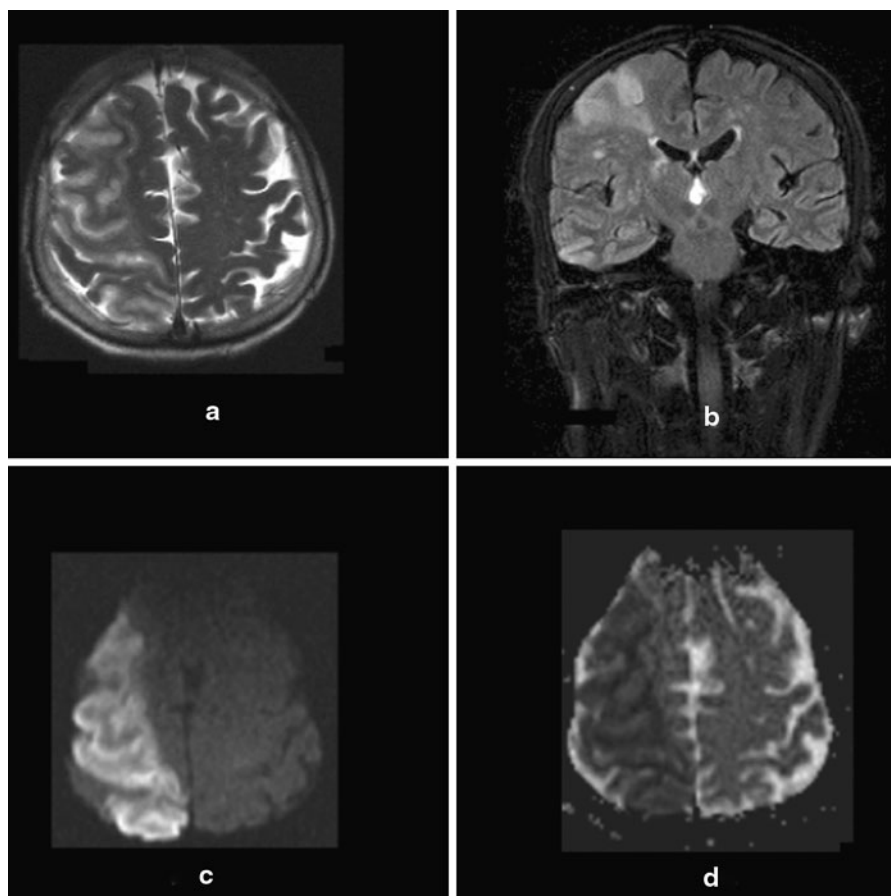


Fig. 2 Follow-up MRI examination shows marked progression of the cerebral watershed infarction (**a** T2-weighted, **b** FLAIR, **c** b1000, and **d** ADC map)

intervention to our case could not be possible. However, surgery cannot be effective in cerebral mucormycosis. In a recent study, surgical debridement was not associated with better survival in recipients with mucormycosis who have central nervous system involvement [14].

Conclusion

Solid organ transplantation is a risk factor for mucormycosis. Particularly, cerebral involvement has high mortality rate. Early diagnosis and treatment can be valuable to prevent spreading of mucormycosis to cerebrum. Mucormycosis should be considered in the differential diagnosis of organ transplant recipients

with atypical clinical presentation like OAS or hemiplegia.

Conflict of interest The authors declare no conflict of interest.

References

1. Fishman JA (2007) Infection in solid-organ transplant recipients. *N Engl J Med* 357:2601–2614
2. Fishman JA, Issa NC (2010) Infection in organ transplantation: risk factors and evolving patterns of infection. *Infect Dis Clin North Am* 24:273–283
3. Roden MM, Zaoutis TE, Buchanan WL et al (2005) Epidemiology and outcome of zygomycosis: a review of 929 reported cases. *Clin Infect Dis* 41:634–653
4. Almyroudis NG, Sutton DA, Linden P et al (2006) Zygomycosis in solid organ transplant recipients in a tertiary

- transplant center and review of the literature. *Am J Transpl* 6:2365–2374
5. Yeh S, Foroozan R (2004) Orbital apex syndrome. *Curr Opin Ophthalmol* 15:490–498
6. Nampoory MR, Khan ZU, Johnny KV et al (1996) Invasive fungal infections in renal transplant recipients. *J Infect* 33:95–101
7. Abbott KC, Hypolite I, Poropatich RK et al (2001) Hospitalizations for fungal infections after renal transplantation in the United States. *Transpl Infect Dis* 3:203–211
8. Singh N, Aguado JM, Bonatti H et al (2009) Zygomycosis in solid organ transplant recipients: a prospective, matched case-control study to assess risks for disease and outcome. *J Infect Dis* 200:1002–1011
9. Kauffman CA, Malani AN (2007) Zygomycosis: an emerging fungal infection with new options for management. *Curr Infect Dis Rep* 9:435–440
10. Lehrer RI, Howard DH, Sypherd PS et al (1980) Mucormycosis. *Ann Intern Med* 93:93–108
11. Bohlega SA (1998) Clinical approach to ophthalmoplegia in renal transplant recipients differential diagnosis and case illustration. *Saudi J Kidney Dis Transpl* 9:27–32
12. Koc Z, Koc F, Yerdelen D et al (2007) Rhino-orbital-cerebral mucormycosis with different cerebral involvements: infarct, hemorrhage, and ophthalmoplegia. *Int J Neurosci* 117:1677–1690
13. Petrlikos G, Skiada A, Lortholary O et al (2012) Epidemiology and clinical manifestations of mucormycosis. *Clin Infect Dis* 54(Suppl 1):S23–S34
14. Sun HY, Forrest G, Gupta KL et al (2010) Rhino-orbital-cerebral zygomycosis in solid organ transplant recipients. *Transplantation* 90:85–92