

CLINICAL CASE REPORTS

Letters to the Editor will be published if suitable,
and as space permits. They should not exceed 1,000 words (double spaced)
in length, and may be subject to editing or abridgment.

Streptokinase in the Treatment of an Acute Cerebral Embolus—A Case Report

Richard J. Frink, M.D.

and

Louis H. Ostrach, Ph.D.

SACRAMENTO, CALIFORNIA

Abstract

During cerebral angiographic examination of a sixty-five-year-old white male, an acute right hemiplegia resulting from embolic occlusion of the left middle cerebral artery developed. Intravenous streptokinase therapy was initiated within forty-five minutes of symptom onset and the hemiplegia cleared in approximately one hour with no evidence of intracranial hemorrhage. This observation underscores the applicability and potential benefits of immediate intravenous thrombolytic therapy for selected patients presenting with acute cerebral thrombosis or embolism.

Case Report

A sixty-five-year-old right-handed white male diabetic was admitted to the hospital complaining of transient recurring left-sided hemiparesis including the face. The first episode had occurred two and a half months before admission. During the three days prior to admission the left hemiparesis recurred and cleared at frequent intervals. At the time of admission the patient was asymptomatic with a temperature of 97.3°F, blood pressure of 110/80, and pulse of 88.

Findings from physical and neurologic examinations were within normal limits. Carotid pulses were palpable and strong and no bruits were detected. A computed tomographic (CT) scan of the brain, without contrast, showed a focal lucency in the right basal ganglia and lateral to the right lateral ventricle. This was compatible with a lacunar infarct of indeterminate age. No evidence of intracranial hemorrhage was found.

A carotid duplex scan showed irregular atherosclerotic plaques bilaterally at the bifurcation of the internal and external carotid arteries. An echocardiogram was within normal limits and

From the Heart Research Foundation, Sacramento, California

This work was supported by the Heart Research Foundation and Mercy General Hospital of Sacramento, Sacramento, California

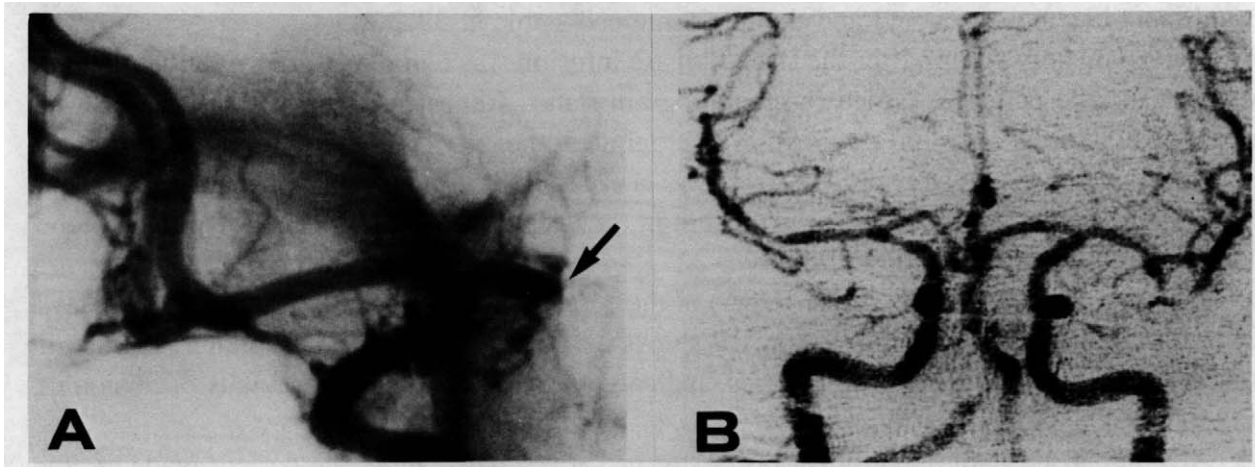


FIG. 1. A. Positive print of cerebral angiographic film. Left lateral view. Black arrow indicates the site of an acute embolic obstruction of the proximal left middle cerebral artery. B. Digital subtraction angiogram taken 4 days after high-dose, short-duration IV streptokinase therapy. Frontal view. Note bilateral simultaneous filling of anterior and middle cerebral arteries.

showed no evidence of mural thrombus in the left ventricle. An electrocardiogram demonstrated sinus tachycardia with mild nonspecific S-T wave changes. Cardiac enzymes were within normal limits. No acute disease was detectable on chest x-ray films.

Because of the frequency of the transient ischemic attacks and the absence of intracranial bleeding on the CT scan, the patient was placed on continuous intravenous heparin (3000 unit bolus, 25,000 units in 250 cc D5W at 10 drops/min; PTT kept at 33-49 sec, PTT ratio kept at 1.4-2.0; Hgb = 14.2 grams, Htc = 41.6%) for five days while awaiting angiography. The likely cause of the attacks was felt to be recurrent cerebral embolism from a carotid artery source.

A cerebral angiogram was performed five days after admission, the right common carotid being injected first. This was uneventful and showed an ulcerated plaque with 70% narrowing of the right internal carotid artery. The catheter was then placed without difficulty in the left common carotid artery. After flushing of the catheter, a hand-injected test dose was performed and no complications were encountered. However, immediately following the machine injection of the left common carotid artery, the patient became unresponsive and developed a right hemiplegia. The left side was unchanged from preangiogram status. Respiration, blood pressure, and pulse were normal. Prompt return of blood was present on catheter withdrawal. The procedure was terminated and the patient taken to the emergency room.

Review of angiographic films showed mild stenosis at the bifurcation of the left internal carotid artery with an ulcerated plaque. Figure 1A shows the abrupt cutoff of the left middle cerebral artery. The presumptive diagnosis was embolic occlusion of the left middle cerebral artery caused by dislodged thrombotic material from the ulcerated plaque. Air embolism associated with the machine injection of contrast material or a catheter source thrombus were alternative, though less likely, possibilities.

Within forty-five minutes of the onset of the right hemiplegia, 750,000 IU of streptokinase was infused intravenously over ten minutes. A second dose of 750,000 IU (in 100 cc D5W) was given over the next hour. A clotting panel taken before the streptokinase infusion showed all values to be well within normal limits. A postinfusion clotting panel was not performed; no

significant bleeding occurred and the Htc remained stable at 39.2%.

Approximately 1 hour after the streptokinase infusion was completed, the right hemiplegia cleared and the patient returned to preangiogram status. Repeat neurologic examination was negative. Heparin infusion as above was continued and blood values remained within the normal range. Repeat CT brain scan two days later showed no evidence of intracranial hemorrhage. A new low-density focus was present in the deep white matter of the left parietal lobe suggesting a small recent infarction.

Digital subtraction angiography (DSA) of the cerebral circulation was performed four days after the streptokinase infusion. Figure 1B shows the observed simultaneous bilateral filling of the anterior and middle cerebral arteries, indicating a resolution of the previous occlusion of the left middle cerebral artery.

A right carotid endarterectomy was performed seven days later. The patient made an uneventful recovery and was discharged. No further episodes of hemiparesis occurred. Repeat DSAs were performed on two occasions and no restenosis at the operative site was found. No further transient ischemic attacks have occurred over the ensuing year; the patient has normal results from neurologic examination and lives normally.

Discussion

Recently, the use of low-dose intraarterial infusion of thrombolytic agents in cases of acute thrombosis has received much attention.¹ These procedures have become increasingly efficacious in situations where sufficient time, expertise, and facilities are available. Even so, pharmaceutical thrombolysis in the cerebral circulation has remained somewhat limited since the anticipated risk of intracranial hemorrhage has prevented its application except in extreme cases such as brainstem stroke² or carotid occlusion.^{3,4} Mindful of these limitations, however, the clinician is occasionally confronted with an acute event that requires prompt action in order to prevent catastrophic damage to neural tissue. The application of routine cardiovascular therapy, namely, immediate high-dose, short-duration intravenous streptokinase, in carefully selected patients with acute cerebral embolus may improve the outlook for these patients.

Thrombolysis in selected patients presenting with acute myocardial infarction is often achieved with intravenous streptokinase provided that therapy can begin less than four to six hours after the onset of chest pain.⁵ A high-dose, short-duration infusion is routinely used without serious complications. Similar results are being obtained with intravenous tissue plasminogen activator.⁶ These types of early treatment might be applicable for the treatment of acute stroke patients since they can be more widely applied than intraarterial methods.

Early reports on intravenous cerebral thrombolysis, such as that by Clarke and Clifton,⁷ demonstrated the promise of this technique. The safety of its application has recently been addressed in an analysis of reported series of cases⁸ and recent reviews of thrombolytic therapy in stroke.^{9,10} These reports outline significant questions pertaining to previous assessments of potential risks. In particular, some or all of the following may have contributed to an overestimation of the risks of applying this method in selected cases: (1) lack of CT scanning and angiographic data, (2) late treatment, (3) large doses infused over long periods.

In their discussion of the incidence of parenchymatous hemorrhage (hematoma) and hemorrhagic infarction associated with atherothrombotic stroke, del Zoppo et al⁸ note that no study

has yet determined the clinical importance of the difference between these two complications. If the clinical significance of hemorrhagic infarction is relatively minor, as they suggest, its occurrence following thrombolytic therapy may not represent a serious complication unless intracerebral hematomas develop subsequently. Clearly, more data are needed to determine the incidence and sequelae of thrombolytically induced intracranial hemorrhage infarction.

Conclusions

In the present case, we cannot rule out the unlikely possibilities that spontaneous recanalization¹⁰ or resorption of an air embolus were responsible for the patient's return to preembolic status. However, the failure of the obstruction to resolve during the short transport and preparation time and the rapid resolution of the hemiplegia following streptokinase administration strongly suggest a direct effect of the treatment. A controlled trial involving immediate repeat DSAs, with and without streptokinase, will be necessary to determine the efficacy of this therapy. Furthermore, incorporation of the highly specific fibrinolytic agent tissue plasminogen activator into such a protocol could enhance the effectiveness of this reasonably simple technique. Thus, it is encouraging to see that systematic studies of the risks and benefits of intravenous thrombolytic therapy in cases of acute stroke^{11,12} are currently underway.

Acknowledgment

We are grateful to Mr. Ken Shiba for his preparation of the figure.

*Richard J. Frink, M.D.
Heart Research Foundation
3900 J Street
Sacramento, California 95819*

References

- Dotter C, Rosch J, Seaman A: Selective clot lysis with low dose streptokinase. *Radiology* 111:31-37, 1974.
- Nenci G, Gresele P, Taramelli M, et al: Thrombolytic therapy for thromboembolism of vertebrobasilar artery. *Angiology* 34:561-571, 1983.
- Zeumer H, Hundgen R, Ferbert E, et al: Local intraarterial fibrinolytic therapy in inaccessible internal carotid occlusion. *Neuroradiol* 26:315-317, 1984.
- del Zoppo GL, Ferbert A, Otis S, et al: Local intraarterial fibrinolytic therapy in acute carotid territory stroke. *Stroke* 19:307-313, 1988.
- Lo Y: Intravenous versus intracoronary streptokinase in acute myocardial infarction. *Clin Cardiol* 8:609-619, 1985.
- Carlson SE, Aldrich MS, Greenberg HS, et al: Intracerebral hemorrhage complicating intravenous tissue plasminogen activator treatment. *Arch Neurol* 45:1070-1073, 1988.
- Clarke RL, Clifton EE: The treatment of cerebrovascular thromboses and embolism with fibrinolytic agents. *Am J Cardiol* 6:546-551, 1960.
- del Zoppo G, Zeumer H, Harker L: Thrombolytic therapy in stroke: Possibilities and hazards. *Stroke* 17:595-607, 1986.
- Sloan M: Thrombolysis and stroke. *Arch Neurol* 44:748-768, 1987.
- Taneda M, Shimada N, Tsuchiya T: Transient neurological deficits due to embolic occlusion and immediate reopening of the cerebral arteries. *Stroke* 16:522-524, 1985.
- Brott TG, Haley EC Jr, Levy DE, et al: Tissue plasminogen activator (tPA) as a very early therapy for cerebral infarction. *Circulation* 76(suppl IV):IV-142, 1987.
- del Zoppo GL, Pessin MS, Poeck K, et al: The t-PA Acute Stroke Study Group. An open multicenter study of the safety and efficacy of various doses of rt-PA in acute stroke: Interim results. *Fibrinolysis* 2(suppl 1):15, 1988.