

Homonymous Quadrantic Visual Field Defect Resulting from Vertebrobasilar Insufficiency: Report of a Case

Camilo R. Gomez, M.D., F.A.C.A.
Madhav H. Bhat, M.D.
and
Hyung D. Chung, M.D.*

ST. LOUIS, MISSOURI

Abstract

A patient showing a congruous homonymous superior quadrantanopsia was found at autopsy to have infarction of the striate cortex. The lesion involved the inferior bank of the calcarine fissure almost entirely and approximately one fifth of the superior bank. Additionally, infarctions of the visual association cortex and the pontine tegmentum were found. No lesions in the corresponding temporal lobe were present. Two types of visual field defects have been described in association with occipital lobe lesions: a monocular temporal crescentic defect if the lesion is anterior and a congruous homonymous hemianopsia if it is posterior. This patient seems to represent a variant of the latter. The most prominent difference with respect to quadrantanopsias resulting from lesions of the optic radiation is the high degree of congruity, especially in the central portion of the field. Association with nonocclusive vascular events related to vertebrobasilar hypoperfusion rather than embolization is also more common.

Introduction

The usual clinical interpretation of homonymous quadrantanopsias is that they represent lesions of the optic radiations that course through the parietal or temporal lobes. Superior homonymous defects are generally associated with temporal lobe lesions, whereas inferior defects commonly result from lesions of the parietal lobe. We present the case of a man who developed a relatively congruous superior homonymous quadrantanopsia and was found, at autopsy, to have extensive infarction of the inferior bank of the calcarine fissure with only

From the Stroke Resource Center, Department of Neurology, St. Louis University School of Medicine, St. Louis, Missouri

* From the Department of Pathology, St. Louis University School of Medicine, St. Louis, Missouri

minimal infarction of its superior bank. The lesions seem to have resulted from vertebrobasilar insufficiency. The latter was the consequence of dynamic changes in cerebral perfusion during cardiac arrhythmias in a vascular territory previously compromised by hypertension and atherosclerosis.

Case Report

This sixty-three-year-old man was admitted with complaints of intermittent numbness and weakness of the right side of his body lasting twenty to thirty minutes for two months prior to admission. These were accompanied by slurred speech, double vision, sometimes triple vision, and difficulty swallowing and maintaining balance. Palpitations were prominently felt by the patient in association to some of these events. He had a long-standing history of hypertension and chronic obstructive pulmonary disease. He smoked two packs of cigarettes per day and drank alcohol occasionally. His medications on admission were hydralazine, hydrochlorothiazide, and theophylline.

Physical examination showed a pulse of 100/minute; blood pressure 136/90 torr; and normal findings from cardiac and abdominal examinations. He had diffuse expiratory wheezes. He was awake, alert, and well oriented. His speech was fluent but slurred. Fundoscopic examination showed moderate hypertensive retinopathy. Visual field examination disclosed a congruous left homonymous superior quadrantanopsia (Fig. 1). He had spasticity of both lower limbs, but his overall strength was normal. Muscle stretch reflexes were increased in the lower limbs with clonus of both ankles. Plantar responses were flexor bilaterally. Gait was wide based, and he could not perform tandem walking. Results of the Romberg test were normal.

His laboratory data were unremarkable, but he had frequent premature ventricular contractions on his EKG. He was eventually discharged and readmitted three months later owing to cardiac decompensation; he showed clinical signs of myocardial ischemia. During his evaluation, the patient developed multiple episodes of ventricular fibrillation, which became refractory to treatment, until he died as the result of one of them. At autopsy, extensive infarction of the inferior bank of the calcarine fissure on the right side was found (Fig. 2). This was accompanied by loss of myelin in the subcortical region (Fig. 3). Partial infarction of the superior bank was also present (Fig. 2). No lesions were present in the temporal lobes. Superficial infarction of the visual association cortex and a localized infarction of the pontine tegmentum were evident too. Marked atherosclerotic plaques were noted in the vertebral arteries and basilar trunk. These produced approximately 60-65% stenosis of these vessels.

Discussion

The bulk of knowledge of the clinical effects of lesions of the visual pathways between the lateral geniculate body and the striate cortex is derived from cortical ablations in primates¹ and from the study of patients with penetrating head injuries,^{2,3} brain tumors,⁴ or cerebral infarctions.

The geniculocalcarine fibers project following a highly organized pattern.^{2,5} The fibers ending in the superior bank of the calcarine fissure travel through the upper part of the radiation (parietal lobe), and the ones ending in the inferior bank travel through the temporal lobe, where they form the so-called "Meyer's Loop." A lesion of the latter part of this projection

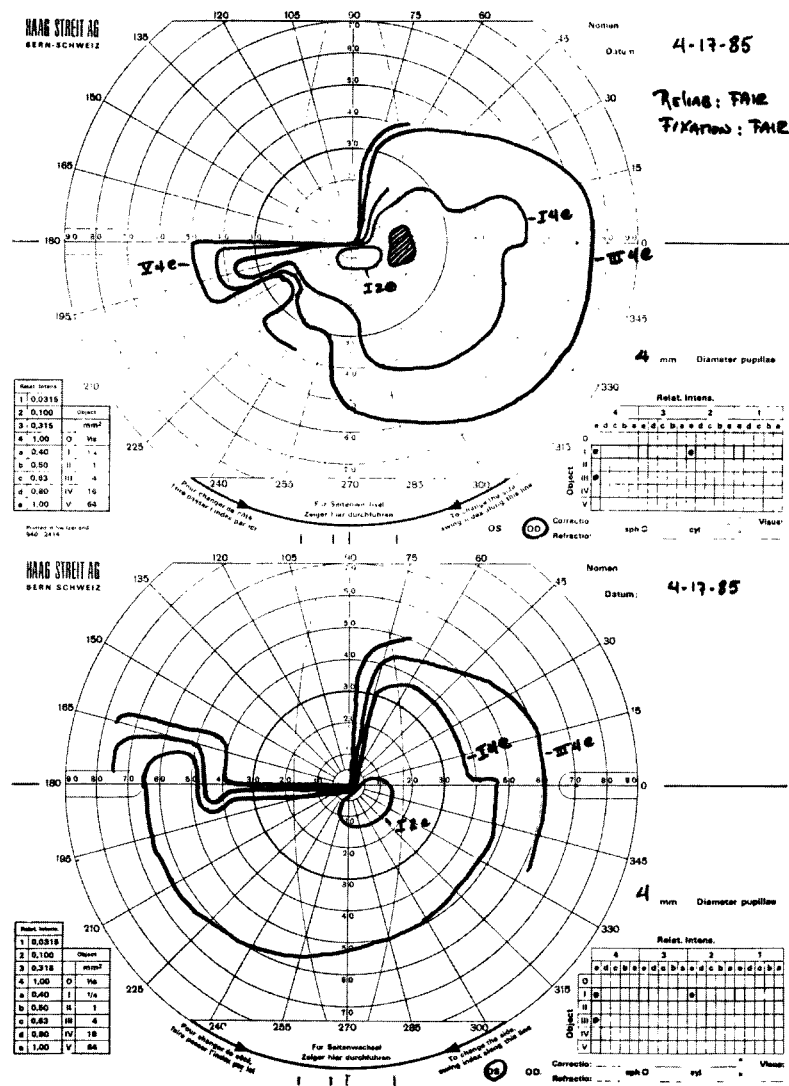


FIG. 1. Visual fields plotted by use of a Goldman perimeter. The field defect is highly congruous with the exception of the most extreme portion of the temporal field. (Top = right eye; bottom = left eye).

system anywhere in its course will produce a superior homonymous quadrantanopsia.^{2,3,6} If a lesion is located in the temporal lobe itself, the visual field defect usually has a sloping inferior margin, it does not affect visual acuity or the size of the blind spot, it may cross the horizontal midline, and it is incongruous.^{7,8} If, on the other hand, the lesion is in the occipital lobe, the shape of the visual field defect will depend on which part of the striate cortex is affected. Lesions located anteriorly give rise to a monocular extreme temporal crescentic field defect that has been referred to as the “temporal half-moon.”^{1,9-11} The fibers involved in this defect represent the end-projection from the unpaired retinal peripheral nasal fibers. More posterior lesions of the primary visual cortex produce exclusively homonymous defects, usually hemianopsic, which are exquisitely congruous.³ In these cases, the phenomenon of sparing of the macula is often, although not always, seen.

Diagnostic localization of an ischemic lesion producing a homonymous quadrantanopsia not only represents an exercise in neurovascular anatomy but also forms the basis for a rational approach to the etiopathogenic mechanism responsible for the cerebral infarction and, conse-

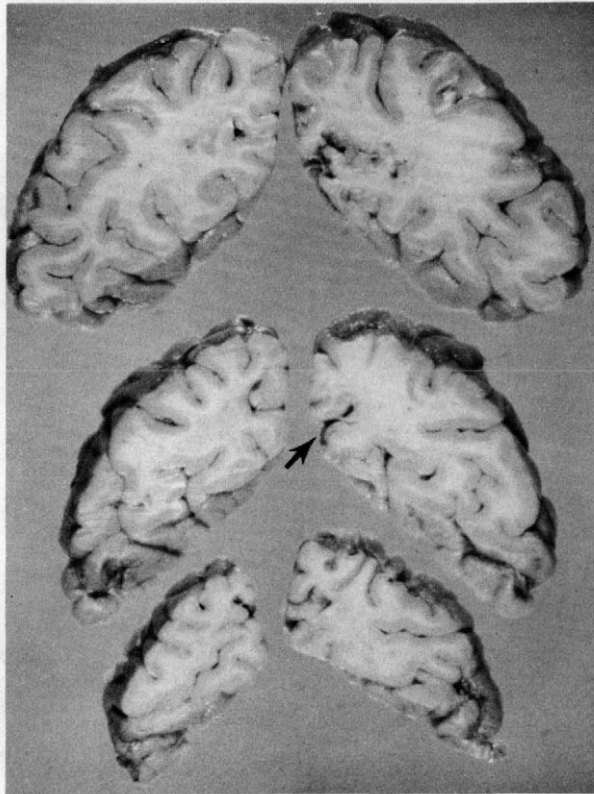


FIG. 2. Macroscopic specimen of the occipital lobes showing the infarction. The area from where the microscopic section was taken is marked with an arrow.

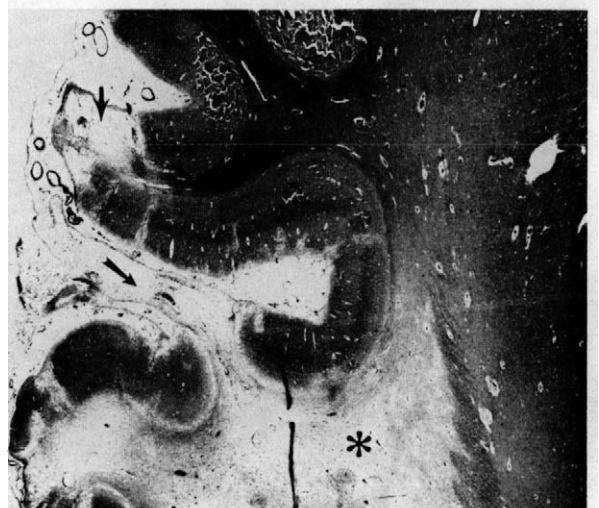

FIG. 3. Section of the calcarine fissure shows prominent infarction of the inferior bank (long arrow) and only minimal affection of the superior bank (short arrow). Subcortical loss of myelin produces conspicuous pallor around the area of infarction(*).

quently, its management. In a study of 104 cases of isolated anopsias,¹² Trobe et al found that 86% of the cases were due to infarction in the posterior cerebral artery territory. Of these, only 16% had homonymous quadrantanopsias. Unfortunately, no correlation with the location of the lesions producing the quadrantic defects was established.

The blood supply to the superior portion of the optic radiation is primarily from branches of the middle cerebral artery. The inferior portion is, however, supplied by the posterior cerebral artery.¹³ The striate cortex has a dual supply, particularly the occipital pole. The middle cerebral artery provides its occipital branches while the posterior cerebral artery provides the parietooccipital, calcarine, and posterior temporal branches.^{5,14,15} The latter three are located at the most distal point of the vertebrobasilar system. Their collateral circulation is provided by leptomeningeal anastomoses, small vessels which are characteristically damaged by hypertension. Occlusion of any of these vessels, especially the branches of the posterior cerebral artery, may be followed by infarction of the striate cortex and development of a highly congruous homonymous hemianopsia. In our patient, however, the infarctions were distributed in a "patchy" pattern and probably resulted from a critically compromised collateral flow in association with vertebrobasilar hypoperfusion secondary to systemic hypotension. Relative sparing of the anterosuperior part of the striate cortex seems to be the reason for the presence of vision in the lower quadrants and the peripheral temporal crescent.

Conclusions

The importance of vertebrobasilar insufficiency's being a potential cause of homonymous quadrantanopsias is its association with ischemia resulting from nonocclusive vascular phenomena such as hemodynamic crisis.¹⁶⁻¹⁸ The presence of other signs of brainstem ischemia (eg, vertigo, double vision) and the congruity of the visual field defect (especially of its central portion) are consistent with changes in perfusion pressure through the posterior circulation as the primary cause of the neurologic event. Decreased cardiac output secondary to cardiac tachyarrhythmias or bradyarrhythmias is a common cause of this problem. In the case of our patient, perfusion changes associated with episodes of ventricular fibrillation probably due to silent myocardial ischemia seem to have been the precipitating events. Previous compromise of the vertebrobasilar circulation by atherosclerosis and hypertension, with reduction of collateral capacity, appears to have been the predisposing factor to symptom formation.

Acknowledgment

The authors wish to thank Mrs. Mary Althage for her assistance in the preparation of the manuscript.

Camilo R. Gomez, M.D., F.A.C.A.
The Stroke Resource Center
Department of Neurology
St. Louis University Medical Center
3660 Vista Avenue, Suite 303
St. Louis, MO 63110

References

1. Polyak S: The main afferent systems of the cerebral cortex in primates, Vol. 2. Berkeley: University of California Press, 1932, pp 1-300.
2. Spalding JMK: Wounds of the visual pathway. Part I: The optic radiation. *J Neurol Neurosurg Psychiatry* 15:99-109, 1953.
3. Spalding JMK: Wounds of the visual pathway. Part II: The striate cortex. *J Neurol Neurosurg Psychiatry* 15:169-183, 1953.
4. Bender MB, Strauss L: Defects in visual field of one eye only in patients with a lesion of optic radiation. *Arch Ophthalmol* 17:765-787, 1948.
5. Polyak S: *The Vertebrate Visual System*, ed. by Klover H. Chicago: University of Chicago Press, 1957.
6. Falconer MA, Wilson JL: Visual field changes following anterior, temporal lobectomy, their significance in relation to "Meyer's loop" of the optic radiation. *Brain* 81:1-14, 1958.
7. Van Buren JM, Balwin M: The architecture of the optic radiation in the temporal lobe of man. *Brain* 81:15-40, 1958.
8. Marino R Jr, Rasmussen T: Visual field changes after temporal lobectomy in man. *Neurology* 18:825-835, 1968.
9. Kronfeld T: The temporal half-moon. *Trans Am Ophthalmol Soc* 30:431-456, 1932.
10. Ask-Upmark E: On the cortical projection of the temporal half-moon of the visual field. *Acta Ophthalmol* 10:271-290, 1932.
11. Walsh TJ: Temporal crescent or half-moon syndrome. *Ann Ophthalmol* 6:501-505, 1974.
12. Trobe JD, Lorber ML, Schlezinger NS: Isolated homonymous hemianopsia: A review of 104 cases. *Arch Ophthalmol* 89:377-381, 1973.
13. Miller NR: *Clinical Neuro-ophthalmology*, ed. 4. Baltimore: Williams and Wilkins, p 106.
14. Smith CG, Richardson WFG: The course and distribution of the arteries supplying the visual (striate) cortex. *Am J Ophthalmol* 61:1391-1396, 1966.
15. Hoyt WF, Margolis MT: Arterial supply of the striate cortex: Angiographic changes with occlusion of the posterior cerebral artery. *Excerpta Med Int Congr*, 1970, pp 1323-1332.
16. Hutchinson EC, Yates PO: Carotid-vertebral stenosis. *Lancet* i:2-8, 1957.
17. Shanbrom E, Levy L: The role of systemic blood pressure in cerebral circulation in carotid and basilar artery thrombosis. *Am J Med* 24:197-204, 1957.
18. Meyer JS, Sheehan S, Bauer R: An arteriographic study of cerebrovascular disease in man. *Arch Neurol* 2:27-45, 1960.