

Asymptomatic neurocysticercosis over 15 years between transitory ischemic attack as initial and epilepsy as second manifestation

Josef Finsterer · Herbert Auer

Received: 7 June 2012 / Accepted: 29 September 2012 / Published online: 11 October 2012
© Belgian Neurological Society 2012

Neurocysticercosis (NCC) is a CNS parasitosis, which is non-progressive in case of intra-parenchymal lesions, but progressive in case of extra-parenchymal lesions [1]. Intra-parenchymal NCC is frequently associated with epilepsy and extra-parenchymal NCC with intracranial hypertension. Persistence of viable cysts over the years is not rare, but infrequently reported. Here, we present a patient with non-progressive NCC who developed epilepsy 15 years after the diagnosis of NCC.

A previously healthy Romanian female experienced recurrent episodes of right-sided hemihypesthesia and headache at age 40 years. Based on the clinical presentation, serological testing, and cerebral MRI which showed an enhancing right parieto-occipital and a left parietal nodular lesion with perilesional edema, NCC was diagnosed. After praziquantel (1,800 mg for 2 weeks), she became symptom free. At age 55 years (15 years later), she experienced a first tonic-clonic seizure followed by transient right-sided hemiparesis. Serum IgG antibodies against *Taenia solium* were positive on Western blot and 7.12 ($n < 1.1$) on an ELISA. Detailed descriptions of the methods used for the ELISA and the Western blot, however, were not provided in the written reports. Carbamazepine (400 mg/day) was given and, since seizure activity was attributed to exacerbation of the parasitological infection, she also received albendazol (800 mg/day) for

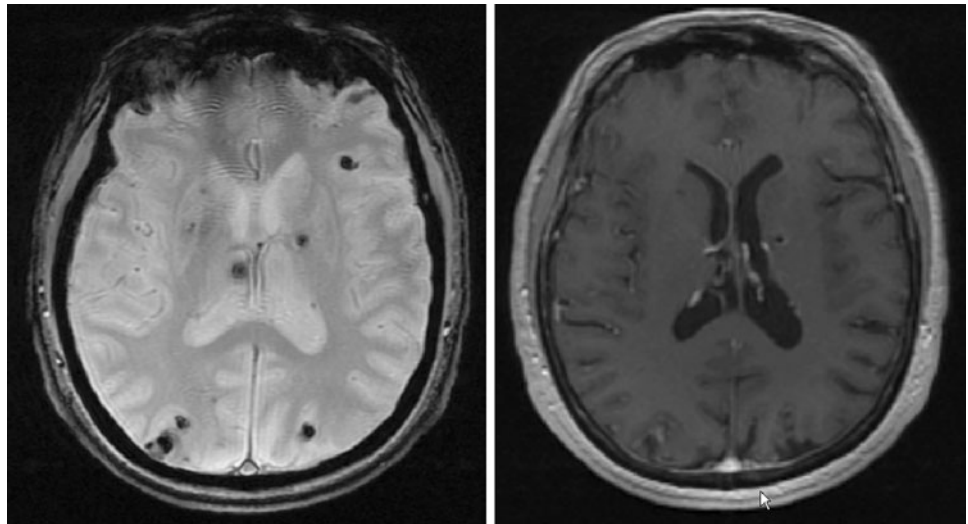
4 weeks and erythromycin (500 mg/day) 3 day/week for 3 weeks. One month after starting carbamazepine, it was replaced by valproic acid (1,000 mg/day) because of recurrent focal seizures of the right arm. Since focal seizures recurred 2 months later, she received praziquantel (1,800 mg/day) for 3 weeks. One month later, albendazole (800 mg/day) was given for 3 weeks followed by a second cycle 3 months later. Seven months after the first tonic-clonic seizure, she experienced a second one. IgG antibodies against *Taenia solium* were 3.11 ($n < 1.1$) on an ELISA. Cerebral MRI showed multiple supra-tentorial, intra-parenchymatous, calcified lesions, which did not show perilesional edema (Fig. 1). Additionally, two enhancing nodular lesions, one in the right parieto-occipital region and the other in a left high parietal location, were found. Carbamazepine (400 mg/day) was added to valproic acid (1,000 mg/day). Though she did not follow the advice to stepwise increase carbamazepine to 900 mg/day, she remained seizure free during the next 2 years until today.

The presented case is interesting for several aspects. First, the patient is from Romania where NCC is endemic and has a higher prevalence than in Western Europe [2]. Whether the lower prevalence in Western Europe is due to a higher standard of hygiene or due to under-diagnosing the condition remains speculative, but with intensified migration the prevalence of NCC will increase also here. Second, NCC initially manifested as headache and transitory ischemic attack (TIA), and remained subclinical during the next 15 years. TIA as the initial manifestation of NCC could be explained with arteritis predominantly occurring with subarachnoid cysts [1]. However, the patient did not show subarachnoid lesions on MRI. Alternatively, TIA occurred independently of NCC due to atherosclerosis (the patient's risk factors were arterial hypertension and smoking), or was a non-convulsive partial seizure. Though

J. Finsterer (✉)
Krankenanstalt Rudolfstiftung,
Postfach 20, 1180 Vienna, Austria
e-mail: fipaps@yahoo.de

H. Auer
Department of Medical Parasitology, Institute of Specific
Prophylaxis and Tropical Medicine, Medical University Vienna,
Vienna, Austria

Fig. 1 MRI of the cerebrum. T2*-weighted images showing multiple supra-tentorial, intraparenchymatous, calcified lesions without perilesional edema (*left panel*). Only two of the lesions were slightly enhanced on T1-weighted images with contrast medium (*right panel*)



asymptomatic cases of NCC have been described [3], they did not remain asymptomatic over such a long period. Silent NCC over 15 years could be explained by the strong immune competence of the patient or effective treatment with praziquantel at the onset 15 years ago. Whether the appearance of epilepsy after 15 years of “silence” was due to reinfection with *T. solium* remains speculative, but in case reinfection had occurred the new treatment with albendazole was effective. Results of stool antigen testing for *Taenia* to rule out autoinfection with shed eggs in stool were not available. Third, albendazole has been administered in Romania without steroids. Steroids have been shown to increase the antihelminthic effect of albendazole by up to 50 % [4]. On the contrary, steroids diminish the antihelminthic effect of praziquantel. The alternating administration of albendazole and praziquantel was also unusual. Today, albendazole with steroids is preferred over praziquantel [5]. Fourth, epilepsy disappeared after combining low-dose valproic acid with low-dose carbamazepine. That seizures were induced by praziquantel is rather unlikely, since the first antihelminthic drug administered after the seizure was albendazole. More likely, seizures were induced by one of the enhancing lesions, representing the vesicular colloidal stages of cyst involution [1]. Seizures could have also been triggered by perilesional edema around a dying larvae, but perilesional edema was absent in the presented patient. Since perilesional edema is found in only 25–33 % of NCC, but epilepsy reported in 50–75 % [6], other triggers are assumed. One of them could be toxins secreted from the involuting cysts, which could kindle seizure activity. An argument against the assumption that seizure activity is related to the stage of larva involution is that there is no difference in the proportion of cyst stages between symptomatic and asymptomatic NCC

patients [7]. It is also conceivable that a calcified, inactive lesion is the only culprit of epilepsy, making several rounds of antiparasitics useless.

This case shows that NCC may initially manifest as TIA and remain asymptomatic thereafter for a long period of time. Recurrence of symptomatic NCC may be attributable to reactivation of the cysts or reinfection.

Conflict of interest None.

References

1. Coyle CM, Tanowitz HB (2009) Diagnosis and treatment of neurocysticercosis. *Interdiscip Perspect Infect Dis* 2009:180742
2. Carangelo B, Erra S, Del Basso De Caro ML, Bucciero A, Vizioli L, Panagiotopoulos K, Cerillo A (2001) Neurocysticercosis. Case report. *J Neurosurg Sci* 45:43–46
3. Alexander AM, Prabhakaran V, Rajshekhara V, Muliylil J, Dorny P (2010) Long-term clinical evaluation of asymptomatic subjects positive for circulating *Taenia solium* antigens. *Trans R Soc Trop Med Hyg* 104:809–810
4. Jung H, Hurtado M, Tulio M, Sanchez M, Sotelo J (1990) Dexamethasone increases plasma levels of albendazole. *J Neurology* 237:279–280
5. Garcia H, Lescano A, Lanchote V et al (2011) Pharmacokinetics of combined treatment with praziquantel and albendazole in neurocysticercosis. *Br J Clin Pharmacol*. doi:10.1111/j.1365-2125.2011.03945.x
6. Nash TE, Pretell EJ, Lescano AG, Bustos JA, Gilman RH, Gonzalez AE, Garcia HH, Cysticercosis Working Group in Peru (2008) Perilesional brain oedema and seizure activity in patients with calcified neurocysticercosis: a prospective cohort and nested case–control study. *Lancet Neurol* 7:1099–1105
7. Prasad A, Gupta RK, Pradhan S, Tripathi M, Pandey CM, Prasad KN (2008) What triggers seizures in neurocysticercosis? A MRI-based study in pig farming community from a district of North India. *Parasitol Int* 57:166–171