

Foix–Chavany–Marie syndrome due to cerebral infarctions with relatively good recovery

Sibel Karaca · Başak Karakurum Göksel ·
Meliha Tan · Özlem Alkan

Received: 9 June 2012 / Accepted: 5 October 2012 / Published online: 19 October 2012
© Springer-Verlag Italia 2012

Introduction

Foix–Chavany–Marie syndrome (FCMS) is seen in patients with ‘bilateral anterior operculum’ lesions. The anterior part of the operculum includes motor centers of cranial nerves 5, 7, 9, 10, and 12. FCMS is cortico-subcortical type of suprabulbar or pseudobulbar palsy of these lower cranial nerves. The preservation of emotional expression in FCM syndrome is explained by activation of the cranial muscles by pathways arising from outside the primary motor cortex [1, 2].

FCMS is usually associated with secondary cerebrovascular accidents (CVA) affecting the bilateral opercular regions as a result of subsequent strokes. Unilateral vascular lesions or simultaneous bilateral infarcts may rarely cause FCM. FCM has also been reported to be due to CVA, and much less frequently, due to central nervous system infections, neurodegenerative disorders, or brain tumors [3, 4].

We report two FCMS patients’ clinical and imaging findings and relatively good prognosis contrary to the literature.

Case I

An 85-year-old, right-handed woman presented with right hemiparesia to our department. The patient had sudden onset of inability to speak and dysphagia, and bilateral facial weakness. She also suffered weakness of the right arm and leg. Her medical history revealed hypertension, for which she was receiving antihypertensive treatment, and osteoporosis. Initial neurological examination revealed that the patient was alert but anarthric; the palatoglossal arches were down, and the gag reflexes were hypoactive with normal tongue movements; there was facial diplegia which improved during laughing, crying, and yawning with slight right hemiparesia (4/5). The patient was able to write down her history using her left hand due to right hemiparesia. There was no deficiency in comprehension, naming, or writing and reading skills. When she was asked to whistle, puff, and blow a kiss, she could not. However, she was able to laugh or cry in appropriate conditions. Her facial expression was in a state of a pseudo-peripheral facial paresis, with involvement of both the lower and upper face to the extent that the affected area appeared immobile.

Cranial magnetic resonance imaging (MRI) showed acute ischemic lesions in the perirolandic areas bilaterally and anterior operculum on the left side [Fig. 1].

On the 2nd day, the patient had respiration problem probably due to aspiration. It might have been related to palatal weakness. Chest X-ray was normal. There was no need for intubation or mechanical ventilation, and the breathing problems resolved on the 3rd day. From the 4th day to the day of discharge (6th day), she showed fast neurological improvement and oral feeding was started. Hemiparesia resolved but pseudo-peripheral facial paresis and speech disturbance continued. The results of the carotid vertebral artery duplex sonography, and carotid and

S. Karaca · B. K. Göksel (✉) · M. Tan
Department of Neurology, Adana Teaching and Medical
Research Center, Baskent University Medical School,
Dadaloglu Mah. 39. sokak. No: 6, 01250 Adana, Turkey
e-mail: bkarakurum@hotmail.com

Ö. Alkan
Department of Radiology, Adana Teaching and Medical
Research Center, Baskent University Medical School,
Dadaloglu Mah. 39. sokak. No: 6, 01250 Adana, Turkey

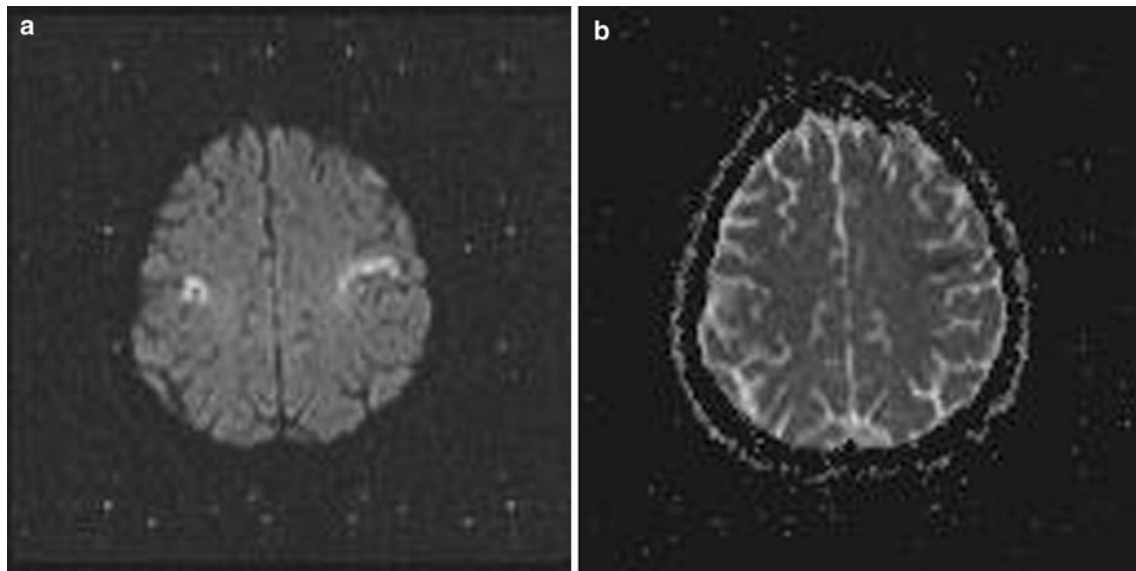


Fig. 1 Diffusion-weighted magnetic resonance images of case I show acute infarctions in bilateral perirolandic areas and the left anterior operculum

cerebral MR angiograms were also normal. Electrocardiogram and echocardiography investigations were normal. The results of the Holter electrocardiogram showed maximum 19-beat supraventricular tachycardia at ten times during a day.

Two months later, on neurological examination, dysarthria and brisk deep tendon reflex on the right side were noted. Her swallowing problem completely resolved. Her facial diplegia was improved except for slight right central paralysis. Five years later, on neurological examination, she had only dysarthria and brisk deep tendon reflex on the right side.

Case II

A 77-year-old man presented with sudden onset of speech disturbance and dysphagia. The patient was unable to speak or perform voluntary facial and tongue movements. In addition, he had mild weakness of the right arm and leg. His past medical history revealed a coronary artery disease and a cerebral infarct 10 years previously. Although the patient and relatives did not provide a detailed history of the past stroke clinical finding, there seemed to be no neurological sequel after this CVA. Neurological examination showed anarthria, facial diplegia, diminished gag reflex, and depressed tongue movements with slight right hemiparesia. ‘Automatic voluntary dissociation’ was observed with preserved crying and smiling abilities in appropriate conditions. However, there was no voluntary control over the muscles of the face, jaw, pharynx, and/or tongue. The patient was fed through a nasogastric tube for about 1 month.

Cranial MRI was performed on the second day using stroke protocol. An acute infarction on the opercular segment of the right frontal lobe [Fig. 2] was reported. Stroke investigation results were as follows: 70 % stenosis in the left internal carotid artery on MR carotid angiography, and two-fourth failure in the mitral and tricuspid valves with pulmonary hypertension and biatrial dilatation were recorded on transthoracic echocardiogram.

Two months later, neurological examination revealed that his speech was markedly improved. He was able to walk independently and his dysphagia resolved.

Discussion

We present two cases of FCMS. Our first case had acute simultaneous bilateral anterior opercular isolated infarct. The second patient had chronic infarct which involved the anterior opercular region and acute opercular infarct. Sequential infarcts to the bilateral anterior opercular or subcortical insular regions are the most commonly described causes as in our second case.

Although it has been known that FCMS usually occurs due to bilateral opercular involvement, acute bilateral simultaneous cerebral infarcts are rarely reported in these patients. Usually, unilateral acute infarcts follow a previous contralateral stroke, while bilateral acute infarcts are seen in 1–6 % of stroke patients [5, 6].

The clinical findings of FCM, also known as facio-labio-pharyngo-glosso-laryngo-brachial paralysis or the cortical type of pseudobulbar paralysis, mimic the other pseudobulbar palsy syndromes, especially brainstem lesions.

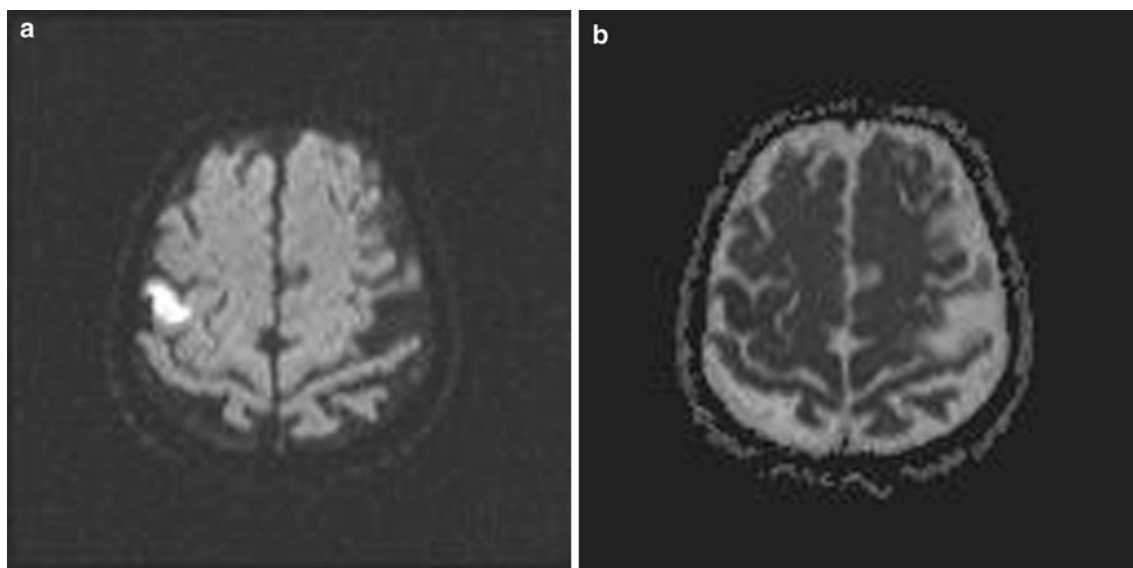


Fig. 2 Diffusion-weighted magnetic resonance images of case II show acute infarction on the opercular segment of the right frontal lobe

FCM patients lose voluntary control of their facial, pharyngeal and lingual abilities, and mastication, while preserving emotional and automatic functions of these muscles. However, oral–buccal apraxia patients experience more difficulty in realizing more complex tasks. In bulbar palsy, lack of both voluntary and automatic movement is observed. MRI is useful for the differential diagnosis of these conditions. Moreover, FMC has a relatively better prognosis than other pseudobulbar paralyses. Although pseudobulbar palsy is associated with emotional lability and an increased gag reflex, in FMC the gag reflex is often absent [6, 7].

Although it has been known that prognosis of FCMS is very limited and clinic deficit is permanent in the majority of these patients, prognosis of the patients was good, which is contrary to the literature. Speech, dysphagia, and facial palsy were markedly improved in both patients. Likewise, some patients with good prognosis were also reported in the literature [2, 3, 8].

In conclusion, we suggest that FCMS does not usually have a poor prognosis and clinic deficits may improve in some of these patients.

References

1. Weller M (1993) Anterior opercular cortex lesions cause dissociated lower cranial nerve palsies and anarthria but no aphasia. *J Neurol* 240:199–298
2. Mao CC, Coull BM, Golper LC et al (1989) Anterior opercular syndrome. *Neurology* 39:1169–1172
3. Uttner I, Brettschneider J, Unrath A et al (2012) Slowly progressive FCM syndrome as a precursor of a primary progressive aphasia. *J Clin Neurosci* 19(5):765–767
4. McGrath NM, Anderson NE, Hope JK et al (1997) Anterior opercular syndrome, caused by herpes simplex encephalitis. *Neurology* 49(2):494–497
5. Bursaw A, Duginski T (2011) Anterior opercular syndrome caused by acute, simultaneous, isolated bilateral infarcts. *Arch Neurol* 68(2):254–255
6. Nowak DA, Griebel G, Dabitz R et al (2010) Bilateral anterior opercular syndrome. *J Clin Neurosci* 17(11):1441–1442
7. Sim LS, Guberman A, Hogan MJ (2005) Acute bilateral opercular strokes causing loss of emotional facial movements. *Can J Neurol Sci* 32:119–121
8. Sacco S, Sara M, Pistoia F et al (2008) Management of pathological laughter and crying in patients with locked-in syndrome. *Arch Phys Med Rehabil* 89(4):775–778