

Dermatomal Sensory Manifestations in Lateral Medullary Infarction

Hiroki Hongo, MD,* Yasutaka Tanaka, MD, PhD,† Yoshiaki Shimada, MD,*
Ryota Tanaka, MD, PhD,* Nobutaka Hattori, MD, PhD,* and Takao Urabe, MD, PhD†

A 61-year-old man who experienced a sudden onset of unstable gait followed by nuchal pain was admitted to our department. The neurologic examination revealed right-sided limb ataxia, right partial ptosis, and decreased sensation to 50% of the normal side to pinprick and temperature stimuli on the left side below the level of the T-6 dermatome. A lateral medullary infarction caused by spontaneous vertebral artery dissection was diagnosed by magnetic resonance imaging and computed tomography angiography. In conclusion, lateral medullary infarction is an important entity to consider in the differential diagnosis of dermatomal sensory manifestations. **Key Words:** Dermatomal sensory manifestation—lateral medullary infarction.

© 2014 by National Stroke Association

A 61-year-old man with sudden onset of unstable gait followed by nuchal pain was admitted to our department. He had a history of poorly controlled dyslipidemia and was previously a smoker. He had no history of major trauma to the neck. The neurologic examination revealed right-sided limb ataxia, right partial ptosis, and decreased sensation to 50% of the normal side to pinprick and temperature stimuli on the left side below the level of the T-6 dermatome (Fig 1A).

Blood test results were normal except for a slight elevation of triglyceride and γ -glutamyl transpeptidase levels. Diffusion-weighted magnetic resonance imaging (MRI)

revealed a right lower lateral medullary infarction (LM; Fig 1B). Computed tomography (CT) angiography revealed a string and pearl sign in the right vertebral artery. A cervical and thoracic MRI was normal. The final diagnosis was LMI caused by spontaneous vertebral artery dissection.

Discussion

The typical case of lateral medullary syndrome, which is characterized by a superficial sensory deficit in the ipsilateral face and contralateral body, ipsilateral Horner syndrome, cerebellar ataxia, dysarthria, and dysphagia, is known as Wallenberg syndrome.¹ However, a patient with LMI who presents with all features of typical Wallenberg syndrome is uncommon. Because the present case was characterized by restricted contralateral sensory loss below the level of the T-6 dermatome without trigeminal sensory dysfunction, spinal cord involvement was initially suspected.

This dermatomal sensory loss can be explained by the site of the lesion and the topographic arrangement of sensory fibers in the spinothalamic tract of the lower

From the *Departments of Neurology at Juntendo University School of Medicine; and †Juntendo University Urayasu Hospital, Chiba, Japan.

Received August 10, 2012; revision received September 13, 2012; accepted September 18, 2012.

Address correspondence to Yasutaka Tanaka, MD, PhD, Department of Neurology, Juntendo University Urayasu Hospital, Tomioka, 2-1-1, Urayasu city, Chiba, Japan. E-mail: 8123a@juntendo.ac.jp.

1052-3057/\$ - see front matter

© 2014 by National Stroke Association

<http://dx.doi.org/10.1016/j.jstrokecerebrovasdis.2012.09.011>

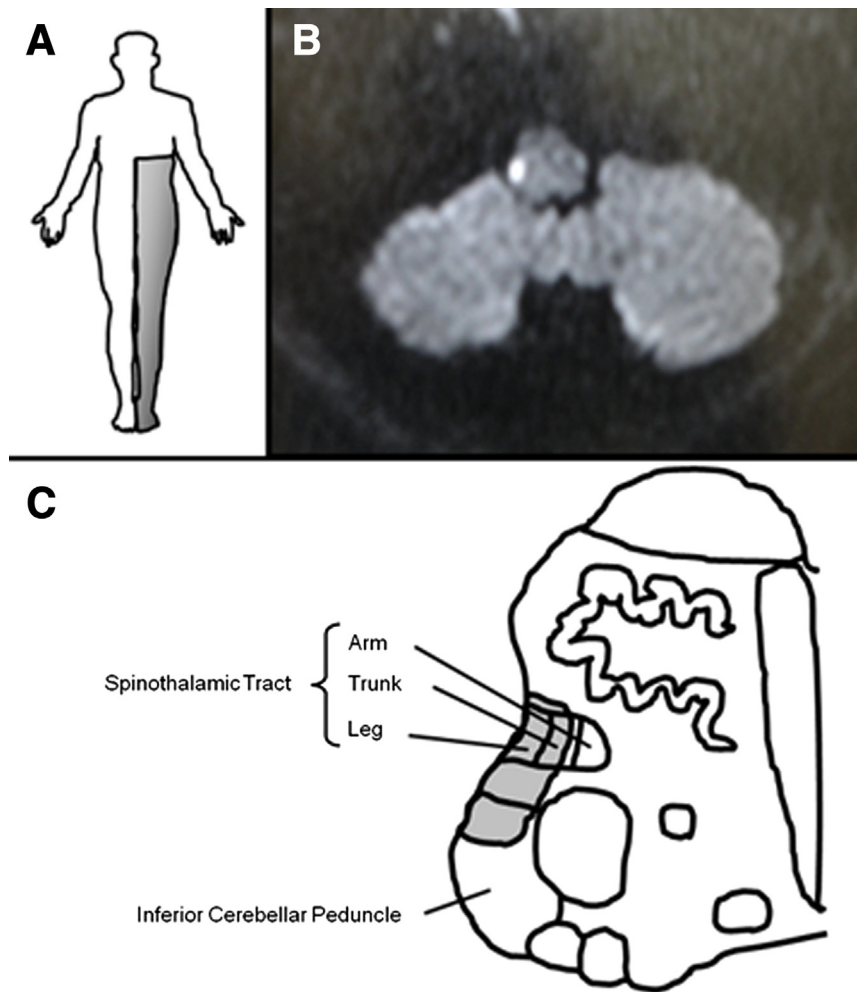


Figure 1. (A) Representation of the patient's superficial sensory deficit (shaded area). (B) Diffusion-weighted magnetic resonance imaging scan reveals a small infarct in the right lateral medulla oblongata. (C) Schematic drawing of important medullary structures (right unilateral). Shaded area indicates the infarct area.

medulla oblongata.^{2,3} The sensations from the sacral area, leg, trunk, and arm are somatotopically arranged in an orderly fashion from the superficial to the medial direction. In the present case, the ischemic lesion was thought to involve the quite superficial layers of the spinothalamic tract. Judging from the coexisting symptoms, the lesion was considered to be in the extremely lateral and posterolateral area, involving part of the inferior cerebellar peduncle and not involving the more medial and posterior area that includes the descending trigeminal tract, the nucleus ambiguus, and the nucleus gracilis (Fig 1C).

In conclusion, LMI is an important entity to consider in the differential diagnosis of dermatomal sensory manifestations.

References

1. Wilkins RH, Brody IA. Wallenberg's syndrome. *Arch Neurol* 1970;22:379-382.
2. Kim JS. Sensory symptoms in ipsilateral limbs/body due to lateral medullary infarction. *Neurology* 2001;57:1230-1234.
3. Kim JS, Lee JH, Lee MC. Patterns of sensory dysfunction in lateral medullary infarction. Clinical-MRI correlation. *Neurology* 1997;49:1557-1563.