

Management of glioblastoma in an NF1 patient with moyamoya syndrome: a case report

Hideyuki Arita · Yoshitaka Narita · Makoto Ohno ·
Yasuji Miyakita · Yoshiko Okita · Takafumi Ide ·
Soichiro Shibui

Received: 5 July 2012 / Accepted: 16 October 2012 / Published online: 30 October 2012
© Springer-Verlag Berlin Heidelberg 2012

Abstract

Introduction Glioma and moyamoya syndrome are both potential complications of neurofibromatosis type 1 (NF1). Here, we report the first case of NF1 concomitantly presenting with glioblastoma 10 years after surgical treatment of moyamoya syndrome.

Case report A 14-year-old boy with NF1 was incidentally diagnosed by magnetic resonance imaging (MRI) with a thalamic tumor during a follow-up for moyamoya syndrome, which had been treated with surgery 10 years earlier. After observation for 36 months, he developed left hemiparesis, and MRI revealed an increase in tumor size and obstructive hydrocephalus due to the tumor. Needle biopsy was performed through small craniotomy, and the histological diagnosis was glioblastoma. After concurrent chemoradiotherapy with 23 cycles of temozolomide, partial response of the tumor was observed. However, 24 months after the start of the initial therapy, the tumor showed regrowth, and the patient died 30 months after the initial therapy. No cerebrovascular events associated with moyamoya syndrome and chemoradiotherapy were observed during the clinical course of glioblastoma.

Discussion Glioblastoma is a fatal disease in children, and our patient successfully received chemoradiotherapy with temozolomide despite the diagnoses of NF1 and moyamoya syndrome. Although radiotherapy or chemotherapy

potentially causes cerebrovascular complications, chemoradiotherapy might be feasible for glioblastoma treatment in patients with moyamoya syndrome and NF1. The following issues are discussed in the management of the present case: the indication of biopsy in NF1 cases, the method of surgery, and the treatment protocol for tumors concomitant with moyamoya disease or syndrome.

Keywords Glioblastoma · Neurofibromatosis · Moyamoya syndrome · Radiotherapy · Temozolomide

Introduction

Neurofibromatosis type 1 (NF1) is an inherited tumor predisposition syndrome in which affected patients develop tumors of central and peripheral nervous systems with increased frequency [1]. The most common brain tumor that occurs with this disease is pilocytic astrocytoma (PA). Other types of glioma can also occur, but the actual frequency is not known. Glioblastoma has been reported to account for 7 % of gliomas complicated with NF1 in a study of 100 pathological specimens that were available for review [2]. In another report that included non-surgical cases, the frequency was 1.9 % [3]. Given that asymptomatic cases of PA may remain undiagnosed, the actual incidence of glioblastoma is likely much lower than described above, and thus, glioblastoma is a relatively rare NF1 complication.

However, vasculopathies are also associated with NF1. In 316 cases of NF1, cerebrovascular disorders were found in 2.5 % [4]. Those abnormalities include occlusive, stenotic, or aneurysmal patterns as well as other rare disorders, such as arteriovenous fistulas or malformations [4–6]. Of these, moyamoya syndrome has been referred to as a potential complication, with an incidence of 0.6 % in the largest series [4, 7–10].

Herein, we describe a rare case of glioblastoma in an NF1 patient 10 years after moyamoya syndrome treatment; this case is unique in terms of the therapeutic process.

H. Arita · Y. Narita (✉) · M. Ohno · Y. Miyakita · Y. Okita ·
S. Shibui

Department of Neurosurgery and Neuro-Oncology,
National Cancer Center Hospital,
5-1-1, Tsukiji, Chuo-ku,
Tokyo 104-0045, Japan
e-mail: yonarita@ncc.go.jp

T. Ide

Department of Neurosurgery,
Tokyo Metropolitan Bokutoh Hospital,
4-23-15, Kotobashi, Sumida-ku,
Tokyo 130-8575, Japan

Case description

A 14-year-old boy with NF1 was diagnosed by magnetic resonance imaging (MRI) with a thalamic malignant tumor. Although pathological diagnosis and treatment were necessary, his past history of surgery for moyamoya syndrome posed a significant problem in the therapeutic plan.

He was diagnosed with NF1 on the basis of familial history and physical findings, including multiple subcutaneous neurofibromas and café-au-lait spots. He experienced repeated transient ischemic attacks at age 4, and a moyamoya syndrome associated with NF1 was diagnosed by angiography. Indirect revascularization with encephaloduroarteriosynangiosis (EDAS) was performed on both sides with staged operation. A right frontoparietal cortical infarction was a postoperative complication. He underwent an additional EDAS operation because of recurrent ischemic attacks. After the surgery, he received medical follow-up with radiological examinations. At age 14, MR images incidentally revealed a new lesion showing poorly marginated high intensity on fluid-attenuated inversion recovery (FLAIR) images, low intensity on the T1-weighted images, and no significant contrast enhancement with gadolinium contrast agent (Fig. 1a). Thalamic glioma was suspected on the basis of the radiological findings, and he was referred to our hospital for treatment. Both surgery and radiation

therapy were considered to pose significant risk of revascularization damage, and his tumor was followed closely without treatment. He had mild mental retardation but had a normal high school life. Nineteen months after the first diagnosis, the tumor showed partial contrast enhancement on MR images. The tumor showed gradual growth, and left hemiparesis appeared and gradually worsened. Thirty-six months after the first diagnosis (when he was 17 years old), radiological examination showed significant dilatation of the right lateral ventricle, suggesting an isolated ventricle syndrome due to the compression of the tumor (Fig. 1b). At that time, needle biopsy for histological diagnosis was planned. Preoperative angiography showed occlusive changes in the distal portion of the bilateral internal carotid artery (ICA) and multiple tiny collateral arteries from occluded ICA and revascularized external carotid artery systems (Fig. 2a–d). With the patient and his family's written informed consent, the biopsy was performed through a small frontal craniotomy, which was considered to have lower risk of vascular injury with careful preoperative planning. Tumor tissue samples were obtained under ultrasonographic and Stealth® (Medtronic, MN, USA) neuronavigation guidance. Histological examination of obtained specimens revealed the presence of glioblastoma. As the initial therapy for glioblastoma, local radiotherapy was administered for a total dose of 60 Gy at 2 Gy/fraction with concomitant chemotherapy

Fig. 1 Magnetic resonance (MR) images of the tumor. **a** Initial MR images of the tumor. The FLAIR image showed a high-intensity area in the right thalamus, suggesting thalamic glioma. **b** Preoperative MR image. T1-weighted imaging with contrast enhancement showed an irregularly shaped enhanced lesion in the right basal ganglia. The right lateral ventricle was dilated. **c** MR image after 15 cycles of adjuvant chemotherapy using temozolomide. The tumor in the right basal ganglia had decreased in size. **d** MR image after 23 cycles of adjuvant chemotherapy. A newly enhanced lesion appears in the right corpus callosum and the anterior horn of the lateral ventricle, suggesting recurrence of the tumor

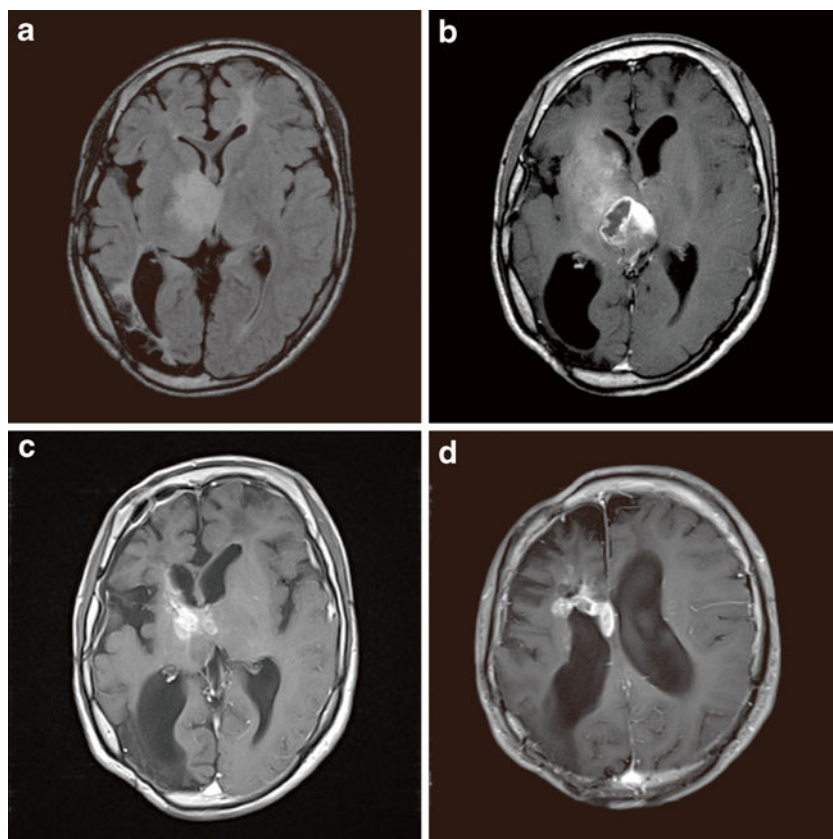
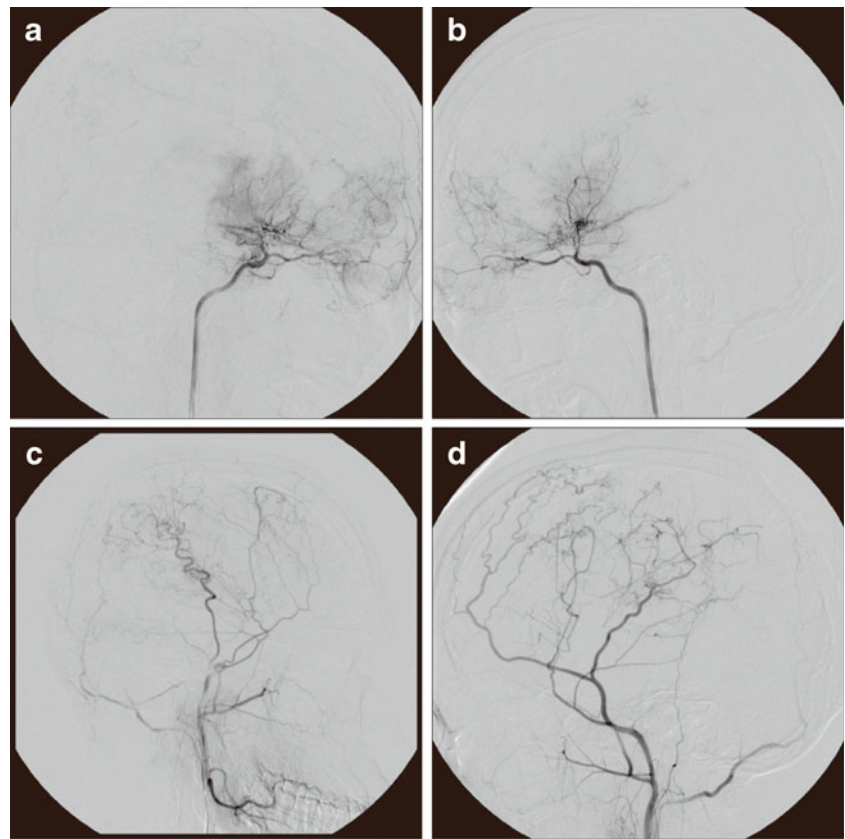


Fig. 2 Preoperative cerebral angiography. **a, b** Internal carotid arteriography of the right (**a**) and left (**b**) side. Bilateral stenotic changes in the terminal portion of the internal carotid artery were apparent. Tiny vessels from the carotid artery and ethmoidal artery were also observed. **c, d** External carotid arteriography of the right (**c**) and left (**d**) side. Collateral arteries from the external carotid system were observed



consisting of temozolomide (TMZ) at a daily dose of 75 mg/m^2 . Although the risk of ischemia induced by irradiation and chemotherapy was discussed, the revascularized area was included in the radiation field with consideration for the fatal course of the tumor. The patient responded to the initial therapy and was subsequently treated via chemotherapy with TMZ for 5 days every 28 days (Fig. 1c). No cerebrovascular events associated with moyamoya syndrome were observed. After 23 cycles of TMZ, MRI showed a recurrence of the tumor in the right corpus callosum and the anterior horn of the lateral ventricle (Fig. 1d). The tumor showed progression even after 2 cycles of second-line chemotherapy consisting of TMZ and procarbazine. Subsequent MRI for follow-up showed progressive tumor invasion of the brainstem, and he became completely hemiplegic on the left side and had consciousness disturbance. Twenty-nine months after the surgery, he underwent ventriculoperitoneal shunt placement for obstructive hydrocephalus. He died at home of the tumor 30 months after beginning the initial therapy.

Discussion

This is the first reported case of glioblastoma in a NF1 patient 10 years after surgical treatment of moyamoya syndrome, even though both diseases are well-known complications of NF1. According to the later onset of glioblastoma,

the moyamoya syndrome was considered independent of the tumor or irradiation. Three challenging issues were presented in the management of the present case: the indication of biopsy in NF1 cases, the method of surgery, and the treatment protocol for tumors concomitant with moyamoya disease or syndrome.

First, the indication for biopsy in NF1 cases should be determined according to the possibility of histological types other than PA, which necessitates different therapeutic approaches. Not surprisingly, histological type is a significant indicator for survival time in NF1 cases [2], and identifying non-PA cases is crucial. Although the frequency of histological types is not known, extra-optic location and symptomatic or progressive tumors have been referred as poor prognostic factors or malignant histological types [3, 11]. The present patient underwent biopsy because malignancy was suspected due to the progressive clinical course and tumor location. Chemoradiotherapy, without histological diagnosis, might be a treatment option for such cases. However, given that systemic pathologic analyses for such cases have been limited, a differential diagnosis from PA, which is likely to respond to conventional carboplatin/vincristine chemotherapy, should be made if possible [11].

Second, brain tumor surgery in patients with moyamoya disease or syndrome is associated with the risk of cerebral ischemia due to collateral vessel damage, and requires special attention to surgical approaches. Limited number of

reports have documented the coexistence of brain tumors and moyamoya disease or syndrome, except for cases of vasculopathy after irradiation [12–15]. In reports where surgical approaches were chosen without damaging vessels, no cerebrovascular events occurred, similar to our case [12–15]. Even in patients with moyamoya vessels, surgery for tumors can be achieved without complications as long as the collateral or moyamoya vessels are preserved.

The third issue pertains to chemoradiotherapy. Vasculopathy after radiation therapy for intracranial lesions is a severe adverse effect, which likely occurs in younger patients [16]. Irradiation may damage cerebral arteries and increase the risk of cerebral ischemia, particularly in patients with pre-existing cerebrovascular disease. Very few reports have described the experience of irradiation for patients with moyamoya disease or syndrome [14, 15]. One report documented the case of a germinoma patient who received focal and whole-ventricle irradiation and did not experience an ischemic event [14]. Another case with pleomorphic xanthoastrocytoma might have shown progression of moyamoya disease after irradiation [15]. Chemotherapy may also increase the risk of cerebrovascular events [17, 18]. Cisplatin has been referred as a potential causing agent of cerebral ischemic events most frequently, although the mechanism of this drug-induced stroke remains unknown [19–22]. Anti-angiogenic agents including bevacizumab can also increase cerebral vascular events [18, 23, 24]. The indication and risks of irradiation and chemotherapy for patients with moyamoya disease remain unclear. In our case, NF1 itself was also a major risk factor for vasculopathy after irradiation [25]. There is only limited information about glioblastoma in NF1 cases, and the radiation results for such cases are not well described [2, 26–29]. Thus, the limited number of case reports about this dual pathology makes it difficult to determine the indication of radiotherapy. A previous study showed that the median overall survival of pediatric malignant glioma patients treated with TMZ and radiotherapy was less than 2 years, which is shorter than the survival time of the present patient [30]. Another series reported that glioblastoma patients without NF1 showed a median overall survival of 1.08 years, but five patients with NF1 had a median survival of 9.3 years after undergoing multimodal treatment, including TMZ and radiotherapy [26]. Thus far, the previous observations have been supported, and chemoradiotherapy should be adopted even in patients with dual pathologies. Another challenging point in the treatment for such cases is the irradiation method. Stereotactic radiotherapy allows precise beam shaping and delivery to the target, and could reduce a radiation injury of normal brain structures. Thus, this approach might be appropriate for cases susceptible to radiation injuries. However, there are no studies proving the efficacy of stereotactic radiosurgery or fractionated stereotactic radiotherapy for

newly diagnosed malignant gliomas without previous external beam radiotherapy [31]. The poorly marginated shape and the size of the tumor in our case also precluded the indication of this approach. Fractionated intensity-modulated radiotherapy might be a better option in our case, but the appropriate therapeutic dose of this method has not been well elucidated [32].

In summary, the rare dual pathology of glioblastoma and moyamoya syndrome in an NF1 patient mandated careful clinical management. In the present case, the patient was successfully treated using surgery and chemoradiotherapy with TMZ without any adverse events. These treatment options should be considered even for NF1 patients with moyamoya syndrome when a histological diagnosis of glioblastoma is confirmed.

Acknowledgments This work was supported in part by the National Cancer Center Research and Development Fund (23-A-20) and the Health and Labour Sciences Research Grants of the Ministry of Health, Labour and Welfare (H23-Ganrinsho-Ippan-013).

Disclosures The authors have no personal financial or institutional interest in any of the drugs, materials, or devices described in this article.

References

1. Gutmann DH, Aylsworth A, Carey JC, Korf B, Marks J, Pyeritz RE, Rubenstein A, Viskochil D (1997) The diagnostic evaluation and multidisciplinary management of neurofibromatosis 1 and neurofibromatosis 2. *JAMA* 278:51–57
2. Rodriguez FJ, Perry A, Gutmann DH, O'Neill BP, Leonard J, Bryant S, Giannini C (2008) Gliomas in neurofibromatosis type 1: a clinicopathologic study of 100 patients. *J Neuropathol Exp Neurol* 67:240–249. doi:10.1097/NEN.0b013e318165eb75
3. Guillamo JS, Creange A, Kalifa C, Grill J, Rodriguez D, Doz F, Barbarot S, Zerah M, Sanson M, Bastuji-Garin S, Wolkenstein P (2003) Prognostic factors of CNS tumours in neurofibromatosis 1 (NF1): a retrospective study of 104 patients. *Brain* 126:152–160
4. Rosser TL, Vezina G, Packer RJ (2005) Cerebrovascular abnormalities in a population of children with neurofibromatosis type 1. *Neurology* 64:553–555. doi:10.1212/01.WNL.0000150544.00016.69
5. Parkinson D (1999) AVMs and neurofibromatosis. *Surg Neurol* 52:325–326
6. Cluzel P, Pierot L, Leung A, Gaston A, Kieffer E, Chiras J (1994) Vertebral arteriovenous fistulae in neurofibromatosis: report of two cases and review of the literature. *Neuroradiology* 36:321–325
7. Koc F, Yerdelen D, Koc Z (2008) Neurofibromatosis type 1 association with moyamoya disease. *Int J Neurosci* 118:1157–1163. doi:10.1080/00207450801898279
8. Smith M, Heran MK, Connolly MB, Heran HK, Friedman JM, Jett K, Lyons CJ, Steinbok P, Armstrong L (2011) Cerebrovasculopathy in NF1 associated with ocular and scalp defects. *Am J Med Genet A* 155A:380–385. doi:10.1002/ajmg.a.33788
9. Tan RM, Chng SM, Seow WT, Wong J, Lim CC (2008) 'Moya' than meets the eye: neurofibromatosis type 1 associated with Moyamoya syndrome. *Singapore Med J* 49:e107–e109
10. Sobata E, Ohkuma H, Suzuki S (1988) Cerebrovascular disorders associated with von Recklinghausen's neurofibromatosis: a case report. *Neurosurgery* 22:544–549

11. Leonard JR, Perry A, Rubin JB, King AA, Chicoine MR, Gutmann DH (2006) The role of surgical biopsy in the diagnosis of glioma in individuals with neurofibromatosis-1. *Neurology* 67:1509–1512. doi:10.1212/01.wnl.0000240076.31298.47
12. Lau YL, Milligan DW (1986) Atypical presentation of craniopharyngioma associated with Moyamoya disease. *J R Soc Med* 79:236–237
13. Arita K, Uozumi T, Oki S, Kuwabara S, Ohba S, Nakahara T, Muttaqin Z, Kohno H, Yamada K (1992) Moyamoya disease associated with pituitary adenoma—report of two cases. *Neurol Med Chir (Tokyo)* 32:753–757, JST.Journalarchive/nmc1959/32.753
14. Shibata Y, Matsuda M, Suzuki K, Matsumura A (2010) Cystic neurohypophysial germinoma associated with moyamoya disease. *Neurol Sci* 31:189–192. doi:10.1007/s10072-009-0172-1
15. Horiguchi S, Mitsuya K, Watanabe R, Yagishita S, Nakasu Y (2011) Pleomorphic xanthoastrocytoma and moyamoya disease in a patient with neurofibromatosis type 1—case report. *Neurol Med Chir (Tokyo)* 51:310–314, JST.JSTAGE/nmc/51.310
16. Bitzer M, Topka H (1995) Progressive cerebral occlusive disease after radiation therapy. *Stroke* 26:131–136
17. Rogers LR (2010) Cerebrovascular complications in patients with cancer. *Semin Neurol* 30:311–319. doi:10.1055/s-0030-1255224
18. Rinne ML, Lee EQ, Wen PY (2012) Central nervous system complications of cancer therapy. *J Support Oncol* 10:133–141. doi:10.1016/j.suponc.2011.11.002
19. Li SH, Chen WH, Tang Y, Rau KM, Chen YY, Huang TL, Liu JS, Huang CH (2006) Incidence of ischemic stroke post-chemotherapy: a retrospective review of 10,963 patients. *Clin Neurol Neurosurg* 108:150–156. doi:10.1016/j.clineuro.2005.03.008
20. Moore RA, Adel N, Riedel E, Bhutani M, Feldman DR, Tabbara NE, Soff G, Parameswaran R, Hassoun H (2011) High incidence of thromboembolic events in patients treated with cisplatin-based chemotherapy: a large retrospective analysis. *J Clin Oncol* 29:3466–3473. doi:10.1200/JCO.2011.35.5669
21. Czaykowski PM, Moore MJ, Tannock IF (1998) High risk of vascular events in patients with urothelial transitional cell carcinoma treated with cisplatin based chemotherapy. *J Urol* 160:2021–2024
22. Periard D, Boulanger CM, Eyer S, Amabile N, Pugin P, Gerschheimer C, Hayoz D (2007) Are circulating endothelial-derived and platelet-derived microparticles a pathogenic factor in the cisplatin-induced stroke? *Stroke* 38:1636–1638. doi:10.1161/STROKEAHA.106.479733
23. Scappaticci FA, Skillings JR, Holden SN, Gerber HP, Miller K, Kabbinavar F, Bergsland E, Ngai J, Holmgren E, Wang J, Hurwitz H (2007) Arterial thromboembolic events in patients with metastatic carcinoma treated with chemotherapy and bevacizumab. *J Natl Cancer Inst* 99:1232–1239. doi:10.1093/jnci/djm086
24. Seet RC, Rabinstein AA, Lindell PE, Uhm JH, Wijdicks EF (2011) Cerebrovascular events after bevacizumab treatment: an early and severe complication. *Neurocrit Care* 15:421–427. doi:10.1007/s12028-011-9552-5
25. Grill J, Couanet D, Cappelli C, Habrand JL, Rodriguez D, Sainte-Rose C, Kalifa C (1999) Radiation-induced cerebral vasculopathy in children with neurofibromatosis and optic pathway glioma. *Ann Neurol* 45:393–396
26. Huttner AJ, Kieran MW, Yao X, Cruz L, Ladner J, Quayle K, Goumnerova LC, Irons MB, Ullrich NJ (2010) Clinicopathologic study of glioblastoma in children with neurofibromatosis type 1. *Pediatr Blood Cancer* 54:890–896. doi:10.1002/pbc.22462
27. Hakan T, Aker FV (2008) Case report on a patient with neurofibromatosis type 1 and a frontal cystic glioblastoma. *Neurol Neurochir Pol* 42:362–365
28. Pal E, Gomori EE, Gati I (2001) Neurofibromatosis and glioblastoma in a case of multiple sclerosis. *Eur J Neurol* 8:717–718
29. Distelmaier F, Fahsold R, Reifenberger G, Messing-Juenger M, Schaper J, Schneider DT, Gobel U, Mayatepek E, Rosenbaum T (2007) Fatal glioblastoma multiforme in a patient with neurofibromatosis type I: the dilemma of systematic medical follow-up. *Childs Nerv Syst* 23:343–347. doi:10.1007/s00381-006-0222-4
30. Cohen KJ, Pollack IF, Zhou T, Buxton A, Holmes EJ, Burger PC, Brat DJ, Rosenblum MK, Hamilton RL, Lavey RS, Heideman RL (2011) Temozolomide in the treatment of high-grade gliomas in children: a report from the Children's Oncology Group. *Neuro Oncol* 13:317–323. doi:10.1093/neuonc/noq191
31. Tsao MN, Mehta MP, Whelan TJ, Morris DE, Hayman JA, Flickinger JC, Mills M, Rogers CL, Souhami L (2005) The American Society for Therapeutic Radiology and Oncology (ASTRO) evidence-based review of the role of radiosurgery for malignant glioma. *Int J Radiat Oncol Biol Phys* 63:47–55. doi:10.1016/j.ijrobp.2005.05.024
32. Chen C, Damek D, Gaspar LE, Waziri A, Lillehei K, Kleinschmidt-DeMasters BK, Robischon M, Stuhr K, Rusthoven KE, Kavanagh BD (2011) Phase I trial of hypofractionated intensity-modulated radiotherapy with temozolomide chemotherapy for patients with newly diagnosed glioblastoma multiforme. *Int J Radiat Oncol Biol Phys* 81:1066–1074. doi:10.1016/j.ijrobp.2010.07.021