

## Unusual presentation of more common disease/injury

## Intracranial venous sinus thrombosis mimicking Lhermitte Duclos disease

Heramba Narayan Praharaj, Maneesh Kumar Singh, Ravindra Kumar Garg, Tushar Premraj Raut

Department of Neurology, Chhatrapati Shahuji Maharaj Medical University, Lucknow, Uttar Pradesh, India

Correspondence to Dr Heramba Narayan Praharaj, babipraharaj@gmail.com

**Summary**

A middle-aged man presented with 1-month history of headache, dizziness, staggering of gait and progressive deafness. Examination revealed decreased visual acuity, papilloedema, gaze evoked nystagmus, bilateral sensorineural deafness and gait ataxia. MRI showed T1 iso and T2 hyperintensity of cerebellum, prominence of folia with gyral enhancement in a tigroid pattern making impression of the rare entity, Lhermitte Duclos disease (LDD) or dysplastic gangliocytoma of cerebellum. Conservative management for the raised intra cranial pressure did not have any impact on patient's general condition for which an MR venogram was planned and it surprisingly showed non-visualisation of left transverse sinus and internal jugular vein, suggestive of thrombosis. Patient was treated with anticoagulants but he succumbed to his illness soon after. We present this case to convey that a high index of suspicion should always be there in mind for this commoner condition (venous sinus thrombosis) before diagnosing the rarer ones (here LDD disease) to prevent the disastrous consequences of the former.

**BACKGROUND**

Cerebral venous sinus thrombosis (CVST) is a relatively common condition resulting from various infective, inflammatory, neoplastic and thrombophilic conditions.<sup>1</sup> Though the classical presentation is with headache, vomiting, seizure, focal deficits, vision loss and alteration of sensorium, unusual forms of presentation may be seen. Though MR venogram clinches the diagnosis, plain MRI may not show the classical signs of venous thrombosis and hence sometimes creates diagnostic confusion especially when the presentation mimics other rare diseases.<sup>2</sup> We here present a similar case whose MRI resembled Lhermitte Duclos disease (LDD), a rare neuronal tumour of cerebellum but MR venogram revealed intracranial venous sinus thrombosis. Our message is that, a high index of suspicion should be there regarding CVST even if plain MRI misleading and we should go for a venogram to diagnose at the earliest and prevent the potential mortality.

**CASE PRESENTATION**

A 42-year-old man, pharmacist by profession, presented to our department with 1 month history of dizziness and staggering of gait. There was headache associated with dizziness but no vomiting. After 15 days he complained of decreased hearing which gradually increased in intensity so that patient at admission was not able to hear even when spoken close to his ears. There was no history of fever, ear discharge, seizures, unconsciousness, drug intake, any other comorbid illness and family history was not contributory. There were no symptoms suggestive of any other cranial nerve dysfunction. Neurological examination showed apparently normal higher function. Cranial nerve examination showed visual acuity of 6/12, early papilloedema, normal ocular movements, bilateral gaze evoked nystagmus and gross bilateral sensorineural hearing loss. Motor and sensory examinations were unremarkable but

there was ataxia of gait. Skull and spine were normal and there were no meningeal signs.

**INVESTIGATIONS**

Biochemical and haematological investigations including homocystine and vitamin B<sub>12</sub> were unremarkable. BAER (Brainstem Auditory Evoked Response) showed no recordable wave forms. Cerebrospinal fluid (CSF) showed an increase in protein with pleocytosis but work-up for tubercular or viral aetiology was negative. MRI of brain showed T1 isointense (figure 1) and T2 hyperintense (figure 2) diffusely involving whole of the grey matter of cerebellum, thickening of cortical layer, prominent folia with contrast enhancement producing a tigroid pattern (figure 3).

**DIFFERENTIAL DIAGNOSIS**

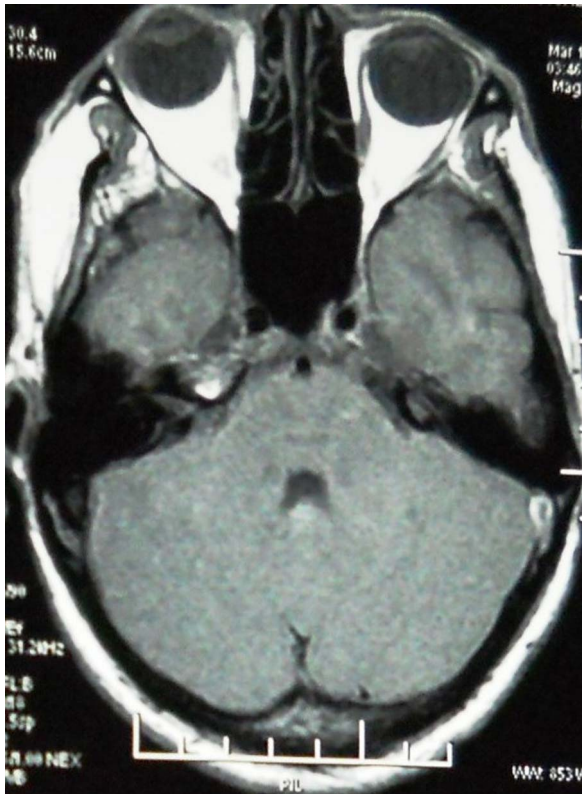
The aforementioned MRI features are characteristic of a dysplastic neuronal tumour of cerebellum called LDD. Cerebellar infarct sometimes produces similar picture of prominent folia despite mass effect.<sup>2</sup>

**TREATMENT**

He was initially treated with intravenous steroids, mannitol and diuretics.

**OUTCOME AND FOLLOW-UP**

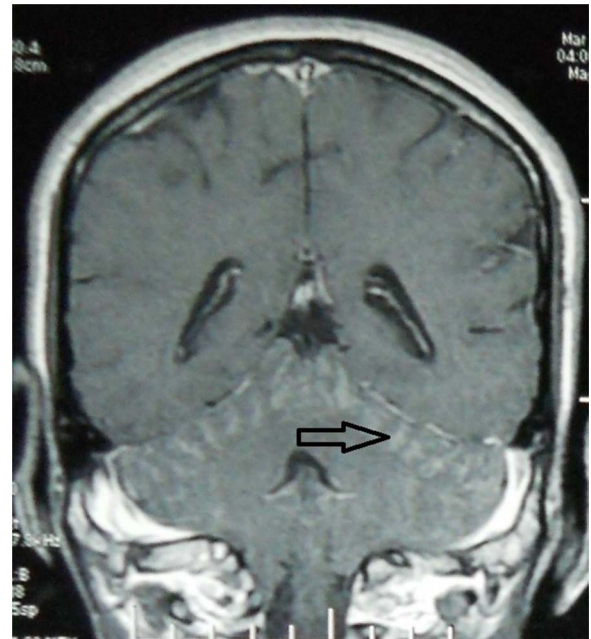
Patient did not have any significant improvement in symptoms. An MR venogram was planned and it surprisingly showed non-visualisation of left transverse sinus and left internal jugular vein suggesting thrombosis (figures 4 and 5). He was immediately started on low-molecular-weight heparin but he did not show a satisfactory response and went on deteriorating and succumbed to his illness on the 20th day of admission.



**Figure 1** T1 weighted axial MRI of brain showing isointense cerebellum.

**DISCUSSION**

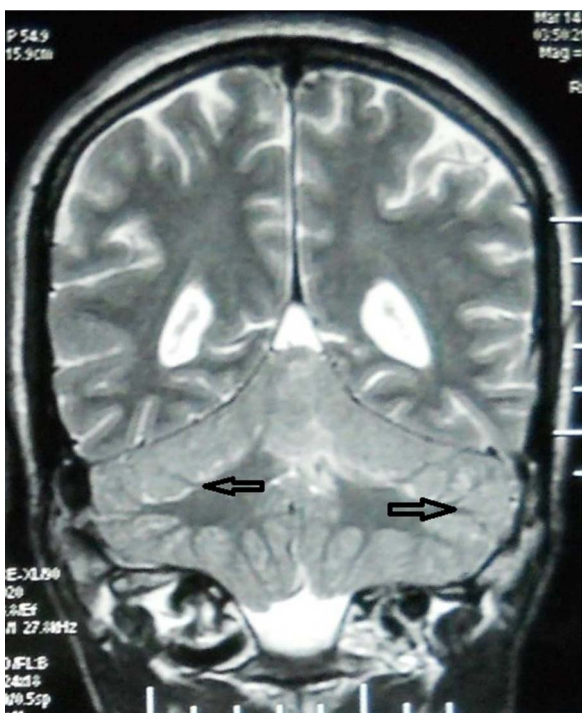
CVST commonly presents with headache, vomiting, seizures, acute onset focal deficits and disorientation.



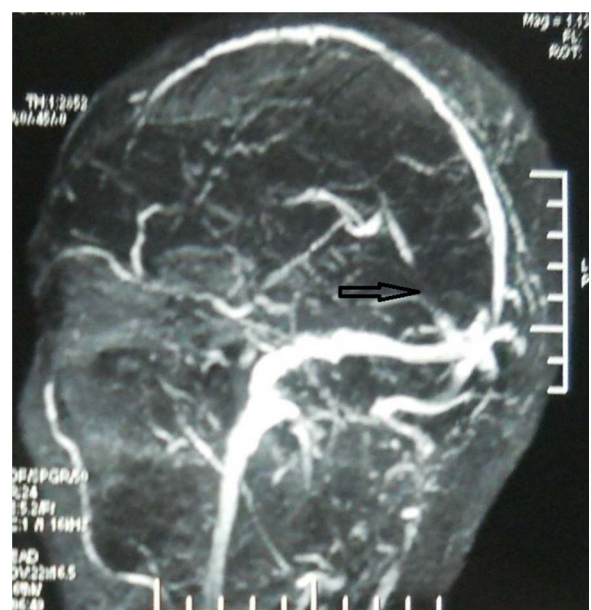
**Figure 3** T1 contrast coronal MRI of brain showing enhancement of cerebellum in a tigroid pattern.

Sometimes the presentation may be that of a subacute onset craniopathy like vestibular neuropathy, deafness and facial weakness.<sup>5</sup> Presenting with bilateral deafness is extremely unusual in venous sinus thrombosis and was misleading in our case.

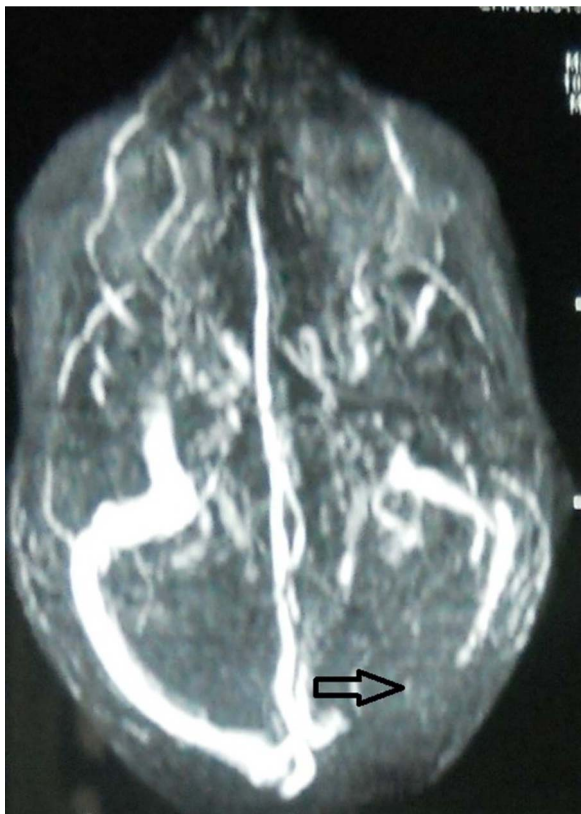Classical MRI features of CVST on plain MRI include absence of flow void, bilateral or multifocal infarcts beyond distribution of arterial occlusion, a haemorrhagic infarct or visualisation of enhancing thrombus.<sup>1</sup> When these features are not distinct, it may sometimes be



**Figure 2** T2 weighted coronal MRI of brain showing hyperintense cerebellar cortex with thickening and prominence of folia.



**Figure 4** Sagittal MR venogram of brain showing non visualisation of left transverse sinus.



**Figure 5** Coronal MR venogram of brain showing non visualisation of left transverse sinus and left internal jugular vein.

difficult to diagnose CVST on plain MRI. MRI in our case showed T1 isointensity and T2 hyperintensity of the whole of cerebellar cortex with contrast enhancement and prominence of folia in a tigroid pattern which mimics a neuronal tumour of cerebellum called the dysplastic cerebellar ganglionocytoma or LDD (mentioned below).

LDD is one of the neuronal tumours of brain which presents with sub-acute onset cerebellar signs and symptoms of raised intra cranial pressure in form of headache, vomiting, ataxia, visual blurring and deafness. The tumour consists of a hamartomatous proliferation of ganglion cells which replaces the inner granular cell and middle Purkinje cell layer of cerebellum.<sup>3</sup>

MRI shows T1 hypointensity and T2 hyperintensity involving one or both lobes of cerebellum<sup>2</sup> with prominence of folia producing a characteristic tigroid pattern (resembling our case). The lesion may or may not enhance with contrast.<sup>4</sup> There may be hydrocephalus due to the whole mass obstructing the fourth ventricle. As mentioned earlier, the similar may be found only in infarct of cerebellum (venous or arterial).

CSF examination in CVST is usually normal but may show increased protein, and when associated with an increased cell count<sup>3</sup> may create confusion with tubercular meningitis as happened in the present case. We did not get any evidence of tuberculosis in CSF in form of AFB or PCR positivity.

Treatment also varies for the two conditions. Where surgery is curative for LDD, prompt treatment with anti-coagulant is necessary in CVST.<sup>2</sup> Mortality in untreated cases of the latter may range from 5.5% to 18% for which an early MR venogram in appropriate clinical setting is inevitable even if MRI is atypical.

#### Learning points

- ▶ Intracranial venous sinus thrombosis is a potentially treatable condition if diagnosed early.
- ▶ MRI may not always show the classical features and may mimic other rare diseases like Lhermitte Duclos disease in the present case.
- ▶ An early MR venogram in appropriate clinical setting is lifesaving even if plain MRI is atypical.

**Competing interests** None.

**Patient consent** Obtained.

#### REFERENCES

1. **Allroggen H**, Sarawan J. Cerebral venous sinus thrombosis. *J Postgrad Med* 2000;**76**:12–15.
2. **Bayat MRH**, Sarawan J. CT and MRI findings in Lhermitte Duclos disease. *SA J Radiol* 2005;Feb:30–1.
3. **Bozbuga M**, Gulec I, Suslu HT, *et al*. Bilateral Lhermitte Duclos disease. *Neurol India* 2010;**58**:309–11.
4. **Spaargaren L**, Cras P, Bornhof MA, *et al*. Contrast enhancement in Lhermitte-Duclos disease of the cerebellum: correlation of imaging and neuropathology in two cases. *Neuroradiology* 2003;**45**:381–5.

Copyright 2012 BMJ Publishing Group. All rights reserved. For permission to reuse any of this content visit

<http://group.bmj.com/group/rights-licensing/permissions>.

BMJ Case Report Fellows may re-use this article for personal use and teaching without any further permission.

Please cite this article as follows (you will need to access the article online to obtain the date of publication).

Praharaj HN, Singh MK, Garg RK, Raut TP. Intracranial venous sinus thrombosis mimicking Lhermitte Duclos disease. *BMJ Case Reports* 2012;10.1136/bcr-2012-007058, Published XXX

Become a Fellow of BMJ Case Reports today and you can:

- ▶ Submit as many cases as you like
- ▶ Enjoy fast sympathetic peer review and rapid publication of accepted articles
- ▶ Access all the published articles
- ▶ Re-use any of the published material for personal use and teaching without further permission

For information on Institutional Fellowships contact [consortiasales@bmjgroup.com](mailto:consortiasales@bmjgroup.com)

Visit [casereports.bmj.com](http://casereports.bmj.com) for more articles like this and to become a Fellow