

Spontaneous Midbrain Hemorrhage*

ROBERT J. FINGEROTE, MD, ASHFAQ SHUAIB, MD, FRCPC, and
A. KEITH W. BROWNELL, MD, FRCPC, Calgary, Alberta, Canada

ABSTRACT: Spontaneous (nontraumatic) midbrain hemorrhage (SMH) is an uncommon condition whose diagnosis is greatly assisted by the use of cranial computerized tomography. Of 18 cases described in the English language literature, only two were diagnosed without the aid of CT. We report five cases of SMH in five normotensive patients. Vertical gaze palsies were noted in four patients, headache in four, pupillary dysfunction in four, mild hemiplegia in two, unilateral ataxia in two, and unilateral asterixis in one. The diagnosis of SMH had not been considered before CT scanning in any of these patients. All patients had partial to complete recovery. Cerebral angiography in each case showed no abnormalities in the area of the hemorrhage.

RAPID DIAGNOSIS of acute neurologic events has been facilitated by the routine application of high-resolution cranial computerized tomography (CT), which has allowed clinicians to gain an appreciation of lesions previously rarely diagnosed ante mortem. Spontaneous midbrain hemorrhage (SMH) is such an entity.

In this report we describe the clinical features of SMH in five patients seen at the Foothills Hospital and the Calgary General Hospital over an 18-month period. Some of the features of Cases 4 and 5 have been previously reported.¹ The need for CT scanning to diagnose this uncommon condition is demonstrated.

CASE REPORTS

Case 1. A 35-year-old normotensive woman came to the hospital five days after the onset of a headache that developed abruptly in the right supraorbital area. Within two hours of onset, the headache worsened, extended to involve the entire cranium, and became associated with neck stiffness. The headache resolved over the subsequent 24 hours but recurred two days later and was associated with blurred vision and nausea. At this time the patient became aware of a dilated right pupil. Her past history was unremarkable.

Examination on admission was unremarkable except for a dilated right pupil that reacted sluggishly to light and accommodation and was nonresponsive to pilocarpine eye drops (0.125%). Cranial CT, done on admission, showed a 1 cm midbrain hemorrhage in close proximity to the cerebral peduncle at the level of exit of the third right cranial nerve. Cerebral angiography showed no lesion in the region of the hemorrhage.

Forty-eight hours after admission, she had diplopia with downward gaze. Ocular motility studies showed moderate weakness of the right inferior rectus muscle, with minimal

weakness of the right medial and superior rectus muscles. A repeat cranial CT scan, done on hospital day 5, showed partial resolution of the hemorrhage.

The patient was discharged after eight days. Her only complaint at that time was diplopia on downward gaze. Over two years of follow-up she has had no new neurologic symptoms.

Case 2. A 30-year-old normotensive woman came to the hospital with a one-day history of severe headache that had started abruptly in the right occipital region. Within two to three hours it worsened, became generalized, and was aggravated by head movement. Although it decreased in severity over the subsequent 12 hours, she became aware of weakness in the left arm and leg, unsteadiness on her feet, numbness in her mouth, and difficulty with phonation. Her past history was unremarkable.

On examination, there was a left hemiparesis and left-sided dysmetria and dysdiadochokinesia. She veered to the left when walking, and was unable to perform tandem gait. Cranial nerve and sensory examination showed no abnormality.

Cranial CT scan showed a small hemorrhage in the midbrain extending into the pons on the right side with slight surrounding edema (Fig 1). Cerebral angiography showed no abnormality in the area of the hemorrhage.

Within 24 hours of admission, the headache had resolved, and by the fourth day the left-sided weakness and cerebellar signs had largely resolved. On day 5, she had right pupillary dilation, which lasted approximately 72 hours. At discharge on hospital day 10, her only deficit was mild weakness of the left arm. A cranial CT scan done on the day before discharge showed a significant decrease in the size of the hemorrhage (Fig 2). The only abnormality seen on a CT scan done six months later was an area of hypodensity in the region of the hemorrhage.

Case 3. A 56-year-old woman came to the hospital after the acute onset of a right supraorbital headache associated with nausea, vomiting, ataxia, blurred vision, and vertigo. Examination showed small pupils only minimally responsive to light. There was paralysis of vertical gaze with convergence retraction nystagmus occurring both spontaneously and with attempts to look upward. Asterixis in the left hand, mild ataxia of the right upper and lower limbs, and mild right-sided dysmetria were also noted. On walking, she tended to fall backward and to the left. She was noted to be somnolent.

*Presented at the poster session, 23rd Canadian Congress of Neurological Sciences, Ottawa, Canada, June 15-18, 1988.

From the Departments of Internal Medicine and Clinical Neurosciences, University of Calgary, Calgary, Alberta, Canada.

Reprint requests to A. K. W. Brownell, MD, Foothills Hospital, 1403 29th St NW, Calgary, Alberta T2N 2T9.

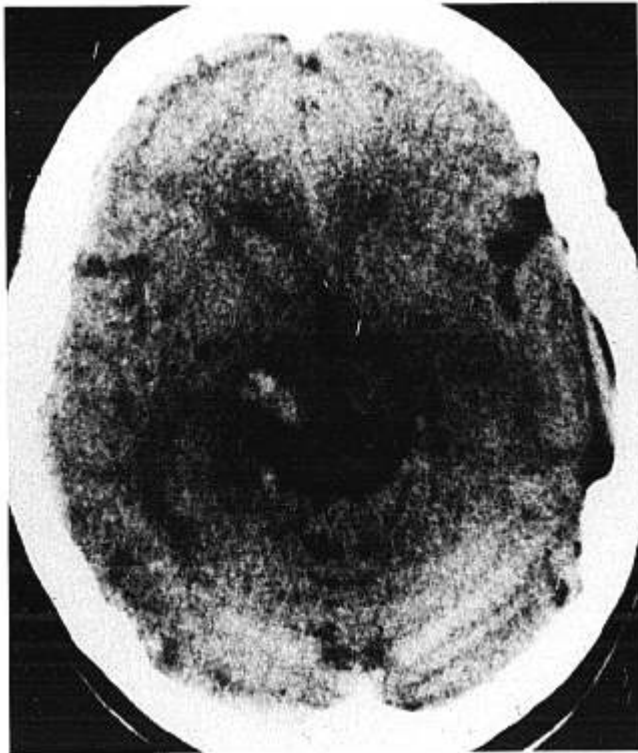


FIGURE 1. (Case 2) Unenhanced cranial CT scan on admission shows localized hemorrhage in right midbrain.

Cranial CT scan showed a hemorrhage in the posterior right thalamus, extending into the right midbrain, with a small amount of blood in the posterior third and lateral ventricles. There was mild hydrocephalus of the lateral and third ventricles. A falx meningioma was also seen. Cerebral angiography showed no vascular abnormality in the region of the hemorrhage.

Within 24 hours, the vertigo had eased, headache had resolved, and asterix had disappeared. Within 96 hours, her downward gaze had improved and her vision was less blurred. She was able to walk unassisted. A repeat CT scan done on day 8 showed significant resolution of the hemorrhage and hydrocephalus. She was discharged seven days after admission. Reassessment two weeks later showed limited vertical gaze to be her only neurologic deficit.

Case 4. A 51-year-old normotensive man came to the hospital shortly after having blurred vision, diplopia, lightheadedness, and unsteadiness on his feet. His past history was unremarkable. Examination showed a dilated, unreactive left pupil, left-sided ptosis, and paralysis of the medial, inferior, and superior rectus muscles. The patient was unable to stand unsupported, and fell toward the right. There was right lateral gaze nystagmus.

Cranial CT showed a left midbrain hemorrhage extending into the left hypothalamus. Cerebral angiography showed no lesion in the region of the hemorrhage.

Although within a week the ptosis had cleared and the pupillary dilation had lessened, at discharge on hospital day 7, the patient was continuing to have unsteadiness on his feet and diplopia on lateral gaze. Two months later, the unsteadiness had resolved and the only neurologic deficits remaining were minimal deficit of downward gaze with minor weakness of the left medial rectus muscle. A CT scan done at this time was normal.

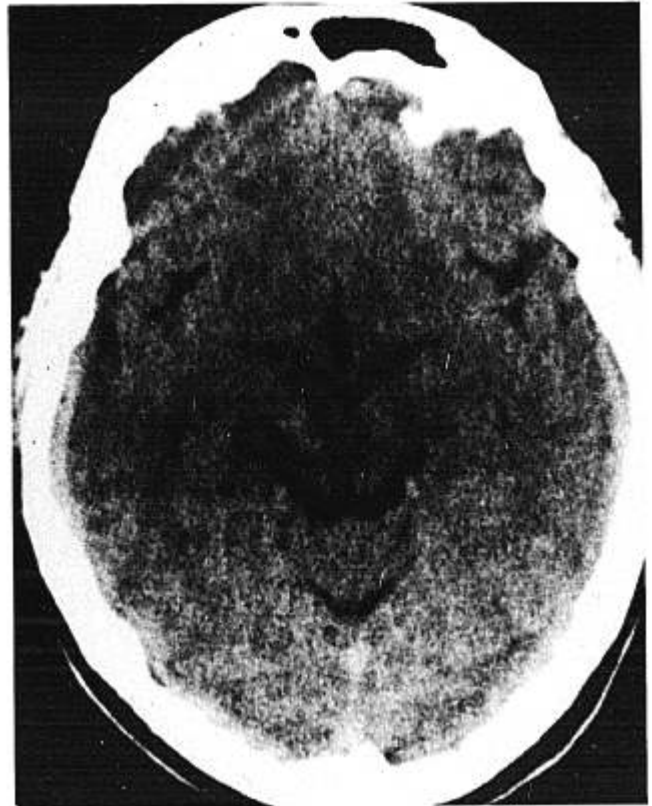


FIGURE 2. (Case 2) Unenhanced cranial CT scan done nine days after initial scan shows significantly diminished hemorrhage.

Case 5. A previously healthy 17-year-old boy came to the hospital one week after the sudden onset of a severe, throbbing, left occipital headache associated with photophobia, diplopia, drowsiness, nausea, and vomiting. Right-sided weakness had lasted several hours shortly after the onset of the headache. Both headache and diplopia persisted, and his parents noticed left-sided ptosis. His past history was unremarkable. Examination revealed left medial and inferior oblique palsies, left-sided ptosis, and mild neck stiffness, as well as diplopia on vertical gaze.

Cranial CT scan showed a hemorrhage in the left lateral midbrain, extending into the hypothalamus. Cerebral angiography showed no vascular abnormalities. It was thought that this hemorrhage could possibly be due to an underlying midbrain tumor, but left frontoparietal craniotomy revealed only a midbrain hematoma, which was drained. Histologic examination of the specimen obtained showed only clotted blood. The patient's diplopia resolved within ten days and he was asymptomatic when discharged after 22 days.

Two months after the event, results of examination and cranial CT scan remained normal. Excessive weight gain suggested hypothalamic dysfunction due to the hemorrhage or surgical exploration.

DISCUSSION

Eighteen cases of spontaneous midbrain hemorrhage have been described in detail in the English language literature.¹⁻¹⁰ Only two of the cases were diagnosed without the benefit of cranial CT scanning.^{2,3} In each of those two cases, a craniotomy was done with the preoperative diagnosis of intracranial neoplasia.

Vertical gaze palsies were noted in 16 patients, 15 had headaches, 14 had disturbances of pupillary function, 13 had an altered state of consciousness, nine had impaired cerebellar function, and eight had varying degrees of motor deficit. Two patients were hypertensive. In one case, temporary blindness and retrograde amnesia were noted in a hypertensive man with a history of alcohol abuse and a coagulopathy. Angiography, done in 17 cases, failed to show vascular abnormalities in the area of hemorrhage. Seven patients had surgical procedures, four with drainage of the hematoma and three with ventricular drainage for hydrocephalus. In two patients small arteriovenous malformations were found in the hematoma wall during a hematoma drainage procedure. There were no deaths reported and all patients had partial or complete recovery.

Neurologic deficit in this condition results from hemorrhage-induced tissue destruction and compression of midbrain and surrounding tissue. The clinical presentation may be complicated by the effects of an obstructive hydrocephalus. As hemorrhage is resorbed, compression eases in surrounding tissue, obstruction to CSF flow is relieved, and neurologic improvement occurs.

Spontaneous midbrain hemorrhage should be considered in the differential diagnosis of headache and visual disturbance with evidence of pupillary dysfunction, vertical gaze palsy, and ataxia. Consciousness may not be disturbed, and there may be additional neurologic symptoms and signs of motor or sensory deficit. The differential diagnosis includes embolic or thrombotic infarct, migraine,

Wernicke's encephalopathy, subarachnoid hemorrhage, or a primary or secondary intracranial neoplasm. Trauma or midbrain hemorrhage due to a bleeding diathesis may be manifested in a similar fashion.

In none of the previously or currently described cases could cerebral angiography determine the cause of the midbrain hemorrhage. Angiography is therefore considered of limited value in the investigation of spontaneous midbrain hemorrhage.

Widespread application of computerized tomography may result in more frequent diagnosis of this condition and improved appreciation of its character and natural history. Experience to date suggests the prognosis for this condition is good.

References

1. Shuaib A, Murphy W: Mesencephalic hemorrhage and third nerve palsy. *J Comput Tomogr* 11:385-388, 1987
2. Scoville WB, Poppen JL: Intrapuduncular hemorrhage of the brain: successful operative approach with evacuation of clot and a seven and one-fourth year observation period. *Arch Neurol Psychiat* 61:688-694, 1949
3. La Torre E, Delitala A, Sorano V: Hematoma of the quadrigeminal plate: case report. *J Neurosurg* 49:610-613, 1978
4. Humphreys RP: Computerized tomographic definition of mesencephalic hematoma with evacuation through pedunculotomy: case report. *J Neurosurg* 49:749-752, 1978
5. Durward QJ, Barnett HJM, Barr HWK: Presentation and management of mesencephalic hematoma: report of 2 cases. *J Neurosurg* 56:123-127, 1982
6. Sand JJ, Biller J, Corbett JJ, et al: Partial dorsal mesencephalic hemorrhages: report of 3 cases. *Neurology* 36:529-533, 1986
7. Weisberg LA: Mesencephalic hemorrhages: clinical and computed tomographic correlations. *Neurology* 36:713-716, 1986
8. Stern LZ, Bernick C: Spontaneous isolated mesencephalic hemorrhage (Letter). *Neurology* 36:1627, 1986
9. Mehler MF, Ragone PS: Primary spontaneous mesencephalic hemorrhage. *Can J Neurol Sci* 15:435-438, 1988
10. Keane JR: Isolated brain-stem third nerve palsy. *Arch Neurol* 45:813-814, 1988