

CASE REPORT

Cerebral hyperperfusion after flow diversion of large intracranial aneurysms

Albert Ho Yuen Chiu,¹ Jason Wenderoth²¹Interventional Neuroradiology Department, Liverpool Hospital, Liverpool, New South Wales, Australia²Department of Medical Imaging, Prince of Wales Hospital, Sydney, New South Wales, Australia**Correspondence to**Dr Albert Ho Yuen Chiu, albert.h.chiu@gmail.com**ABSTRACT**

Cerebral hyperperfusion syndrome has been proposed to be caused by rapidly increased blood flow into chronically hypoperfused parenchyma with resultant impaired autoregulation, and has been noted after clipping of intracranial aneurysms and carotid stenting. The occurrence of the syndrome after endovascular flow diversion, however, has not been previously described. A 52-year-old woman was admitted electively for flow diverter treatment of a recurrent ventral paraclinoid aneurysm arising within a dysplastic segment of the left internal carotid artery. During the immediate postprocedural period the patient was found to have confusion, right hemiparesis, facial droop and dysarthria, which resolved with blood pressure control. Subsequent CT perfusion on day 11 demonstrated mildly elevated cerebral blood flow, cerebral blood volume and permeability values in the left hemisphere.

BACKGROUND

Cerebral hyperperfusion syndrome has been proposed to be due to rapidly increased blood flow into chronically hypoperfused parenchyma with resultant impaired autoregulation,^{1–3} and has been noted after clipping of intracranial aneurysms^{4–6} and carotid stenting.^{1–3} The occurrence of the syndrome after endovascular flow diversion, however, has not been previously described. We present a case of the syndrome after flow diversion of a large ventral paraclinoid aneurysm.

CASE PRESENTATION

A 52-year-old woman was admitted electively for flow diverter treatment of a recurrent ventral paraclinoid aneurysm arising within a dysplastic segment of the left internal carotid artery which also demonstrated multiple smaller unruptured aneurysms. The large paraclinoid aneurysm had previously been coiled acutely, with the residual perfusing component measuring 16 mm in diameter with a 10 mm neck. The patient was a heavy smoker and also had a history of hypertension, which was diagnosed 7 years previously, and appeared medically well-controlled with the last reading from the GP measuring 132/89.

Prior to the procedure, the patient was given 100 mg aspirin and 75 mg clopidogrel daily for 5 days, and an intraprocedural dose of 5000 U heparin was given to reach an activated coagulation time of 255. Insertion of a 3.75 mm × 18 mm Pipeline Embolization Device (ev3, Irvine,

California, USA) was performed uneventfully with a deployment time of approximately 3 min (figure 1).

However, during the immediate postprocedural period, approximately 1 h after flow diverter deployment, the patient was found to have confusion, right hemiparesis, facial droop and dysarthria. Her recorded systolic blood pressure at this point was 160 mm Hg.

OUTCOME

A CT scan of the brain was performed as an emergency but no abnormality was demonstrated and abciximab was given in expectation of embolic disease. However, this treatment resulted in no improvement. Hyperperfusion syndrome was then suspected and the patient was placed on a glyceryl trinitrate infusion with a systolic blood pressure target of 100–120. The target blood pressure was reached approximately 10.5 h after the procedure, but by 6 h after the procedure the hemiparesis had already resolved, at a systolic pressure of 138.

MRI was performed approximately 7 h after the procedure and revealed no evidence of diffusion restriction (figure 2), with 3D time-of-flight MR angiography demonstrating large vessel patency. Heparin infusion was continued for 24 h, titrated to an activated partial thromboplastin time of 50–90 as per routine.

Repeat MRI on day 4 demonstrated gyriform left posterior temporal cortical edema (figure 3), but there was no evidence of regional susceptibility artefact on susceptibility-weighted imaging to suggest hemorrhage (figure 4). The patient's blood pressure continued to be controlled with hydralazine, which resulted in resolution of symptoms over the next 4 days. Subsequent CT perfusion on day 11 demonstrated mildly elevated cerebral blood flow, cerebral blood volume and permeability values in the left hemisphere compared with the contralateral hemisphere (figure 5).

FLAIR imaging at a subsequent MRI examination performed 6 months after the procedure (figure 6) demonstrated a normal appearance of the hyperperfused area with no evidence of gliosis to suggest previous infarct.

DISCUSSION

Cerebral hyperperfusion syndrome has been noted after carotid stenting¹ and clipping of intracranial aneurysms,^{4–6} but has not been previously described with endovascular flow diversion. Most

To cite: Chiu AHY, Wenderoth J. *J NeuroInterv Surg* 2013; **5**:e48.

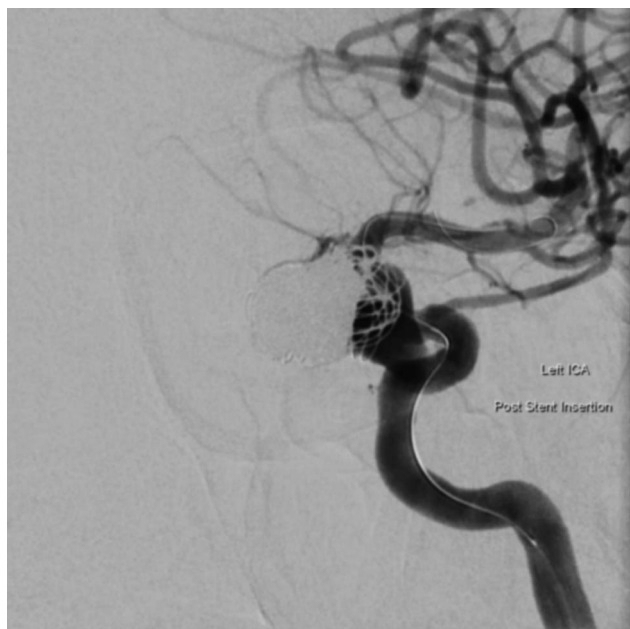

Figure 1 Immediate post-deployment angiographic image in oblique projection demonstrating the recurrent aneurysm sac.

studies report an incidence of the syndrome of 0–3% after carotid intervention. A wide range of symptomatology has been described, ranging from severe unilateral headache through to seizures, focal neurological deficits and intracranial hemorrhage.³ As flow-diverting stents also reduce blood flow into the aneurysmal sac by directing flow to the distal vessel similar to aneurysm clipping, it is logical to postulate that the syndrome may also occur with flow diversion and be susceptible to the same predisposing factors as the more recognized causes of hyperperfusion. These predisposing factors include hypertension, diabetes, age >75 years, recent carotid procedure within the past 3 months, high-grade ipsilateral or contralateral stenosis, female sex, vascular malformations and cerebrovascular reactivity.³

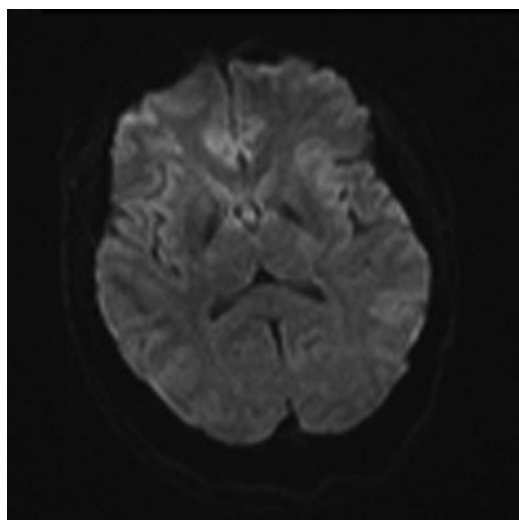


Figure 2 Axial diffusion-weighted imaging performed 7 h after the procedure showing no evidence of diffusion restriction, precluding procedural ischemia as a cause for symptomatology.

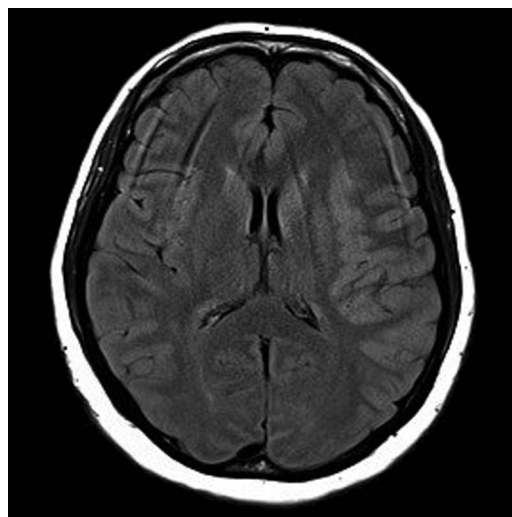


Figure 3 Axial FLAIR weighted imaging performed on day 4 showing mild edema of the left insular and opercular cortex.

Increased vessel maximum flow rate distal to the aneurysm after clipping has been demonstrated on transcranial Doppler studies. This has been postulated to be due to loss of the expansion effect of the aneurysm during systole, which would otherwise have reduced the available volume to be expelled into the distal vessel as well as potentially producing an exaggerated ‘Windkessel effect’. These changes have been hypothesized to be the cause of hyperperfusion after clipping¹ and have also been suggested as the cause of intraparenchymal hemorrhage after flow diversion.^{7 8}

Angiography typically shows a reduction or cessation of the ‘sump’ effect commonly seen with large aneurysms, with more rapid transit of contrast into the ipsilateral hemisphere. This angiographic finding is consistent with previous research involving hyperperfusion after carotid stenting, where a larger change in cerebral circulation time after stenting (with a cut-off of

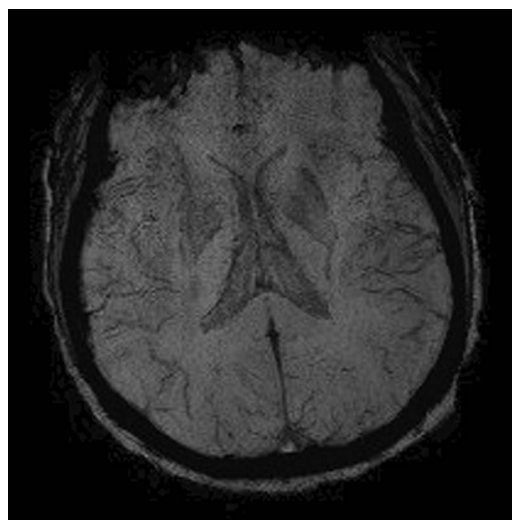


Figure 4 Axial susceptibility-weighted imaging performed on day 4 showing no evidence of hypointensity in the left hemisphere to suggest deposition of blood products.

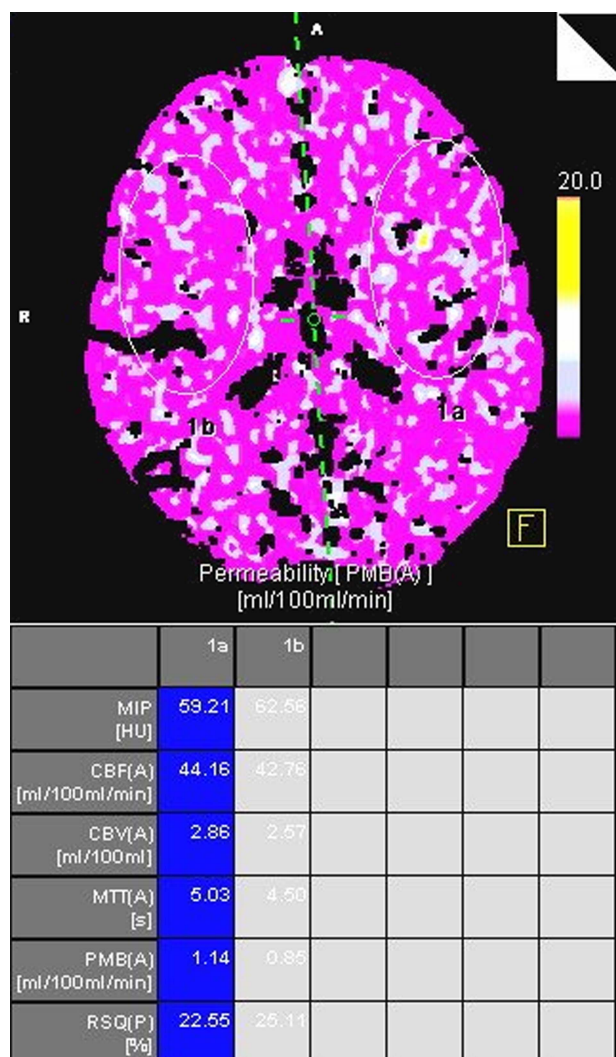


Figure 5 CT perfusion imaging performed on day 11 showing mildly elevated cerebral blood volume, cerebral blood flow and permeability. The differences are subtle, probably due to the delay to the perfusion study. The permeability map has been included to demonstrate the region of interest, which has been drawn to include a large area of each internal carotid territory to attempt to demonstrate the gross differences between the hemispheres.

2.7 s) has been correlated with the development of hemorrhagic hyperperfusion syndrome.¹ Although the change in cerebral circulation time in our patient was not significant, in view of her gender and history of hypertension, her suggestive symptomatology and imaging as well as her response to hypotensive therapy, we believe hyperperfusion syndrome provides an elegant potential unifying diagnosis.

Given the relatively early stage of clinical application of flow diversion, a number of alternative theories have been proposed as to the potential etiologies of delayed hemorrhage. Apart from changes in hemodynamic factors, the possibility of micro-wire perforations and hemorrhagic transformation of small infarcts have also been raised for parenchymal hemorrhage,⁸ and delayed aneurysmal rupture has been suggested for subarachnoid hemorrhage.⁹ We believe, however, that the identification of these imaging findings will render further weight to hemodynamic changes as a plausible cause for delayed hemorrhage and encourage further research into this new treatment modality.

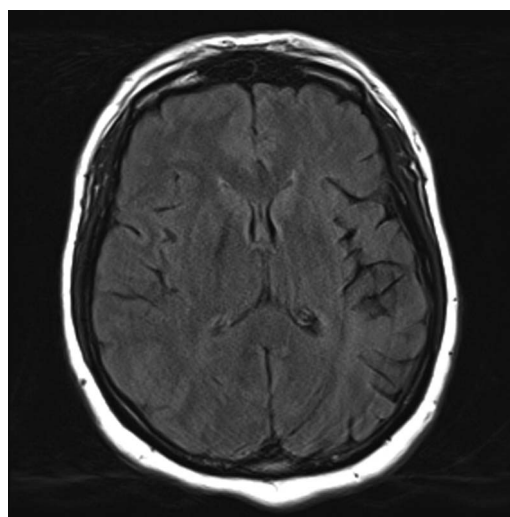


Figure 6 Axial FLAIR imaging performed 6 months after the procedure showing normal appearances of the left insular and opercular cortex without evidence of T2 hyperintensity to suggest gliosis from previous ischemic injury.

Key messages

- ▶ Cerebral hyperperfusion syndrome should be considered in any case of early neurological deterioration in patients who have undergone flow diversion, for which early CT perfusion is suggested to exclude hyperperfusion.
- ▶ Awareness of the differences in transit time before and after flow diversion may be useful in identifying patients at risk.
- ▶ Consideration should also be given to cerebral hyperperfusion syndrome as a potential cause for hemorrhage after flow diversion, a known complication of severe cerebral hyperperfusion, especially given the universal administration of aspirin and clopidogrel prior to the procedure which may worsen the severity of any intracranial bleeding.

Acknowledgements Wisdom Tong (CT senior radiographer, Liverpool Hospital) who provided technical assistance in the manipulation of CT perfusion data.

Contributors Both authors contributed to the interpretation and analysis of the results and the writing of the paper.

Competing interests None.

Patient consent Obtained.

Provenance and peer review Not commissioned; externally peer reviewed.

REFERENCES

- 1 Narita S, Aikawa H, Nagata S, *et al*. Intraprocedural prediction of hemorrhagic cerebral hyperperfusion syndrome after carotid artery stenting. *J Stroke Cerebrovasc Dis*. Published Online First: 28 Dec 2011. doi:10.1016/j.jstrokecerebrovasdis.2011.10.015.
- 2 Murakami H, Inaba M, Nakamura A, *et al*. Ipsilateral hyperperfusion after neck clipping of a giant internal carotid artery aneurysm. *J Neurosurg* 2002;97:1233–6.
- 3 Lieb M, Shah U, Hines GL. Cerebral hyperperfusion syndrome after carotid intervention: a review. *Cardiol Rev* 2012;20:84–9.
- 4 Maruya J, Nishimaki K, Minakawa T. Hyperperfusion syndrome after neck clipping of a ruptured aneurysm on a dolichoectatic middle cerebral artery. *J Stroke Cerebrovasc Dis* 2011;20:260–3.
- 5 Sugino T, Ohtaki M, Wanibuchi M, *et al*. Hyperperfusion syndrome after clipping an unruptured cerebral aneurysm: two case reports. *Neural Med Chir (Tokyo)* 2010;50:306–9.

New devices

- 6 Kuroki K, Taguchi H, Yukawa O. Hyperperfusion syndrome after clipping of an unruptured aneurysm. *Neuro Med Chir (Tokyo)* 2006;46:248–50.
- 7 Velat GJ, Fargen KM, Lawson MF, *et al.* Delayed intraparenchymal hemorrhage following pipeline embolization device treatment for a giant recanalized ophthalmic aneurysm. *J Neurointerv Surg* 2012;4:e24.
- 8 Cruz JP, Chow M, O’Kelly C, *et al.* Delayed ipsilateral parenchymal hemorrhage following flow diversion for the treatment of anterior circulation aneurysms. *Am J Neuroradiol* 2012;33:603–8.
- 9 Kulcsar Z, Houdart E, Bonafe A, *et al.* Intra-aneurysmal thrombosis as a possible cause of delayed aneurysm rupture after flow diversion treatment. *Am J Neuroradiol* 2011;32:20–5.



Cerebral hyperperfusion after flow diversion of large intracranial aneurysms

Albert Ho Yuen Chiu and Jason Wenderoth

J NeuroIntervent Surg 2013 5: e48 originally published online November 27, 2012

doi: 10.1136/neurintsurg-2012-010479.rep

Updated information and services can be found at:

<http://jnis.bmj.com/content/5/6/e48.full.html>

These include:

References

This article cites 8 articles, 3 of which can be accessed free at:

<http://jnis.bmj.com/content/5/6/e48.full.html#ref-list-1>

Article cited in:

<http://jnis.bmj.com/content/5/6/e48.full.html#related-urls>

Email alerting service

Receive free email alerts when new articles cite this article. Sign up in the box at the top right corner of the online article.

Topic Collections

Articles on similar topics can be found in the following collections

[New devices](#) (99 articles)

Notes

To request permissions go to:

<http://group.bmj.com/group/rights-licensing/permissions>

To order reprints go to:

<http://journals.bmj.com/cgi/reprintform>

To subscribe to BMJ go to:

<http://group.bmj.com/subscribe/>