

# Cerebral Venous and Sagittal Sinus Thrombosis after Transcallosal Removal of a Colloid Cyst of the Third Ventricle: Case Report

Eddy Garrido, M.D., and Gerald R. Fahs, M.D.

*Departments of Neurosurgery (EG) and Pathology (GRF), Lancaster General Hospital, Lancaster, Pennsylvania*

The authors report a case of cortical vein and sagittal sinus thrombosis after a transcallosal removal of a colloid cyst of the third ventricle. Thirty-six hours after the operation, the patient developed focal seizures; after progressive deterioration, he died on the sixth postoperative day. At the autopsy, a venous hemorrhagic infarct in the right frontoparietal area and fresh thrombus occluding the sagittal sinus and cortical veins were found. The mechanism of cortical vein and sinus thrombosis subsequent to this procedure is discussed, and suggestions are made to prevent this serious complication. (*Neurosurgery* 26:540-542, 1990)

**Key words:** Cerebral infarct, Cerebral vein thrombosis, Colloid cyst, Sagittal sinus thrombosis, Transcallosal approach

Thrombosis of the sagittal sinus and cortical veins has been reported as a complication of the transcallosal approach to the lateral and third ventricles (9). Although rare, this complication usually leads to severe neurological deficits. We report a well-documented case of fatal thrombosis of the cortical cerebral veins and sagittal sinus after an uneventful transcallosal removal of a colloid cyst of the third ventricle. The precipitating factor appeared to be the coagulation of a large vein draining from the frontal lobe to the sagittal sinus.

## CASE REPORT

A 54-year-old man with a 2- to 3-year history of progressive headaches was seen. For 2 months before he was admitted, the headaches had become worse and he had noticed difficulties with ambulation as well as a subtle deterioration of his memory; however, he had been able to continue to carry on his job as a physician.

At neurological examination, the patient was alert and oriented, his mental status was unremarkable, and there was no papilledema nor any abnormalities of the cranial nerves. He had no weakness, reflex changes, or sensory abnormalities. The Romberg test disclosed nothing abnormal. He could not walk heel to toe in a straight line.

A magnetic resonance imaging (MRI) scan showed a lesion in the anterior third ventricle occluding the foramen of Monro, causing hydrocephalus. The findings were typical for a colloid cyst (Fig. 1). The patient was taken to surgery and underwent a right parasagittal craniotomy centered over the area of the coronal suture and in front of it. After the dura was opened, a large vein draining the frontal lobe into the sagittal sinus was encountered. The vein was located in front of the coronal suture, and it became evident that, to proceed with the operation, this vein needed to be taken. After coagulation and sectioning of this parasagittal vein, the frontal lobe was separated from the falx and the corpus callosum was exposed. With standard microsurgical technique, the corpus callosum was opened and the colloid cyst was totally removed through the foramen of Monro. No retractors were applied to the sagittal sinus or falx. A ventricular catheter was brought out through the scalp for postoperative drainage of cerebrospinal fluid.

Postoperatively, the patient awoke with no neurological

deficit. The next day, he was alert and oriented, able to sit up in bed to eat dinner and to watch television. About 36 hours after the operation, the patient had two focal seizures involving the left lower extremity, and postictally, he developed left hemiparesis. At this time, a computed tomographic (CT) scan of the brain was done, and it showed a rather large hemorrhagic infarct affecting the right frontoparietal area (Fig. 2). The cerebrospinal fluid was drained as needed to keep the intracranial pressure within normal limits.

The patient gradually deteriorated and became drowsy, and the hemiparesis became complete hemiplegia in about 24 to 36 hours. The CT scan was repeated 36 hours later, and it showed a slight increase in cerebral edema, but the hemorrhagic area had not changed. We did not feel that the patient would benefit from surgery to remove the intracerebral hematoma, since this was rather diffuse. The patient then became comatose and showed progressive weakness of his right side as well. He had cardiorespiratory arrest and died on the sixth postoperative day.

At the postmortem examination, he was found to have diffuse cerebral edema in addition to the hemorrhagic infarct that affected the right frontoparietal area. There was evidence of cortical vein thrombosis and thrombosis of the sagittal sinus (Figs. 3 and 4).

## DISCUSSION

The anterior transcallosal approach to the ventricular system for removal of colloid cysts and other tumors of the third ventricle is a well-established and excellent surgical procedure for the removal of these lesions (1, 2, 8, 9). Other surgical approaches that have been used for the removal of colloid cysts have been the transcortical, intraventricular approach and, more recently, the stereotactic aspiration and/or removal of the colloid cyst (1, 3, 6, 7).

The transcallosal approach gives an excellent view of the area of the foramen of Monro. It can be used in patients with normal or enlarged lateral ventricles, and the risk of postoperative seizures is small. Opening the corpus callosum from 2 to 2.5 cm does not seem to cause any permanent neuropsychological deficit.

A cerebral venous infarct causing serious neurological deficit is the most significant complication. Shucart and Stein

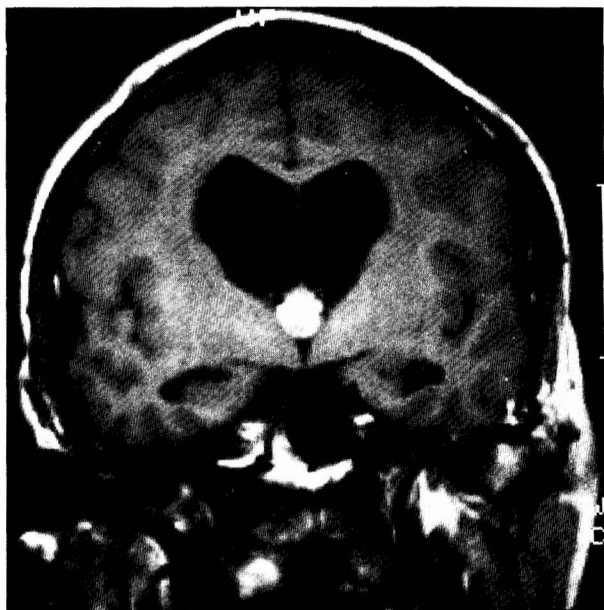


FIG. 1. MRI scan shows enlarged lateral ventricles and a homogenous lesion in the anterior third ventricle, typical of a colloid cyst.

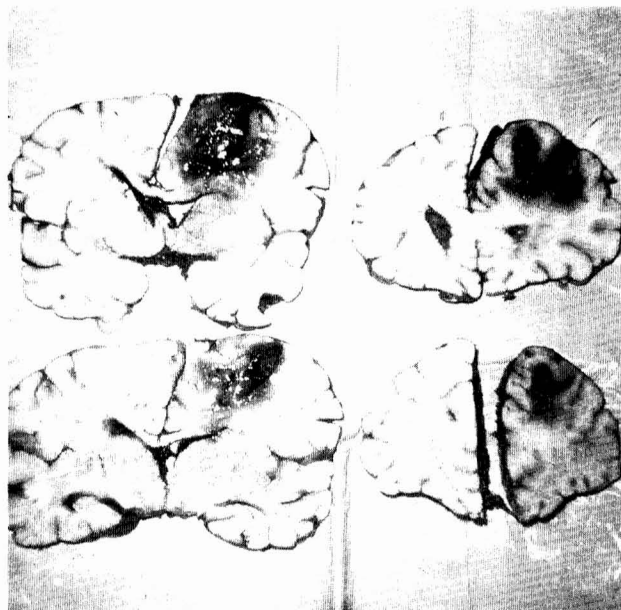


FIG. 3. The postmortem examination reveals a large hemorrhagic infarction in the right frontal and parietal lobes.

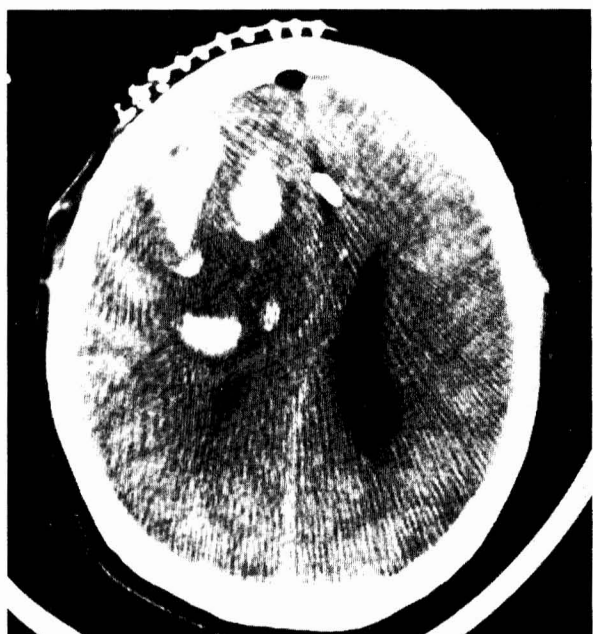

FIG. 2. CT scan 36 hours after surgery shows a hemorrhagic infarct involving the right frontal and parietal lobes.

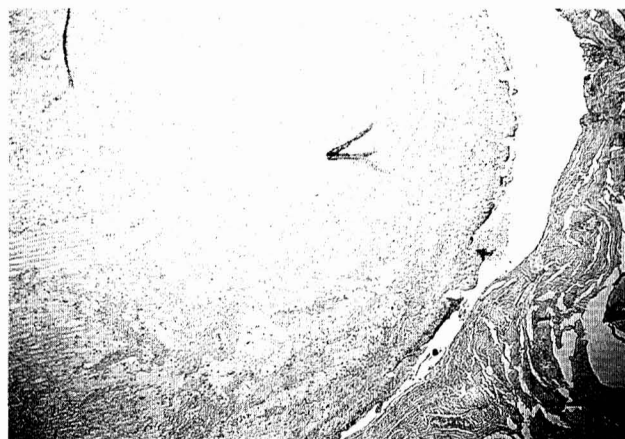

FIG. 4. Complete occlusion of the sagittal sinus by a fresh thrombus (hematoxylin and eosin,  $\times 100$ ).

(9), in a series of 25 patients operated on by this approach, had two patients in whom cortical vein thrombosis and cerebral infarcts developed. They believed the venous and sagittal sinus thrombosis was related to undue pressure by the brain retractor against the sagittal sinus in one patient and to coagulation of two prominent parasagittal veins in the other. In our patient, no retractors were used against the sagittal sinus or the falx; therefore, we cannot postulate this mechanism as the cause of the sinus thrombosis. The surgical coagulation of a prominent draining vein in the parasagittal area was probably the leading factor, since the decreased blood flow throughout the cortical veins and sagittal sinus after

coagulation of the parasagittal vein(s) causes venous stasis and promotes venous and sinus thrombosis.

Apuzzo et al. (2) recommend cerebral angiography prior to surgery to map out the parasagittal veins, so that the bone flap may be fashioned in an area that is devoid of prominent parasagittal veins. No venous infarcts occurred in their series of 11 patients. Ehni (4) also uses the angiogram as a guide for placement of the bone flap in order to avoid the parasagittal veins.

The transcortical, intraventricular approach for the management of colloid cysts is associated with a higher risk of seizures, and it is difficult to perform in a patient without significant hydrocephalus. The stereotactic aspiration of colloid cysts has been used by some surgeons and has been reported to be effective in about 50% of patients (6). The main problem is that frequently, the content of the colloid cyst is very thick or even solid, making aspiration impossible. More recently, stereotactic removal of colloid cysts has been reported (3). The complication rate associated with this procedure appears to be minimal. Obviously, this technique is

not widely available, and the total reported number of patients in whom it has been used is relatively small.

It would appear, then, that the transcallosal approach will remain as the procedure of choice to remove colloid cysts. To minimize the serious and potentially fatal complication of cerebral venous infarct associated with this procedure, we support the concept of performing cerebral angiography prior to surgery to visualize the parasagittal veins, so that the bone flap may be made in an area of the coronal suture devoid of veins. Obviously, the bone flap could be made either to the left or to the right of the midline. We also suggest making the opening in the bone large enough so that, if a large parasagittal vein is encountered that would have to be sacrificed to continue with the transcallosal approach, the transcortical intraventricular approach can be used instead. The use of brain retractors against the sagittal sinus should be avoided.

Once the diagnosis of cerebral venous infarct has been made, little can be done to reverse it. The patient should be kept well hydrated. The use of anticoagulants is contraindicated. Some patients will recover fully, but many will either be left with serious neurological deficit or will die (5).

Received for publication, August 3, 1989; accepted, September 12, 1989.

Reprint requests: Eddy Garrido, M.D., 1671 Crooked Oak Drive, Lancaster, PA 17601.

#### REFERENCES

1. Antunes JL, Louis KM, Ganti SR: Colloid cysts of the third ventricle. *Neurosurgery* 7:450-455, 1980.
2. Apuzzo MLJ, Chikovani OK, Gott PS, Teng EL, Zee C, Giannotta SL, Weiss MH: Transcallosal interforaminal approaches for lesions affecting the third ventricle: Surgical considerations and consequences. *Neurosurgery* 10:547-554, 1982.
3. Camacho A, Abernathy CD, Kelly PJ, Laws ER: Colloid cysts: Experience with the management of 84 cases since the introduction of computed tomography. *Neurosurgery* 24:693-700, 1989.
4. Ehni G: Comment on paper by Schucart and Stein. *Neurosurgery* 3:339-343, 1978.
5. Gates PC, Barnett HJM: Venous disease: Cortical veins and sinuses, in Barnett HJM, Mohr JP, Stein BM, Yatsu FM (eds): *Stroke: Pathophysiology, Diagnosis, and Management*. New York, Churchill Livingstone, 1986, vol 2, pp 731-743.
6. Hall WA, Lunsford LD: Changing concepts in the treatment of colloid cysts. *J Neurosurg* 66:186-191, 1987.
7. Little JR, MacCarty CS: Colloid cysts of the third ventricle. *J Neurosurg* 39:230-235, 1974.
8. Long DM, Chou SN: Transcallosal removal of craniopharyngiomas within the third ventricle. *J Neurosurg* 39:563-567, 1973.
9. Shucart WA, Stein BM: Transcallosal approach to the anterior ventricular system. *Neurosurgery* 3:339-343, 1978.

#### COMMENTS

The authors describe a complication of a cerebral midline exposure that is rare in experienced hands. Such an unfortunate event has not been encountered in any of more than 300 personal cases related to such surgery. Although possible, it is doubtful that sacrifice of a single draining vein in the pericoronal region would be solely responsible for such a disastrous chain of events, and other elements of surgical technique or patient status require consideration. Other than by direct application of a retractor, unrecognized sinus injury may be created by: 1) development of bony exposure during midline manipulations; 2) aggressive utilization of bipolar coagulation

in the perisinuous area; and 3) aggressive retraction of dural flaps to optimize midline exposure. In addition, a transient or unrecognized hypercoagulable state could contribute to such injuries, creating clinically important thrombotic events.

Excessive lateral retraction may initiate posterior venous injury. The potential for such injury and complication should be reduced by meticulous technique and constant recognition of the possibilities for their emergence during each stage of the operative exposure (1-3).

We have employed magnetic resonance studies to define venous tributaries and the paramedian venous anatomy in corridor development for a number of years, and largely have abandoned angiography for such planning (1). We are convinced of the necessity to consider preoperatively the definition of the midline and paramedian venous anatomy.

Some comment is needed with respect to the advisability of such a major surgical enterprise for colloid cyst management. Our developing experience with *image-directed stereotactic endoscopic* management of such lesions during the past 8 years has led us to adopt *stereotactic endoscopy* under local anesthesia as the initial procedure for the management of such lesions. Applying a number of methods in addition to "aspiration," we now believe that in experienced hands, the majority of these lesions may be satisfactorily treated by such minimally invasive methods, with major surgery being reserved for individuals in whom the stereotactic surgery is attended by an unsatisfactory result (4, 5).

Michael L. J. Apuzzo  
Los Angeles, California

1. Apuzzo MLJ: Surgery of masses affecting the third ventricular chamber: Techniques and strategies. *Clin Neurosurg* 34:499-522, 1988.
2. Apuzzo MLJ: Anterior and mid ventricular lesions: Surgical overview, in Apuzzo MLJ (ed): *Surgery of the Third Ventricle*. Baltimore, Williams & Wilkins, 1987, pp 495-541.
3. Apuzzo MLJ: Interforaminal approach, in Apuzzo MLJ (ed): *Surgery of the Third Ventricle*. Baltimore, Williams & Wilkins, 1987, pp 354-580.
4. Apuzzo MLJ: Applications of computerized tomographic guidance stereotaxis, in Apuzzo MLJ (ed): *Surgery of the Third Ventricle*. Baltimore, Williams & Wilkins, 1987, pp 751-792.
5. Apuzzo MLJ, Chandrasoma PT, Zelman V, Giannotta SL, Weiss MH: Computerized tomographic guidance stereotaxis in the management of lesions of the third ventricular region. *Neurosurgery* 15:502-508, 1984.

The authors review the unfortunate complication of venous infarction following transcallosal removal of a colloid cyst of the third ventricle. Their patient had severe hydrocephalus, so that a transcortical transventricular approach could have been considered. Recently, the transcallosal approach has become more popular among neurosurgeons, and many neurosurgeons prefer it to the transventricular approach. Therefore, it is important to realize that the risk of venous infarction is present when the transcallosal approach is used, if it becomes necessary to sacrifice large veins. This gives some support to those who prefer the transcortical transventricular approach in patients with hydrocephalus. We have used this approach in patients with hydrocephalus almost exclusively, and have reserved the transcallosal approach for those with normal-sized ventricles. The transcortical transventricular approach is still an excellent approach for these types of tumors.

Benjamin R. Gelber  
Omaha, Nebraska