

Brain abscess mimicking lung cancer metastases; a case report[☆]

Michiko Asano^a, Nobukazu Fujimoto^{a,*}, Yasuko Fuchimoto^a, Katsuichiro Ono^a, Shinji Ozaki^a,
Fumiaki Kimura^b, Takumi Kishimoto^a

^aDepartment of Respiratory Medicine, Okayama Rosai Hospital, Okayama, 1-10-25 Chikkomidorimachi, Minamiku, Okayama 7028055, Japan

^bDepartment of Medicine, Tamano City Hospital, 2-3-1 Uno, Tamano 7060011, Japan

Received 4 April 2012; accepted 18 April 2012

Abstract

A 76-year-old woman came to us because of staggering, fever, dysarthria, and appetite loss. Magnetic resonance imaging (MRI) of the brain revealed multiple masses with surrounding edema. Chest X-ray and computed tomography demonstrated a mass-like lesion in the left lung and left pleural effusion. Lung cancer and multiple brain metastases were suspected. However, the brain lesions demonstrated a high intensity through diffusion-weighted MRI. The finding was an important key to differentiate brain abscesses from lung cancer metastases. © 2013 Elsevier Inc. All rights reserved.

Keywords: Brain abscess; Metastatic brain tumors; Magnetic resonance imaging; *Nocardia*

1. Introduction

Brain abscesses are usually identified based on the diagnostic clinical symptoms, laboratory findings, and brain imaging. Prompt diagnosis and early treatment initiation are needed because the prognosis is poor [1]. The differential diagnosis between brain abscess and necrotic brain tumor can be difficult. We present a case in which multiple brain abscesses were diagnosed using diffusion-weighted magnetic resonance imaging (DWI) and successfully cured with antibiotic treatment.

2. Case report

A 76-year-old woman visited a local hospital because of staggering, dysarthria, and appetite loss. Magnetic resonance

imaging (MRI) of the brain revealed multiple masses with surrounding edema. Chest X-ray and computed tomography (CT) demonstrated a mass-like lesion in the left lower lobe of the lung (Fig. 1A) and left pleural effusion (Fig. 1B). Lung cancer with multiple brain metastases was suspected, and the patient was admitted to our hospital. She was treated with a course of antibiotics at the hospital because she experienced a fever of 38°C.

In our hospital, the patient underwent thoracentesis and bronchofiberscopy; however, cytological examination of the pleural fluid and bronchial lavage fluid did not reveal any malignant cells. The patient showed no peripheral leukocytosis and negative C-reactive protein. The left pleural effusion slightly decreased in 1 week without chemotherapy or pleural drainage. Gadolinium-diethylenetriamine-pentaacetic acid (Gd-DTPA)-enhanced MRI of the brain showed multiple ring-enhanced masses with surrounding edema (Fig. 2A), and these lesions were categorized as high intensity using DWI (Fig. 2B). Based on these findings, we concluded that the patient did not have any malignant diseases but likely had some kind of infection that resulted in pneumonia, pleurisy, and brain abscesses. However, we were unable to detect any responsible bacterium from

[☆] Conflict of interest: None.

* Corresponding author. Department of Respiratory Medicine, Okayama Rosai Hospital, 1-10-25 Chikkomidorimachi, Minamiku, Okayama 7028055, Japan. Tel.: +81 86 2620131; fax: +81 86 2623391.

E-mail address: nfuji@okayamaH.rofuku.go.jp (N. Fujimoto).

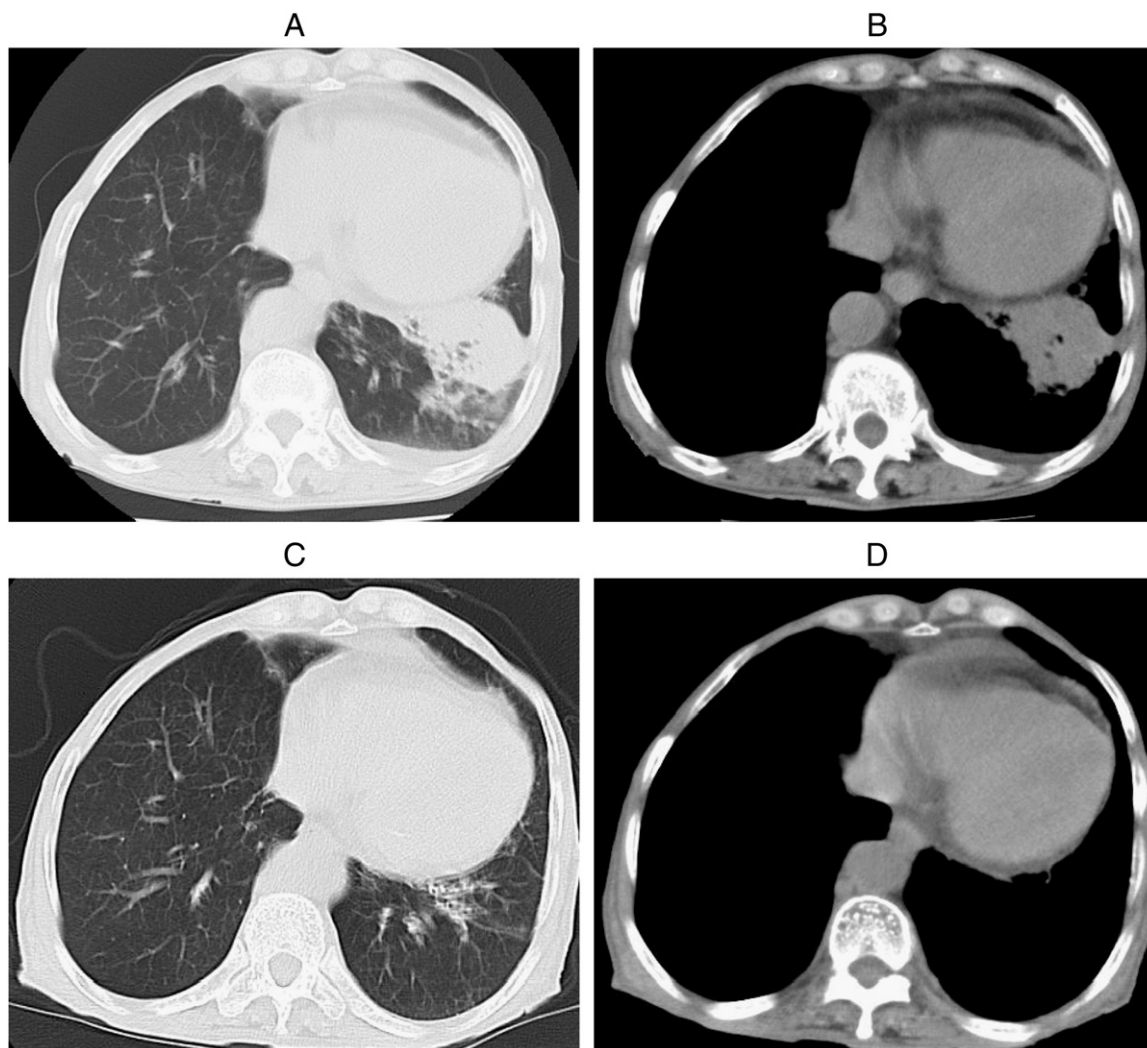


Fig. 1. Chest CT demonstrated a mass-like lesion in the left lower lobe of the lung (A) and left pleural effusion (B). After 3 months of treatment with antibiotics, both the mass-like lesion and the left pleural effusion disappeared completely (C, D).

cultivations of sputum, blood, pleural fluid, or bronchial lavage fluid.

At that time, we decided to begin treatment of the brain abscesses because the patient's general condition was worsening. We considered the possibility of *Nocardia* infection because this bacterium is likely to affect the lungs and brain. We started began treatment with sulfamethoxazole-trimethoprim (ST) and ceftriaxone (CTRX). Two weeks later, the patient's appetite increased and she began to talk smoothly. Thrombocytopenia and hyperkalemia appeared and were suspected as adverse effects of ST; however, we were able to continue the treatment with a reduced dose of the drug. The left pleural effusion and the mass in the left lung gradually regressed and had disappeared completely after 3 months of treatment (Fig. 1C, D). Multiple brain abscesses visibly reduced in size and had nearly disappeared after 6 months of treatment (Fig. 2C). The patient was treated with both ST and CTRX for 6 months and then stopped

CTRX. We continued ST for another 9 months with no sign of reactivation.

3. Discussion

We initially suspected lung cancer with metastatic brain tumors in this case because the patient had abnormal shadows in both the lung and the brain and, particularly, because the T1-weighted Gd-DTPA-enhanced brain MRI revealed multiple ring-enhanced lesions. However, there was no evidence of malignancy and the left pleural effusion decreased slightly without chemotherapy or pleural drainage. Ultimately, the left pleural effusion and the mass-like lesion in the left lung disappeared after 3 months and multiple brain masses almost disappeared after 6 months of treatment with antimicrobial agents, so we are convinced that the patient had pneumonia, pleuritis, and brain abscesses.

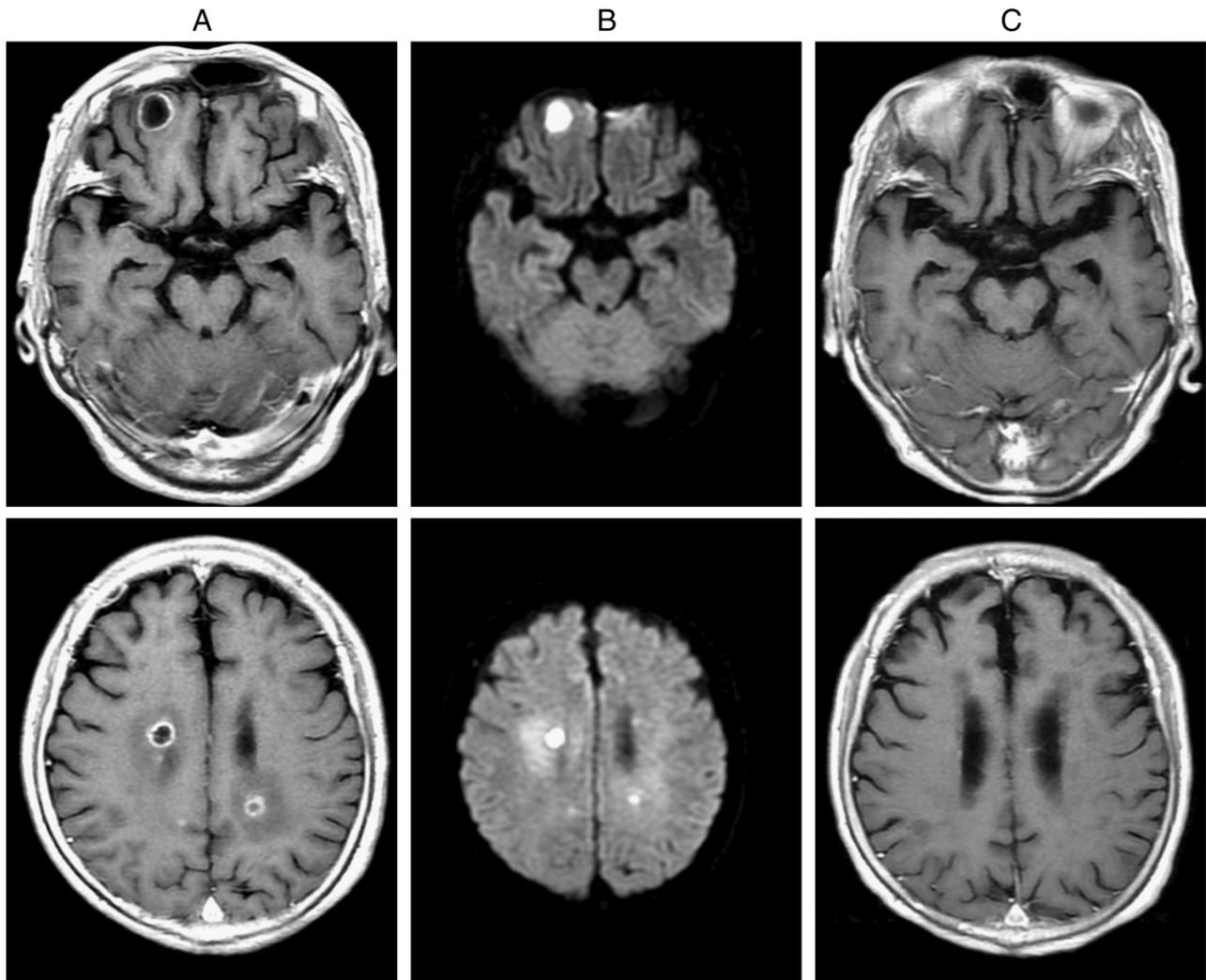


Fig. 2. Gd-DTPA-enhanced MRI of the brain revealed multiple ring-enhanced masses with surrounding edema (A), and diffusion-weighted MRI (DWI) revealed that these were high-intensity lesions (B). These lesions had nearly disappeared after 6 months of antibiotic treatment (C).

Brain abscesses are initiated by microbial invasion of the brain. Pyogenic bacteria evoke inflammation and produce pus-forming masses. The responsible microorganisms include staphylococcus, streptococcus, and gram-negative bacilli [2]. Although detection of the responsible microorganism is generally essential, we were unable to detect any responsible bacterium from cultivations of sputum, blood, pleural fluid, or bronchial lavage fluid, possibly because the patient was administered a course of antibiotics before she presented to our hospital. Drainage from the brain abscesses was the only means to identify responsible bacteria, but we abandoned this option because of the risk of spreading the inflammation into the brain. We decided to start the treatment of brain abscesses because patients with brain abscess generally have a poor prognosis with high mortality rate [1]. Although *Nocardia* is not commonly responsible for brain abscesses, we considered it as a responsible bacterium because it was likely to affect both the lungs and the

brain. *Nocardia* infection generally occurs by inhalation of bacteria or cutaneous invasion, and is likely to affect the lungs, brain, and skin [3]. Treatments for nocardiosis include surgical drainage and antimicrobial agents. ST is considered the first therapy of choice, and combinations of ST with aminoglycoside, CTRX, minocycline, or carbapenem are recommended to be delivered during the acute stage to avoid drug resistance [3,4]. Long-term medication is recommended for 6 to 12 months for nocardial brain abscesses, and patients should be followed up with attention to reactivation. In our case, we were able to identify neither the responsible bacterium nor drug susceptibility, although the patient was successfully treated with the combination of ST and CTRX.

T_1 -weighted Gd-DTPA-enhanced MRI usually shows ring-enhanced lesions in cases of brain abscess and may also be demonstrated in metastatic brain tumors or glioblastomas [5]. Differentiation between metastatic tumors and abscesses is sometimes difficult as in the

present case. Recently, DWI of the brain was reported to be useful in the differentiation. It is described that brain tumors have a low-intensity area at the core of the mass; by contrast, brain abscesses tend to be categorized as high intensity [6–8]. These differences are likely caused by differences in content: pus in the cavity of a brain abscess consists of inflammatory cells, bacteria, necrotic tissue, and highly viscous proteinaceous exudates; in contrast, metastatic tumors usually consist of necrotic tissue debris, fewer inflammatory cells, and clearer serous fluid than pus. Highly viscous fluid in the abscesses results in high-intensity areas on DWI. In the present case, DWI revealed multiple lesions as high-intensity spots, indicating that they are likely brain abscesses.

In conclusion, brain abscess is a condition with poor prognosis that requires treatment as soon as possible, so physicians should recognize the possibility when they observe multiple brain masses. DWI is a useful tool in differentiating brain abscesses from metastatic brain tumors.

References

- [1] Mamelak AN, Obana WG, Flaherty JF, Rosenblum ML. Nocardial brain abscess: treatment strategies and factors influencing outcome. *Neurosurgery* 1994;35:622–31.
- [2] Tonon E, Scotton PG, Gallucci M, Vaglia A. Brain abscess: clinical aspects of 100 patients. *Int J Infect Dis* 2006;10:103–9.
- [3] Lerner PI. Nocardiosis. *Clin Infect Dis* 1996;22:891–903 [quiz 904–5].
- [4] Weber L, Yium J, Hawkins S. Intracranial Nocardia dissemination during minocycline therapy. *Transpl Infect Dis* 2002;4:108–12.
- [5] Lai PH, Hsu SS, Lo YK, Ding SW. Role of diffusion-weighted imaging and proton MR spectroscopy in distinguishing between pyogenic brain abscess and necrotic brain tumor. *Acta Neurol Taiwan* 2004;13:107–13.
- [6] Nakaiso M, Uno M, Harada M, Kageji T, Takimoto O, Nagahiro S. Brain abscess and glioblastoma identified by combined proton magnetic resonance spectroscopy and diffusion-weighted magnetic resonance imaging—two case reports. *Neurol Med Chir (Tokyo)* 2002;42:346–8.
- [7] Castillo M. Imaging brain abscesses with diffusion-weighted and other sequences. *AJNR Am J Neuroradiol* 1999;20:1193–4.
- [8] Kim YJ, Chang KH, Song IC, Kim HD, Seong SO, Kim YH, et al. Brain abscess and necrotic or cystic brain tumor: discrimination with signal intensity on diffusion-weighted MR imaging. *AJR Am J Roentgenol* 1998;171:1487–90.