


This article was downloaded by: [University of Connecticut]

On: 13 October 2014, At: 21:11

Publisher: Routledge

Informa Ltd Registered in England and Wales Registered Number: 1072954 Registered office: Mortimer House, 37-41 Mortimer Street, London W1T 3JH, UK



The Clinical Neuropsychologist

Publication details, including instructions for authors and subscription information:

<http://www.tandfonline.com/loi/ntcn20>

Longitudinal neuropsychological findings in amyloid beta-related angiitis (A β RA): A case report

Antonina Omisade^a, Heather Rigby^b, Alexander Easton^c,
Stephen J. Phillips^b & Sherri L. Carter^a

^a Psychology, QEII Health Sciences Centre, Halifax, NS, Canada

^b Division of Neurology, Dalhousie University, Halifax, NS, Canada

^c Department of Pathology, Dalhousie University, Halifax, NS, Canada

Published online: 17 Dec 2012.

To cite this article: Antonina Omisade, Heather Rigby, Alexander Easton, Stephen J. Phillips & Sherri L. Carter (2013) Longitudinal neuropsychological findings in amyloid beta-related angiitis (A β RA): A case report, *The Clinical Neuropsychologist*, 27:2, 300-312, DOI: [10.1080/13854046.2012.744851](https://doi.org/10.1080/13854046.2012.744851)

To link to this article: <http://dx.doi.org/10.1080/13854046.2012.744851>

PLEASE SCROLL DOWN FOR ARTICLE

Taylor & Francis makes every effort to ensure the accuracy of all the information (the "Content") contained in the publications on our platform. However, Taylor & Francis, our agents, and our licensors make no representations or warranties whatsoever as to the accuracy, completeness, or suitability for any purpose of the Content. Any opinions and views expressed in this publication are the opinions and views of the authors, and are not the views of or endorsed by Taylor & Francis. The accuracy of the Content should not be relied upon and should be independently verified with primary sources of information. Taylor and Francis shall not be liable for any losses, actions, claims, proceedings, demands, costs, expenses, damages, and other liabilities whatsoever or howsoever caused arising directly or indirectly in connection with, in relation to or arising out of the use of the Content.

This article may be used for research, teaching, and private study purposes. Any substantial or systematic reproduction, redistribution, reselling, loan, sub-licensing, systematic supply, or distribution in any form to anyone is expressly forbidden. Terms &

Conditions of access and use can be found at <http://www.tandfonline.com/page/terms-and-conditions>

CE Longitudinal neuropsychological findings in amyloid beta-related angiitis (A β RA): A case report

**Antonina Omisade¹, Heather Rigby², Alexander Easton³,
Stephen J. Phillips², and Sherri L. Carter¹**

¹Psychology, QEII Health Sciences Centre, Halifax, NS, Canada

²Division of Neurology, Dalhousie University, Halifax, NS, Canada

³Department of Pathology, Dalhousie University, Halifax, NS, Canada

Amyloid β -related angiitis (A β RA) is a clinicopathological diagnosis of primary central nervous system angiitis theoretically triggered by vascular deposition of amyloid β peptide. Deposits of A β are associated with degeneration of the vasculature, thereby increasing risks of a stroke and/or cognitive impairment. Despite this, no prior studies have presented a detailed neuropsychological profile associated with A β RA. We present longitudinal neuropsychological findings for the case of a 58-year-old man with biopsy-diagnosed A β RA. Neuropsychological test results and clinical presentation demonstrated a mild to moderate dysexecutive syndrome implicating dorsolateral frontal and orbitofrontal-subcortical systems involvement. Despite prior reports of cognitive decline following a diagnosis of A β RA, cognitive functioning remained relatively stable over a 15-month period after immunosuppressive treatment. For the most part, objective measures did not demonstrate a measurable change in cognitive functioning, except for a mild decline in memory. There were subjective reports of improvement in cognitive and adaptive functioning from the patient and his spouse over this time period. The clinical significance of these results is discussed in the context of theories of executive dysfunction, and with reference to previously-published cases of A β RA.

Keywords: Vasculitis; Central nervous system; Neuropsychology; Dementia.

INTRODUCTION

Amyloid β -related angiitis (A β RA) is a clinicopathological diagnosis of primary CNS angiitis theoretically triggered by vascular deposition of amyloid β peptide (Scolding et al., 2005). A diagnosis of A β RA can only be made definitively by histological examination of brain tissue, showing vasculitis in cortical and leptomeningeal blood vessels whose walls contain amyloid β peptide. Although considered a distinct clinical-pathological entity, it may lie on a continuum of vasculitic disorders that includes primary central nervous system vasculitis (PCNSV), typically characterized by vascular inflammatory lesions, and cerebral amyloid angiopathy (CAA), characterized by A β deposits in the vasculature (Amick, Joseph, Silvestri, & Selim, 2008; Salvarani et al., 2008). In CAA deposits of A β are associated with degeneration of the vasculature, thereby increasing risks of a hemorrhagic stroke and/or cognitive impairment (Greenberg, 1998;

Address correspondence to: Dr. Sherri L. Carter, Psychology – QEII Health Sciences Centre, Nova Scotia Rehabilitation Centre, 1341 Summer Street, Halifax, Nova Scotia B3H 4K4, Canada. E-mail: sherri.carter@cdha.nshealth.ca

Accepted for publication: October 24, 2012. First published online: December 14, 2012.

Greenberg, Gurol, Rosand, & Smith, 2004; Greenberg, Vonsattel, Stakes, Gruber, & Finklestein, 1993). In A β RA, the clinical presentation varies and may include all or some of the features associated with PCNSV or CAA such as seizures, headache, focal neurological findings, cognitive features, personality changes, or other mental status changes (Amick et al., 2008; Fountain & Eberhard, 1996; Salvarani et al., 2008; Schwab, Lidov, Schwartz, & Anderson, 2003; Scolding et al., 2005).

Published descriptions of cognitive and behavioral symptoms in A β RA at initial presentation have been brief. Salvarani et al. (2008) reported a greater frequency of cognitive dysfunction in A β RA compared to PCNSV alone. “Dementia” and “cognitive decline” (without further elaboration of signs or symptoms) are among the most frequently reported changes (Amick et al., 2008; Scolding et al., 2005). With regard to specific deficits, confusion (Fountain & Eberhard, 1996; Salvarani et al., 2008; Scolding et al., 2005), “amnesia” or memory impairment (Fountain & Eberhard, 1996; Scolding et al., 2005), dysphasia (including “aphasia” and “fluent aphasia”) (Amick et al., 2008; Scolding et al., 2005; Fountain & Eberhard, 1996), visual disturbance (hemianopia) (Amick et al., 2008; Fountain & Eberhard, 1996; Salvarani et al., 2008; Scolding et al., 2005), and unilateral hemiparesis (Amick et al., 2008; Fountain & Eberhard, 1996; Scolding et al., 2005) are most frequently reported. In fewer cases attentional deficits, apraxia, ataxia, alexia, dysgraphia, and dysmetria have been noted at initial presentation or shortly thereafter (Fountain & Eberhard, 1996; Salvarani et al., 2008; Scolding et al., 2005). Two reported A β RA cases presented without any significant cognitive dysfunction as assessed by neurological exam and chart review (Scolding et al., 2005; Wong, Robbins, Knuckey, & Kermod, 2006). Behavioral and psychiatric symptoms have been observed in some cases. Scolding et al. (2005) reported three cases that presented with hallucinations, paranoia, and “behavioral disturbance,” while Salvarani et al. (2008) described a patient with “agitated behavior” at onset.

Consistent with variable presenting signs and symptoms, outcomes of A β RA also vary, but there are high rates of death and disability; dementia is often associated with disease progression (Amick et al., 2008; Fountain & Eberhard, 1996; Salvarani et al., 2008; Schwab et al., 2003; Scolding et al., 2005). Despite frequent cognitive involvement, no case reports have formally evaluated cognitive functioning via standardized neuropsychological testing.

We present the case of a 58-year-old man with biopsy-diagnosed A β RA who completed two neuropsychological assessments 15 months apart and showed little objective cognitive decline over this time period. Despite prior reports of dementia in this population, our patient’s clinical presentation was mainly characterized by a stable behavioral dysexecutive syndrome before and after steroidal treatment. The clinical and theoretical significance of the current findings is discussed with reference to prior reports of cognitive decline in A β RA and within the context of theories of executive functions. This case also highlights the heterogeneity of this clinical pathological entity with regard to initial presentation and outcomes, as well as important areas to target for patient/family education and behavioral intervention.

CLINICAL HISTORY

At the time of initial presentation, the patient was a 58-year-old, right-handed male who presented to hospital with a generalized tonic clonic (GTC) seizure. Neurologic examination was normal. MRI scan revealed prominent left fronto-temporal subcortical T2 signal change with the appearance of vasogenic edema. There was non-specific right temporal dysrhythmia on EEG. Cerebrospinal fluid analysis was unremarkable. Four weeks later, a scheduled brain biopsy was deferred on the basis of a pre-operative MRI that showed marked reduction in lesion size. The patient had a second GTC seizure 3 months following his initial presentation and a repeat MRI showed an interval increase in lesion size with new mild leptomeningeal enhancement. In the days that followed he developed an expressive language deficit, personality change, and recurrent seizures refractory to medical therapy.

A surgical biopsy was obtained from the left middle frontal gyrus 16 weeks after symptom onset. Biopsy consisted of three cortical fragments up to 1.3 cm in maximum dimension. Microscopic evaluation showed changes in cortical blood vessels. The pathological diagnosis of amyloid beta related angiitis (A β RA) was confirmed based on inflammatory damage to the wall of arterial vessels containing beta amyloid (Figure 1).

He was treated with prednisone and cyclophosphamide for 9 months after which he was switched to azathioprine alone. A repeat MRI scan at 2 years demonstrated complete resolution of the lesion (Figure 2). He remained neurologically stable at last follow-up 3 years after initial presentation.

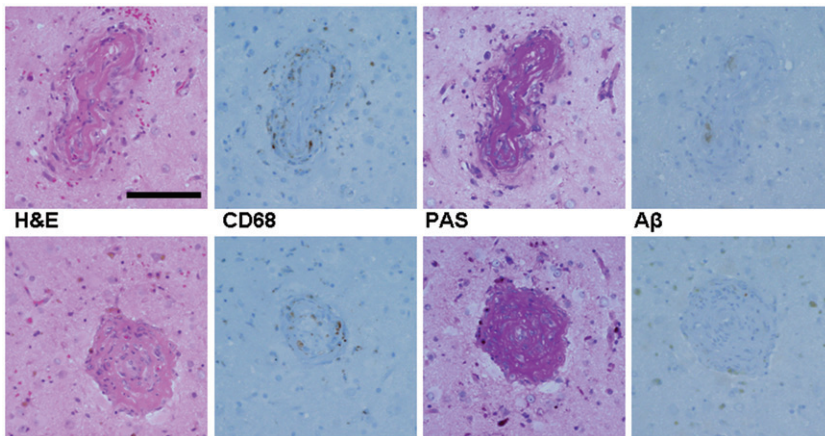


Figure 1. Histopathology results. Small arteries and arterioles were infiltrated by lymphocytes (CD3 positive) and macrophages (CD68 positive). Vessels showed damage in the form of vascular thickening and occlusion, hypertrophy of lining endothelial cells and infiltration by fibrinoid material. Several involved vessels were positive for beta-amyloid; 44/116 arterial vessels (38%) were involved. Upper panel was previously published in: Rigby, H., Easton, A., & Bhan, V. (2011). Amyloid β -related angiitis of the central nervous system: Report of 3 cases. *Canadian Journal of Neurological Sciences*, 38, 626–630. It is reproduced with the permission from the Canadian Journal of Neurological Sciences and from Dr. Heather Rigby.

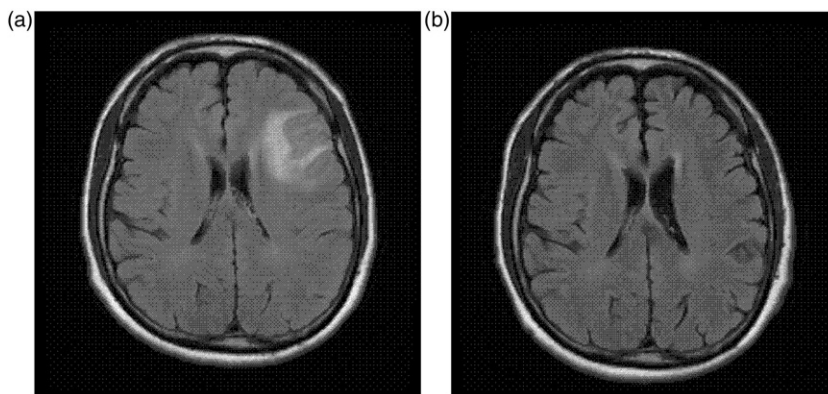


Figure 2. FLAIR MRI results at initial presentation (a) and at follow-up (b). The follow-up MRI was conducted approximately 2 months following the second neuropsychological assessment (NPA 2).

With respect to pre-morbid history, the patient reported 9 years of formal education with no history of a learning disorder or developmental disability. Prior to the onset of symptoms the patient was employed full-time in a cognitively demanding career in the field of public safety and security. He was independent in all activities of daily living, and at the time of both assessments he was living independently in his own home with his spouse. Medical history was significant for prolonged daily alcohol consumption until his diagnosis with A β RA, and a remote episode of right hand dystonia. There was no reported history of pre-morbid psychiatric disorder.

NEUROPSYCHOLOGICAL ASSESSMENTS

Informed consent was obtained according to the procedure approved by the institutional ethics board. Two neuropsychological assessments were completed to track disease trajectory and treatment effects. The first assessment was conducted 4 months following biopsy and the second one 15 months later. Both assessments included clinical interviews with the patient and his spouse, and the administration of a comprehensive battery of clinical neuropsychological tests and questionnaires regarding the patient's cognitive, emotional, and behavioral functioning.

Both evaluations included the Neuropsychological Assessment Battery (NAB) Screening Module (White & Stern, 2003), a brief screening battery of timed and untimed tests of attention, language, memory, visuospatial functions, and executive functions. Index scores for each domain were computed by converting raw test scores (time to complete and/or number of correct responses) into standard scores that were demographically-corrected for age and education. The following cognitive domains were sampled further using conventional neuropsychological measures: *processing speed* (Trail Making Test A; Reitan & Wolfson, 1993), *complex attention and working memory* (Wechsler Memory Scale-III Working Memory Index and Mental Control subtest; Wechsler, 1997a), *verbal fluency* (Controlled Oral Word Association, COWA; Benton, Hamsher, & Sivan, 1994, and Animal Fluency;

Spreen & Strauss, 1998), *visuospatial skills* (Wechsler Adult Intelligence Scale-III Block Design; Wechsler, 1997b), *verbal learning and memory* (California Verbal Learning Test-II, CVLT-II; Delis, Kramer, Kaplan, & Ober, 2000), and *executive functions* (NAB Executive Functions Module; White & Stern, 2003; Trail Making Test B; Reitan & Wolfson, 1993; Wisconsin Card Sorting Test; Heaton, Chelune, Talley, Kay, & Curtiss, 1993).

The patient and his spouse also completed two self-report questionnaires: (i) Frontal Systems Behavior Scale (FrSBe) (Grace & Malloy, 2001), which includes scales assessing symptoms sensitive to frontal system pathology (i.e., apathy, disinhibition, and executive dysfunction), and (ii) Neurobehavioral Functioning Inventory (NFI) (Kreutzer, Seel, & Marwitz, 1999) that assesses six cognitive and behavioral areas (depression, somatic complaints, memory/attention, communication, aggression, and motor problems) often affected in neurological disorders.

To minimize potential practice effects alternate forms of the NAB screening module, the COWA, and the CVLT-II were used during the second assessment. No alternate forms were available for the remainder of the tests. The Standard Deviation Index method (as described in Duff, 2012) was used to define meaningful change from NPA1 to NPA2 on neuropsychological tests and self-report questionnaires. A change in standard scores of 1.64 standard deviations in either direction was considered to represent clinically significant improvement or decline.

RESULTS

Neuropsychological assessment 1 (NPA1)

Interview. The patient and spouse both described changes in the patient's cognitive and adaptive functioning but their opinions differed on the degree and impact of these changes. The patient reported minor declines in memory and language. For instance, he described his memory as "short" (i.e., requiring more notes and reminders than usual) and noted that he "stutters" in conversation. He was frustrated by these changes, but he minimized their importance and he denied problems completing daily activities.

His spouse, however, described significant cognitive declines in the patient's organizational abilities, memory, visuospatial skills (e.g., becoming lost in familiar places), and language (e.g., word retrieval problems). She reported that these changes substantially interfered with the patient's ability to carry out daily tasks, such as bill payment, and they posed safety concerns. As such, the patient was rarely left unattended, particularly in situations involving elements of danger (e.g., fire and electrical safety).

In addition to cognitive declines, striking changes in personality and behavior were described by the patient's wife, including decreased initiation, perseveration, and difficulty with interpersonal interactions. In particular the patient became overly familiar in social situations, and he frequently used profane language or made inappropriate comments; he also began "overpersonalizing" interactions with others. Subtle behavioral changes in the form of "angry outbursts" reportedly began about 3 years prior to the onset of neurological symptoms.

Behavior. The patient was generally cooperative, but impatient and suspicious about the assessment. Speech was hesitant, with mild word retrieval problems. Speech content was mildly vague and tangential, with repetition and fixation on some ideas; he often lost track of his responses. Mood fluctuated from neutral to jocular, irritable, and confrontational. During testing he became argumentative during timed tasks, which he disliked. He appeared impatient to complete the testing and he required multiple reminders that his participation was voluntary. Despite this, he was receptive to redirection, such that the tests were completed in a valid manner. Mild behavioral disinhibition was evident, such as over-familiarity, occasional profanity, and sexual references. Because standardized rules of testing were maintained despite the patient's behavior, and because his presentation on testing appeared to accurately reflect his functioning in daily life, the results of neuropsychological testing were considered a valid representation of the patient's neurocognitive functioning.

Test results. Neuropsychological assessment results from two occasions: NPA1 and NPA2 (15 months later) are presented in Table 1. Compared to neurologically normal peers, performance was below expected (mildly impaired) in several areas, including speed of information processing and complex attention, visuospatial skills, and verbal fluency (particularly animal fluency). Although variable, memory scores generally measured within the average range. However, memory test performance suggested difficulty self-monitoring responses, which was evident in a higher than normal number of perseverative responses on the CVLT-II.

The behavioral presentation was more striking than objective test results, characterized by interpersonally disinhibited behavior, emotional dysregulation, difficulty with self-monitoring, perseveration, and reduced awareness of these changes. On questionnaires, the FrSBe scale of disinhibition was "clinically elevated" from "normal," which represented a change from baseline functioning according to the patient. Specifically, the patient's responses on the self-rating form reflected more impulsive and immature behavior (e.g., more frequent swearing). On the family rating form, the disinhibition scale was not significantly elevated and did not reflect a significant change from baseline. However, a detailed review of the spouse's responses identified impulsivity as a particular concern that was not present prior to onset of the patient's illness, as well as an increased tendency for him to interrupt others in conversation. The FrSBe scale of executive dysfunction was also clinically elevated, but only on the family rating form. The spouse identified problems such as disorganization, difficulty sequencing and multi-tasking, behavioral rigidity, poor judgment, and reduced awareness which were not present prior to onset of illness. NFI ratings were average compared to the normative group at both time points. Taken together with his new learning and memory profile, these results were interpreted as consistent with a mild to moderate dysexecutive syndrome (e.g., Bonelli & Cummings, 2007; Lezak, Howison, & Loring, 2004).

Neuropsychological assessment 2 (NPA2)

Interview. In contrast to the initial assessment, the couple agreed that cognitive and adaptive functioning had improved significantly. They reported

Table 1. Time 1 (NPA1) and Time 2 (NPA2) neuropsychological assessment results

COGNITIVE DOMAIN	NPA 1		NPA 2	
	Raw score	Percentile	Raw score	Percentile
Test				
<i>Sub-scores</i>				
SPEED/ATTENTION				
TmT A Speed (Errors)	51'' (1)	14	44'' (1)	32
NAB Screen: Attention Index	87	19	81	10
Digit Span				
<i>Digits Forward</i>	7	31	7	42
<i>Digits Backward</i>	3	38	4	62
Orientation	29	50	29	50
Numbers and Letters part A				
Speed (Errors)	48'' (0)	18	60'' (0)	4
Numbers and Letters part B				
Efficiency	28	21	15	2
WORKING MEMORY				
Mental Control	24	50	30	75
WMS-III WMI	17	27	20	47
MEMORY				
CVLT-II				
<i>Trial 1</i>	7	50	4	7
<i>Trial 5</i>	14	84	11	70
<i>Trial 1-5 Total</i>	51	75	39	45
<i>List B</i>	7	84	3	7
<i>SDFR</i>	11	70	9	50
<i>SDCR</i>	13	84	10	32
<i>LDFR</i>	12	84	10	50
<i>LDCR</i>	14	84	10	50
<i>Slope: Trial 1-5</i>	1.6	70	1.5	70
<i>Repetitions</i>	18	1	8	7
<i>Intrusions</i>	4	50	9	7
<i>Recognition Discrim.</i>	3.2	84	2	32
NAB Screen: Memory Index	100	50	104	61
Shape Learning				
<i>Immediate Recognition</i>	2	46	2	58
<i>Delayed Recognition</i>	1	21	2	62
<i>Percent Retention</i>	50	21	100	75
Story Learning				
<i>Immediate Recall</i>	16	62	20	84
<i>Delayed Recall</i>	15	73	8	27
<i>Percent Retention</i>	94	50	40	5
LANGUAGE				
COWA	30	22	32	25-75
Animal Fluency	13	6	14	21
NAB Screen: Language Index	108	70	100	50
Auditory Comprehension	56	69	56	66
Naming	9	69	9	58

(continued)

Table 1. Continued.

COGNITIVE DOMAIN	NPA 1		NPA 2	
	Raw score	Percentile	Raw score	Percentile
Test				
<i>Sub-scores</i>				
VISUOSPATIAL FUNCTIONS				
Block Design	22	21	Not administered	
NAB Screen: Spatial Index	82	12	83	13
Visual Discrimination	3	10	4	31
Design Construction	4	27	1	10
EXECUTIVE FUNCTIONS				
TmT B Speed (Errors)	104" (2)	37	117" (0)	32
WCST				
Categories	Not administered		1	6–10
PE			34	16
NPE			37	2
FMS			0	>16
%CLR			27	6
NAB Executive Module Index	103	58	97	42
Mazes	16	76	8	42
Judgment	12	21	12	21
Category test	10	54	13	73
Word Generation	11	76	7	50

NAB = Neuropsychological Assessment Battery; WMS-III = Wechsler Memory Scale-III, WMI = Working Memory Index; CVLT-II = California Verbal Learning Test-II, SDFR and SDCR = Short Delay Free and Cued Recall, respectively, LDFR and LDCR = Long Delay Free and Cued Recall, respectively; COWA = Controlled Oral Word Association; WAIS-III = Wechsler Adult Intelligence Scale-III; TmT = Trail Making Test; WCST = Wisconsin Card Sorting Test; PE = Perseverative errors; NPE = Nonperseverative errors; FMS = Failures to Maintain Set; %CLR = Percentage of conceptual-level responses.

ongoing mild problems with: speed of processing new and complex information, multi-tasking, remembering names, retrieving words, and sense of direction in unfamiliar environments. There were no longer any safety concerns. Although still present, behavioral symptoms (e.g., social disinhibition, occasional irritability/anger), occurred less often and were reportedly more manageable.

Behavior. The patient was generally cooperative, but he again required reassurance and encouragement to complete the assessment. Spontaneous speech had improved, with better fluency and fewer word-finding and word-substitution errors. Speech content remained mildly tangential, circumlocutory, and thematically perseverative. Engagement in testing fluctuated across tasks. He regularly attempted to circumvent the rules of testing, he interrupted tasks, and he argued with the examiner. However, as on initial assessment, he was responsive to redirection such that standardized administration procedures could be maintained. Changeable mood and mild social disinhibition remained prominent.

Test results. The neuropsychological profile remained relatively stable since the assessment 15 months prior. There was a variable pattern of decline and

improvement across individual tasks, but these changes were attributed to fluctuating task engagement rather than cognitive decline. For example, speed of response was slightly faster on one psychomotor sequencing task, but slower on other tasks. The only change interpreted as significant was a mild decline in the immediate recall of new verbal information, particularly notable on List B recall of the CVLT-II (see Table 1). Despite this decline, most memory test scores remained within average limits for his age. A mild to moderate dysexecutive syndrome persisted on behavioral presentation and objective tests of mental flexibility and problem solving.

Questionnaires showed subjective improvement from both the point of view of the patient and his spouse, consistent with their report in interview. At NPA2, only self-reported disinhibition remained elevated on the FrSBe, with age-inappropriate/childish behavior and swearing representing ongoing areas of difficulty. Spousal ratings on all of the FrSBe scales were below clinical cut-offs on this occasion, comparable to her ratings of the patient's baseline functioning. NFI ratings remained average and unchanged from NPA 1.

DISCUSSION

In summary, the results of the first assessment were interpreted to reflect a mild to moderate dysexecutive syndrome with both cognitive and behavioral features including: weaknesses on tasks of mental flexibility and self-monitoring, as well as social disinhibition, perseveration, and emotional dysregulation observed over the course of the evaluation. In addition mild weaknesses in information processing speed and complex attention, visuospatial skills, and semantic (animal) fluency were present. On re-assessment the results were generally stable. Objective measures did not demonstrate a clinically significant change, except for a decline in the immediate recall of new verbal information, primarily notable on CVLT-II List B recall. Despite this, memory test scores largely remained within normal limits. Subjectively, the patient and his spouse reported improvements in the patient's cognitive and adaptive functioning over time.

These results were somewhat unexpected given prior reports of dementia and eventual cognitive decline associated with A β RA (Amick et al., 2008; Fountain & Eberhard, 1996; Salvarani et al., 2008; Schwab et al., 2003; Scolding et al., 2005) and they were contrary to the prognosis anticipated at initial presentation. At the same time neurological improvement and subsequent stability, although less frequently reported, have been observed in some cases following steroidal treatment (Rigby, Easton, & Bhan, 2011; Sakaguchi et al., 2011). In fact, when our patient's relatively stable neuropsychological test results are considered against the reduction in lesion size on MRI and his neurological recovery, a lack of corresponding *improvement* in objectively measured cognitive functions is perhaps equally surprising.

The most prominent and stable dysexecutive behavioral and cognitive features in this case are commonly associated with dysfunction within the orbitofrontal and dorsolateral frontal-subcortical circuits (Bonelli & Cummings, 2007; Mesulam, 2000). Weaknesses in the described cognitive domains may stem directly from damage to the frontal regions (e.g., attention and working memory) or to disruption in functional connectivity between frontal and posterior (temporal and parietal)

areas involved in new learning and visuospatial processing (Bonelli & Cummings, 2007, 2008). The patient's presentation and neuropsychological test performance at both assessment time points were consistent with the MRI findings of increased T2 signal in the frontotemporal subcortical region. Mild declines in memory represented the only significant change within the profile from the first assessment.

Stability of cognitive dysfunction over time despite a reduction in lesion size may be explained by theories of executive functions, such as that proposed by Stuss and Alexander (2007). Their model challenges the traditional view of executive or "supervisory control" as a unitary functional property of the frontal lobes. Stuss and Alexander (2007) proposed discrete control sub-processes (i.e., energization, monitoring, and task-setting) that are subserved by neuroanatomically independent frontal networks, but are functionally interactive. According to this model, symptoms such as disinhibition and perseveration do not exist as unitary processes with individually identifiable neuroanatomical underpinnings, but they are caused by some combination of dysfunction in at least one of the three sub-processes. Thus a reduction in frontal lesion size, as observed in this case, would not necessarily correlate with significant behavioral or cognitive improvement as long as one or more key regions remain affected. Furthermore, conventional neuroimaging methods (e.g., MRI) do not provide information about neuroanatomical functioning or about the full scope of metabolic or neurochemical changes associated with neuroinflammation in vasculitis. Bonelli and Cummings (2007) point out that changes in levels of dopamine and norepinephrine may be particularly significant in regulating the functioning of frontal-subcortical circuits, and both contribute to selective impairment or recovery of various "frontal" functions. If available, functional imaging techniques, such as fMRI or PET, might have demonstrated more significant or widespread changes in the frontal subcortical networks that would better correlate with neuropsychological findings. Functional methods might also reveal much broader CNS involvement, extending beyond the frontal systems, due to the possible widespread effects of angiitis. In addition, clinical tests (e.g., WCST, TMT) may identify frontal systems dysfunction, but they are not able to pinpoint deficits within individual executive sub-processes (Zald & Andreotti, 2010). Thus the presented neuropsychological assessment results may not reflect subtle changes in executive functions which might have been detected using more sensitive or specific tools other than those currently available for clinical use.

Mild declines in verbal memory in the presence of an otherwise-stable profile are of uncertain clinical significance in this case. Although this finding may be a harbinger of future cognitive decline, such a conclusion is not warranted on the basis of the current results alone. Despite the observed change, most memory test scores remained within the average range. In addition this change was not accompanied by any functional declines. In fact both the patient and his spouse reported improvements in his daily functioning. Subjective perception of improvement could have been influenced by the patient's positive response to medical treatment and adjustment to illness rather than an objective change in his cognitive and behavioral functioning. However, an additional re-assessment would be helpful in further clarifying the cognitive trajectory.

This case provides important information about the course of cognitive dysfunction in treated A β RA. However, given the paucity of detail regarding

cognitive functioning in published cases of A β RA, it is unclear whether our patient's profile can be considered representative or characteristic of neuropsychological difficulties associated with this condition. Although A β RA is considered a separate clinical-pathological entity, it probably lies on a continuum of vasculitic disorder that includes PCNSV and CAA; theoretically, its clinical manifestations may vary greatly on an individual basis and reflect different syndromes (including dementia) associated with vasculitis and angiitis (Amick et al., 2008; Fountain & Eberhard, 1996; Scolding et al., 2005). Although A β deposits are highly prevalent in patients with dementia, which is common in CAA, they are also found in approximately 30% of the healthy elderly (Haglund, Kalaria, Slade, & Englund, 2006; Scolding et al., 2005). Salvarani et al. (2008) further argue that despite the high concordance of A β deposits and cognitive impairment, A β in A β RA patients is much less critical to clinical manifestations and progression of the disease than inflammation associated with the underlying vasculitis. Good response to immunosuppressive treatment in A β RA, which is characteristic of PCNSV, further supports this point. Thus, while A β may be associated with cognitive impairment as seen in CAA (Scolding et al., 2005), it does not invariably lead to progressive dementia, particularly if the inflammatory process is stopped or reversed with treatment. In our case, early behavioral changes were followed by a relatively stable course after immunosuppressive treatment, consistent with an underlying treatable disorder. Our patient's neuropsychological profile may also reflect the contribution of individual factors, including location and size of the initial lesion, combined with a good response to immunosuppressive treatment.

Furthermore, it is important to point out that our selection of SDI as a method of determining clinically significant change, rather than "reliable change" (RC) or regression-based (SRB) methods, imposes some inherent limitations on our conclusions of neuropsychological stability over time. SDI is statistically inferior to RCI and SRB, which account for some of the non-clinical factors associated with variability between baseline and re-test scores (e.g., test reliability, susceptibility to practice effects, etc) (Duff, 2012). However, our reason for selecting this method of determining change in favor of the RCI and SRB scores was two-fold. First, SDI is popular in clinical practice due to ease of calculation. Second, a thorough search of the literature did not yield RCI and SRB indices for all of our tasks that would adequately fit our case profile, including the interval between assessment points. Although the "one size fits all" approach of the SDI method is often considered a limitation, this characteristic allowed us to uniformly apply it to all of our tasks for a standard method of comparison. A consistent method of comparison across cognitive tasks was considered of paramount importance in this case due to the lack of published neuropsychological data in this rare disorder. As per Duff (2012), selection of an appropriate index to represent reliable change is a complex decision, which is based on numerous statistical and individual case-related factors.

When examined within the context of previously-published cases of A β RA, our case is consistent with some prior reports that patients with this condition may represent a highly clinically heterogeneous group (Salvarani et al., 2008). Prognosis regarding long-term cognitive and adaptive functioning may depend on unique characteristics of each case, including early response to treatment, cognitive performance at index cognitive assessment, and the presence of other vascular risk

factors. However, these hypotheses cannot be evaluated further without more detailed cognitive assessment data collected on a larger number of biopsy-confirmed cases of A β RA. Our findings of stable cognitive dysfunction may also merit a more balanced approach to educating patient and family members about the nature and prognosis of cognitive dysfunction in A β RA. In the case of a relatively stable course, intervention approaches used in cognitive rehabilitation paradigms with other populations (e.g. acquired brain injury) may also be useful to address A β RA-associated cognitive sequelae such as executive dysfunction.

ACKNOWLEDGMENT

The authors express their sincerest gratitude to this patient and spouse for sharing their experiences in the interests of improving future clinical care and science.

REFERENCES

- Amick, A., Joseph, J., Silvestri, N., & Selim, M. (2008). Amyloid- β -related angiitis: A rare cause of recurrent transient neurological symptoms. *Nature Clinical Practice Neurology*, 4, 279–283.
- Benton, A., Hamsher, K., & Sivan, A. (1994). *Multilingual Aphasia Examination manual of instructions* (3rd ed.). Iowa City, IA: AJA Associates.
- Bonelli, R. M., & Cummings, J. L. (2007). Frontal-subcortical circuitry and behavior. *Dialogues in Clinical Neurosciences*, 9, 141–151.
- Bonelli, R. M., & Cummings, J. L. (2008). Frontal-subcortical dementias. *The Neurologist*, 14, 100–107.
- Delis, D., Kramer, J., Kaplan, E., & Ober, B. A. (2000). *California Verbal Learning Test, second edition: Adult version*. San Antonio, TX: The Psychological Corporation.
- Duff, K. (2012). Evidence-based indicators of neuropsychological change in the individual patient: Relevant concepts and methods. *Archives of Clinical Neuropsychology*, 27, 248–261.
- Fountain, N. B., & Eberhard, D. A. (1996). Primary angiitis of the central nervous system associated with cerebral amyloid angiopathy: Report of two cases and review of the literature. *Neurology*, 46, 190–197.
- Grace, J., & Malloy, P. (2001). *Frontal Systems Behavior Scale*. Lutz, FL: Psychological Assessment Resources.
- Greenberg, S. M. (1998). Cerebral amyloid angiopathy: Prospects for clinical diagnosis and treatment. *Neurology*, 51, 690–694.
- Greenberg, S. M., Gurol, M. E., Rosand, J., & Smith, E. E. (2004). Amyloid-angiopathy-related vascular cognitive impairment. *Stroke*, 35, 2616–2619.
- Greenberg, S. M., Vonsattel, J. P., Stakes, J. W., Gruber, M., & Finklestein, S. P. (1993). The clinical spectrum of cerebral amyloid angiopathy: Presentations without lobar hemorrhage. *Neurology*, 43, 2073–2079.
- Haglund, M., Kalaria, R., Slade, J. Y., & Englund, E. (2006). Differential deposition of amyloid beta peptides in cerebral amyloid angiopathy associated with Alzheimer's disease and vascular dementia. *Acta Neuropathologica*, 111, 430–435.
- Heaton, R., Chelune, G., Talley, J., Kay, G. G., & Curtiss, G. (1993). *Wisconsin Card Sorting Test manual: Revised and expanded*. Odessa, FL: Psychological Assessment Resources.

- Kreutzer, J., Seel, R., & Marwitz, J. H. (1999). *Neurobehavioral Functioning Inventory*. San Antonio, TX: The Psychological Corporation.
- Lezak, M., Howison, D. B., & Loring, D. W. (2004). *Neuropsychological Assessment* (4th ed.). New York: Oxford University Press.
- Mesulam, M-M. (2000). *Principles of behavioral and cognitive neurology* (2nd ed.). New York: Oxford University Press.
- Reitan, R., & Wolfson, D. (1993). *The Halstead-Reitan Neuropsychological Test Battery*. Tucson, AZ: Neuropsychology Press.
- Rigby, H., Easton, A., & Bhan, V. (2011). Amyloid β -related angiitis of the central nervous system: Report of 3 cases. *Canadian Journal of Neurological Sciences*, *38*, 626–630.
- Sakaguchi, H., Ueda, A., Kosaka, T., Yamashita, S., Kimura, E., Yamashita, T., . . . Uchino, M. (2011). Cerebral amyloid angiopathy-related inflammation presenting with steroid-responsive higher brain dysfunction: Case report and review of the literature. *Journal of Neuroinflammation*, *14*, 116.
- Salvarani, C., Brown, R. D., Calamia, K. T., Christianson, T. J., Weigand, S. D., Miller, D. V., . . . Hunder, G. G. (2008). Primary central nervous system vasculitis: Comparison of patients with and without cerebral amyloid angiopathy. *Rheumatology*, *47*, 1671–1677.
- Schwab, P., Lidov, H. G. W., Schwartz, R. B., & Anderson, R. (2003). Cerebral amyloid angiopathy associated with primary angiitis of the central nervous system: Report of two cases and review of the literature. *Arthritis Rheumatism*, *49*, 421–427.
- Scolding, N. J., Joseph, F., Kirby, P. A., Mazanti, I., Gray, F., Mikol, J., . . . Love, S. (2005). A β -related angiitis: Primary angiitis of the central nervous system associated with cerebral amyloid angiopathy. *Brain*, *128*, 500–515.
- Spreen, O., & Strauss, E. (1998). *A Compendium of Neuropsychological Tests: Administration norms and commentary* (2nd ed.). New York: Oxford University Press.
- Stuss, D. T., & Alexander, M. P. (2007). Is there a dysexecutive syndrome? *Philosophical Transactions of the Royal Society B: Biological Sciences*, *362*, 901–915.
- Wechsler, D. (1997a). *Wechsler Memory Scale, third edition*. San Antonio, TX: The Psychological Corporation.
- Wechsler, D. (1997b). *Wechsler Adult Intelligence Scale, third edition*. San Antonio, TX: The Psychological Corporation.
- White, T., & Stern, R. (2003). *Neuropsychological assessment battery*. Lutz, FL: Psychological Assessment Resources.
- Wong, S. H., Robbins, P. D., Knuckey, N. W., & Kermod, A. G. (2006). Cerebral amyloid angiopathy presenting with vasculitic pathology. *Journal of Clinical Neuroscience*, *13*, 291–294.
- Zald, D. H., & Andreotti, C. (2010). Neuropsychological assessment of the orbital and ventromedial prefrontal cortex. *Neuropsychologia*, *48*, 3377–3391.